اللهم أنر قبر منْ حنّ لهُ القلب
اللهم هب له سعة في قبره لا يرا لها نهاية
هب لمضجعه طيبا وَ لظلمته نورا
ولذنوبه غفراناً وَ برّد قبره
وزده احساناً فوق احسانه
واجعل الجنة مسكنه

A 62-year-old patient presents complaining of shortness of breath which has increased over the past 2–3 months. He smokes 10 cigarettes per day. Examination reveals a BP of 132/82, with pulse 74 (AF). He has hyper-expanded lung fields and bilateral poor air entry. There is quiet wheeze and bilateral pitting oedema of the ankles. BMI is 26.

His blood gas measurements:

$p(CO_2)$	7.2 kPa
$p(O_2)$	9.1 kPa
pH	7.33
HCO_3	29 mmol/l

Lung function results show:

RV	120%
TLC	110%
KCO	70% (as a percentage of the expected values)

Which of the following diseases fits best with the above presentation?

A	Emphysema
B	Asthma
C	Obesity hypoventilation syndrome
D	Interstitial lung disease
E	Lymphangiomyomatosis

2318

Submit

Previous Question | Skip Question

Calculator

Normal Values

© Pastest 2017

A 62-year-old patient presents complaining of shortness of breath which has increased over the past 2–3 months. He smokes 10 cigarettes per day. Examination reveals a BP of 132/82, with pulse 74 (AF). He has hyper-expanded lung fields and bilateral poor air entry. There is quiet wheeze and bilateral pitting oedema of the ankles. BMI is 26.

His blood gas measurements:

$p(CO_2)$	7.2 kPa
$p(O_2)$	9.1 kPa
pH	7.33
HCO_3	29 mmol/l

Lung function results show:

RV	120%
TLC	110%
KCO	70% (as a percentage of the expected values)

Which of the following diseases fits best with the above presentation?

A	Emphysema
B	Asthma
C	Obesity hypoventilation syndrome
D	Interstitial lung disease
E	Lymphangiomyomatosis

Explanation

A	Emphysema

Emphysema gives a chronic CO_2-retaining picture, with an increased residual volume (RV), slightly high total lung capacity (TLC) and high RV/TLC percentage indicative of obstructive lung pathology. It's consistent with the compensated respiratory acidosis and evidence of right heart failure.

B	Asthma

Although acute asthma is associated with increased residual volume, this is not really a feature of chronic controlled asthma, nor is hypercapnia.

C	Obesity hypoventilation syndrome

Obesity hypoventilation is associated with reduced TLC, and would only be associated with hypercapnia in severe disease complicated by pulmonary hypertension and right heart failure.

D	Interstitial lung disease

Although interstitial lung disease is associated with hypoxia, hypercapnia is unexpected unless the patient has a superimposed acute respiratory tract infection.

E	Lymphangiomyomatosis

This usually presents in women of child-bearing age with shortness of breath and recurrent pneumothoraces.

2318

Rate this question:

Next Question

Previous Question | Tag Question

Feedback | End Session

Difficulty: Average

Peer Responses %

Session Progress

Responses Correct:	0
Responses Incorrect:	1
Responses Total:	1
Responses - % Correct:	0%

© Pastest 2017

A 40-year-old woman attends her GP complaining of a 9-month history of cough and shortness of breath. She has taken on looking after her father's aviary of rare birds around 1 year ago and smokes 10 cigarettes per day. Her GP has prescribed a salbutamol inhaler although apparently there has been little impact on her symptoms. Examination reveals occasional wheeze on auscultation. There are no signs of right heart failure.

Which of the following would be the biggest pointer to extrinsic allergic alveolitis in this patient?

A	Elevated inflammatory markers
B	Patchy upper zone shadowing on the CXR
C	Obstructive pattern on respiratory function testing
D	Symptomatic response to oral clarithromycin
E	Symptomatic response to oral corticosteroids

2320

Submit

Previous Question | Skip Question

Calculator

Normal Values

© Pastest 2017

A 40-year-old woman attends her GP complaining of a 9-month history of cough and shortness of breath. She has taken on looking after her father's aviary of rare birds around 1 year ago and smokes 10 cigarettes per day. Her GP has prescribed a salbutamol inhaler although apparently there has been little impact on her symptoms. Examination reveals occasional wheeze on auscultation. There are no signs of right heart failure.

Which of the following would be the biggest pointer to extrinsic allergic alveolitis in this patient?

A	Elevated inflammatory markers
B	Patchy upper zone shadowing on the CXR
C	Obstructive pattern on respiratory function testing
D	Symptomatic response to oral clarithromycin
E	Symptomatic response to oral corticosteroids

Explanation

B	Patchy upper zone shadowing on the CXR

In the subacute form, there may be micronodular or reticular opacities in the mid/upper lung fields, which over time may progress to fibrosis with loss of lung volume. Marked changes on CXR would be unexpected in a patient with simple asthma.

A	Elevated inflammatory markers

Although elevated inflammatory markers may be seen on CXR, they aren't definitive with respect to diagnosing extrinsic allergic alveolitis.

C	Obstructive pattern on respiratory function testing

Chronic extrinsic alveolitis may demonstrate evidence of obstructive lung disease, as may asthma.

D	Symptomatic response to oral clarithromycin

Antibiotic therapy has no impact on prognosis in bird fancier's lung – allergen avoidance and oral corticosteroids are the key.

E	Symptomatic response to oral corticosteroids

Both extrinsic allergic alveolitis and chronic poorly controlled asthma may show a response to corticosteroid therapy, and this is therefore a poor differentiator.

2320

Rate this question:

Next Question

Previous Question | Tag Question

Feedback | End Session

Difficulty: Average

Peer Responses %

Session Progress

Responses Correct:	0
Responses Incorrect:	2
Responses Total:	2
Responses - % Correct:	0%

© Pastest 2017

A patient with known bronchiectasis grows fully sensitive *Pseudomonas aeruginosa* in their sputum for the first time. This associated with a deterioration in his breathlessness.

Which of the following antibiotics would be most suitable as first-line treatment?

A	IV Ticarcillin plus IV Gentamicin
B	IV Ceftazidime
C	IV Gentamicin
D	Intravenous Colistin
E	Nebulised Colistin

2321

Submit

Previous Question | Skip Question

Calculator

Normal Values

© Pastest 2017

A patient with known bronchiectasis grows fully sensitive *Pseudomonas aeruginosa* in their sputum for the first time. This associated with a deterioration in his breathlessness.

Which of the following antibiotics would be most suitable as first-line treatment?

A	IV Ticarcillin plus IV Gentamicin
B	IV Ceftazidime
C	IV Gentamicin
D	Intravenous Colistin
E	Nebulised Colistin

Explanation

Standard treatment is with a third generation cephalosporin such as Ceftazidime, or Meropenem, or Aztreonam, used in combination with Gentamicin if required. Nebulised treatments such as aminoglycosides and Colistin can be used for prevention of a flare-up of a patient colonised with *Pseudomonas aeruginosa* and their use as prophylactic therapy has been shown to imporove lung funtion in patients with cystic fibrosis, but this not adequate as a treatment of acute infection. *Pseudomonas aeruginosa* is resistant to Amoxicillin.

2321

Rate this question:

Next Question

Previous Question | Tag Question

Feedback | End Session

Difficulty: Average

Peer Responses %

Session Progress

Responses Correct:	0
Responses Incorrect:	3
Responses Total:	3
Responses - % Correct:	0%

Tag Question

Your notes...

Cancel

Tag Question

© Pastest 2017

A high-resolution thoracic CT of a patient complaining of shortness of breath shows patchy ground-glass shadowing. However, there is much movement artefact.

What would be the best test to confirm restrictive lung disease due to a parenchymal disorder?

A	CT in expiration phase
B	FEV_1
C	Arterial blood gas
D	Chest X-ray
E	KCO

2322

Submit

Previous Question | Skip Question

Calculator

Normal Values

© Pastest 2017

A high-resolution thoracic CT of a patient complaining of shortness of breath shows patchy ground-glass shadowing. However, there is much movement artefact.

What would be the best test to confirm restrictive lung disease due to a parenchymal disorder?

A	CT in expiration phase
B	FEV_1
C	Arterial blood gas
D	Chest X-ray
E	KCO

Explanation

Restrictive lung diseases are characterised by reduced lung volume, either because of an alteration in lung parenchyma or because of a disease of the pleura, chest wall, or neuromuscular apparatus. The transfer coefficient will be reduced in patients with interstitial lung disease. With the presence of an abnormal CT, despite the fact that it is of poor quality, this would be enough evidence to suggest the diagnosis. Without the presence of a CT lesion, a normal KCO would merely rule out significant restrictive lung disease as a cause, with the abnormal CT seen here, abnormal KCO is useful supporting evidence for an underlying parenchymal disorder. The forced expiratory volume in 1 s is used for establishing obstructive lung disease. CXR and arterial blood gas estimation may be normal if restrictive lung disease is not severe. CT in expiration phase is useful for showing air-trapping in COPD.

2322

Rate this question:

Next Question

Previous Question | Tag Question

Feedback | End Session

Difficulty: Average

Peer Responses %

Session Progress

Responses Correct:	0
Responses Incorrect:	4
Responses Total:	4
Responses - % Correct:	0%

© Pastest 2017

A 24-year-old asthmatic on PRN salbutamol inhaler and budesonide 200 µg inhaler twice a day is not well controlled and needs his treatment stepping up.

Which of the following would be recommended according to current BTS guidelines?

A	Add in oral cromoglicate
B	Increase the budesonide to 800 µg BD
C	Add oral theophylline (modified release)
D	Add formoterol inhaler
E	Add tiotropium

2324

Submit

Previous Question Skip Question

Calculator

Normal Values

Blog About Pastest Contact Us Help

© Pastest 2017

A 24-year-old asthmatic on PRN salbutamol inhaler and budesonide 200 µg inhaler twice a day is not well controlled and needs his treatment stepping up.

Which of the following would be recommended according to current BTS guidelines?

A	Add in oral cromoglicate
B	Increase the budesonide to 800 µg BD
C	Add oral theophylline (modified release)
D	Add formoterol inhaler
E	Add tiotropium

Explanation

Cromoglicate is only effective for asthma prophylaxis by inhalation 3-4 times a day and is generally only considered after patients have failed to gain control on multiple agents including inhaled corticosteroids, long-acting beta agonist and monteleukast. The standard dose of budesonide is 100-400 µg, the high dose is 0.8-2mg. Before using a high dose steroid a long-acting beta agonist should be tried. Formoterol is a long-acting beta-2 agonist and should be added regularly in the next step up of the BTS guidelines. If there is no response this can be discontinued. Theophylline would be added in if asthma is not controlled after trying high dose inhaled steroids. Tiotropium is a long acting antimuscarinic licencsed for maintenance treatment for COPD and for the treatment of asthma in patients not controlled on inhaled corticosteroids and long-acting beta agonist.

2324

Rate this question:

Next Question

Previous Question | Tag Question

Feedback | End Session

Difficulty: Easy

Peer Responses %

Session Progress

Responses Correct:	0
Responses Incorrect:	5
Responses Total:	5
Responses - % Correct:	0%

© Pastest 2017

A patient complaining of chronic nocturnal cough and wheeze is investigated for asthma.

Which of the following tests, if positive would be most useful in differentiating a rare cause of his symptoms rather than a common one such as asthma?

A	Neutrophil count
B	HRCT
C	FEV_1 and FVC measurements
D	IgG
E	ANCA

2325

Submit

Previous Question | Skip Question

Calculator

Normal Values

© Pastest 2017

A patient complaining of chronic nocturnal cough and wheeze is investigated for asthma.

Which of the following tests, if positive would be most useful in differentiating a rare cause of his symptoms rather than a common one such as asthma?

A	Neutrophil count
B	HRCT
C	FEV_1 and FVC measurements
D	IgG
E	ANCA

Explanation

The presence of antineutrophil cytoplasmic antibody (ANCA) helps to rule in the Churg–Strauss syndrome (found in 70% of cases), which is similar to asthma and an important differential diagnosis since the treatment is different. The other stems wouldn't be as useful for differentiating between likely potential diagnoses. The eosinophil count and IgE level can be raised in both asthma and allergic bronchopulmonary aspergillosis (ABPA). Computed tomography (CT) in expiration phase shows air-trapping and can be seen especially in severe asthmatics. High-resolution computed tomography (HRCT) is only useful when looking for bronchiectasis in patients with ABPA. Although the forced expiratory volume in 1 s (FEV_1) and forced vital capacity (FVC) are non-specific in terms of diagnosis, they are useful in disease monitoring.

2325

Rate this question:

Next Question

Previous Question | Tag Question

Feedback | End Session

Difficulty: Average

Peer Responses %

Session Progress

Responses Correct:	0
Responses Incorrect:	6
Responses Total:	6
Responses - % Correct:	0%

© Pastest 2017

A 45 year old woman is referred by the GP to the respiratory care clinic with shortness of breath of unknown origin. Spirometry results: KCO 60%, FEV_1/FVC 90%.

Which of the following is most likely to be the underlying cause of these pulmonary function test results?

A	Sarcoidosis
B	Severe kyphoscoliosis
C	Muscular dystrophy
D	Pneumonectomy
E	Bronchiectasis

2327

Submit

Previous Question | Skip Question

Calculator

Normal Values

© Pastest 2017

A 45 year old woman is referred by the GP to the respiratory care clinic with shortness of breath of unknown origin. Spirometry results: KCO 60%, FEV_1/FVC 90%.

Which of the following is most likely to be the underlying cause of these pulmonary function test results?

A	Sarcoidosis
B	Severe kyphoscoliosis
C	Muscular dystrophy
D	Pneumonectomy
E	Bronchiectasis

Explanation

A	Sarcoidosis

A FEV_1/FVC of 90% indicates a restrictive cause. All the above diseases are evidenced by a restrictive pattern, except bronchiectasis which can result in an obstructive pattern. Only sarcoidosis would reduce the transfer coefficient as there is damage to the alveolar cells themselves. Other conditions where a reduction in KCO is reduced include those such is idiopathic pulmonary fibrosis, where there is also loss of alveolar function.

B	Severe kyphoscoliosis

Abnormalities of the thoracic cage lead to a reduction in available lung volume for gas exchange but don't impact on the transfer coefficient.

C	Muscular dystrophy

Similar to kyphoscoliosis, muscular dystrophy can lead to a restrictive lung pattern but doesn't impact on gas transfer.

D	Pneumonectomy

Pneumonectomy is most likely to have been performed for chronic bronchiectasis or lung cancer, both of which would be unusual in a 45-year-old woman and wouldn't be expected to impact on transfer factor in the remaining lung.

E	Bronchiectasis

Bronchiectasis produces an obstructive lung pattern on pulmonary function testing.

2327

Rate this question:

Next Question

Previous Question | Tag Question

Feedback | End Session

Difficulty: Easy

Peer Responses %

Session Progress

Responses Correct:	0
Responses Incorrect:	7
Responses Total:	7
Responses - % Correct:	0%

© Pastest 2017

A 45-year-old farmer comes to the Respiratory Clinic for review. He has been diagnosed by the GP as having asthma, for which he is treated with high-dose fluticasone/salmeterol and salbutamol ,without significant improvement in his symptoms. Examination reveals a BP of 122/72 mmHg, with pulse 70/min and regular. There is scattered wheeze and coarse crackles on auscultation of the chest. Respiratory function tests show an obstructive picture. A thoracic HRCT shows bilateral centrally dilatated thickened airways with 'signet rings'.

Which of the following tests would be most useful to confirm the suspected diagnosis?

A	IgE
B	IgG
C	ANCA
D	ANA
E	C3 and C4

2329

Submit

Previous Question | Skip Question

Calculator

Normal Values

© Pastest 2017

A 45-year-old farmer comes to the Respiratory Clinic for review. He has been diagnosed by the GP as having asthma, for which he is treated with high-dose fluticasone/salmeterol and salbutamol ,without significant improvement in his symptoms. Examination reveals a BP of 122/72 mmHg, with pulse 70/min and regular. There is scattered wheeze and coarse crackles on auscultation of the chest. Respiratory function tests show an obstructive picture. A thoracic HRCT shows bilateral centrally dilatated thickened airways with 'signet rings'.

Which of the following tests would be most useful to confirm the suspected diagnosis?

A	IgE
B	IgG
C	ANCA
D	ANA
E	C3 and C4

Explanation

A	IgE

The HRCT changes described are classical of proximal bronchiectasis. The diagnosis is therefore allergic bronchopulmonary aspergillosis (ABPA). The total IgE will be raised in ABPA, especially during a flare-up, and therefore represents the preferred investigation.

B	IgG

IgG can be low in bronchiectasis secondary to hypogammaglobulinaemia, although presentation for the first time at an earlier age would be expected because of recurrent respiratory tract infection.

C	ANCA

ANCA is most likely to be elevated in vasculitis. Eosinophilic vasculitis (Churg–Strauss) is associated with more features than just worsening of asthma, including skin lesions and mononeuritis, which aren't seen in this scenario.

D	ANA

ANA is raised in connective tissue disease such as SLE, although there are no other features to suggest connective tissue disease as the underlying diagnosis.

E	C3 and C4

Complement factors are consumed most when there is active tissue inflammation, such as with SLE. The absence of other features such as glomerulonephritis counts against C3 and C4 as being useful here.

2329

Rate this question:

Next Question

Previous Question | Tag Question

Feedback | End Session

Difficulty: Average

Peer Responses %

Session Progress

Responses Correct:	0
Responses Incorrect:	8
Responses Total:	8
Responses - % Correct:	0%

© Pastest 2017

A 16-year-old patient presents with bilateral crackles and clubbing. He also has problems with chronic diarrhoea and he has difficulty maintaining his weight.

Which of the following results is most closely related to the underlying diagnosis?

A	Corrected Ca 1.8 mmol/l
B	Eosinophils 2.0 × 10^6/l
C	A high number of macrophages on bronchoalveolar lavage
D	IgE 1200 µg/l
E	Inadequate pancreatic exocrine function

2331

Submit

Previous Question | Skip Question

Calculator

Normal Values

© Pastest 2017

A 16-year-old patient presents with bilateral crackles and clubbing. He also has problems with chronic diarrhoea and he has difficulty maintaining his weight.

Which of the following results is most closely related to the underlying diagnosis?

A	Corrected Ca 1.8 mmol/l
B	Eosinophils 2.0 × 10^6/l
C	A high number of macrophages on bronchoalveolar lavage
D	IgE 1200 μg/l
E	Inadequate pancreatic exocrine function

Explanation

The clinical signs could be the result of cystic fibrosis. Cystic fibrosis gene leads to defective chloride secretion and increased sodium absorption across the airway epithelium which can result in bronchiectasis and deficient pancreatic exocrine function. High IgE and eosinophil levels are significant for asthma or allergic bronchopulmonary aspergillosis (ABPA), which would, however, not cause the clubbing. A raised calcium level (above 2.1 mmol/L) could be due to sarcoidosis which could cause the above signs. A high number of macrophages are often seen in smokers' lungs and are therefore a non-specific test.

2331

Rate this question:

Next Question

Previous Question | Tag Question

Feedback | End Session

Difficulty: Average

Peer Responses %

Session Progress

Responses Correct:	0
Responses Incorrect:	9
Responses Total:	9
Responses - % Correct:	0%

© Pastest 2017

A known asthmatic is admitted to A&E with wheeze and shortness of breath, although she is not yet showing signs of fatigue. She is given continued nebulised salbutamol, IV steroids and high-flow oxygen. You are asked by the nursing sister in charge whether giving IV magnesium is appropriate.

According to the BTS guidelines, which of the following would count against the need for IV magnesium at this stage?

A	Patient is 18 years old
B	Magnesium is at the lower end of the normal range
C	Tachycardia with a heart rate of 120 beats/min
D	Patient is treated with oral theophylline
E	PEFR 240 vs 140 on admission (normal 500)

2332

Submit

Previous Question | Skip Question

Calculator

Normal Values

© Pastest 2017

A known asthmatic is admitted to A&E with wheeze and shortness of breath, although she is not yet showing signs of fatigue. She is given continued nebulised salbutamol, IV steroids and high-flow oxygen. You are asked by the nursing sister in charge whether giving IV magnesium is appropriate.

According to the BTS guidelines, which of the following would count against the need for IV magnesium at this stage?

A	Patient is 18 years old
B	Magnesium is at the lower end of the normal range
C	Tachycardia with a heart rate of 120 beats/min
D	Patient is treated with oral theophylline
E	PEFR 240 vs 140 on admission (normal 500)

Explanation

E	PEFR 240 vs 140 on admission (normal 500)

The British Thoracic Society (BTS) guidelines say that 50% magnesium sulphate at 1.2–2 g (4–8 mmol) over 20 min can be given IV to a patient with severe asthma not responding to inhaled bronchodilator or who has severe life-threatening asthma. In this case the PEFR is improving, without signs of fatigue, and it is therefore appropriate to continue with current management.

A	Patient is 18 years old

Age is irrelevant when considering the need for magnesium infusion, and there is little difference in response as age increases.

B	Magnesium is at the lower end of the normal range

Magnesium concentration is irrelevant as supra-therapeutic levels are given to achieve a pharmacological response with reduced acetylcholine release and improved smooth muscle relaxation

C	Tachycardia with a heart rate of 120 beats/min

Heart rate >110/min is an indicator of severe asthma and more likely to drive the use of magnesium.

D	Patient is treated with oral theophylline

The need for oral theophylline implies a poor response to beta-agonist therapy, and therefore a possible greater need for acute intervention with magnesium.

2332

Rate this question:

Next Question

Previous Question | Tag Question

Feedback | End Session

Difficulty: Average

Peer Responses %

Session Progress

Responses Correct:	0
Responses Incorrect:	10
Responses Total:	10
Responses - % Correct:	0%

© Pastest 2017

A 65-year-old man with known COPD comes to see you at the Respiratory Clinic. He has been a smoker for 40 years and previously worked in the docks at Southampton. He has experienced no increase in his sputum volume or any change in its colour. On examination, he is pursed-lip breathing but managing complete sentences. His BP is 140/70 mmHg, pulse 80 bpm and regular, $Sp(O_2)$ 93% o/a, respiratory rate 18 breaths/min and temperature 37°C. Examination of his chest revealed a widespread wheeze with coarse crepitations heard in the left mid-zone. FEV_1:FVC ratio in the clinic today was 69%.

What is the most useful investigation in establishing the diagnosis?

A	Repeat spirometry
B	Chest X-ray
C	V/Q scan
D	High-resolution CT
E	Full blood count

2360

Submit

Previous Question | Skip Question

Calculator

Normal Values

© Pastest 2017

A 65-year-old man with known COPD comes to see you at the Respiratory Clinic. He has been a smoker for 40 years and previously worked in the docks at Southampton. He has experienced no increase in his sputum volume or any change in its colour. On examination, he is pursed-lip breathing but managing complete sentences. His BP is 140/70 mmHg, pulse 80 bpm and regular, Sp(O_2) 93% o/a, respiratory rate 18 breaths/min and temperature 37°C. Examination of his chest revealed a widespread wheeze with coarse crepitations heard in the left mid-zone. FEV_1:FVC ratio in the clinic today was 69%.

What is the most useful investigation in establishing the diagnosis?

A	Repeat spirometry
B	Chest X-ray
C	V/Q scan
D	High-resolution CT
E	Full blood count

Explanation

D	High-resolution CT

Patients with longstanding chronic obstructive pulmonary disease (COPD) often develop localised areas of bronchiectasis because of progressive damage to the lung tissue. It is important to distinguish between this and fibrosis (secondary to asbestos exposure) in the absence of infective processes so that adequate treatment can be employed. The most useful investigation is therefore a CT scan.

A	Repeat spirometry

Spirometry is not useful and it is likely that it would confirm an obstructive picture, with a low level of sensitivity to identify the onset of any restrictive lung disease.

B	Chest X-ray

CXR has only a low pick-up rate for bronchiectasis or pulmonary fibrosis versus CT and would therefore not be considered useful here.

C	V/Q scan

VQ scanning is most useful in identifying evidence of an acute pulmonary embolus. That would not fit with the picture of wheeze and coarse crepitations on auscultation here.

E	Full blood count

FBC may show an increase in Hb because of chronic hypoxia, although this would be non-specific with respect to the cause of any underlying hypoxia (i.e. worsening COPD versus asbestos-related pulmonary fibrosis).

2360

Rate this question:

Next Question

Previous Question | Tag Question

Feedback | End Session

Difficulty: Average

Peer Responses %

Session Progress

Responses Correct:	0
Responses Incorrect:	11
Responses Total:	11
Responses - % Correct:	0%

© Pastest 2017

An 82-year-old lady living in her own home presents with a 3-day history of confusion as noted by her carer. She has had a purulent cough for several days. She has never smoked. Her other health problems include controlled hypertension, osteoarthritis and venous leg ulcers, which limit her mobility. She attends a day hospital 3 days per week, where two other patients have recently been treated for pneumonia with 'atypical features' according to the general practitioner (GP), although you have no further details regarding this. On examination she is mildly confused and drowsy, with mild pyrexia of 37.8°C. Chest examination is abnormal. Routine bloods reveal a neutrophilia with CRP of 220.
Her chest X-ray shows left lower lobe consolidation.

What is the most likely causative organism?

A	*Streptococcus pneumoniae*
B	*Legionella pneumophilia*
C	*Mycoplasma*
D	*Staphylococcus aureus*
E	*Haemophilus influenzae*

6337

Submit

Previous Question | Skip Question

Calculator

Normal Values

© Pastest 2017

An 82-year-old lady living in her own home presents with a 3-day history of confusion as noted by her carer. She has had a purulent cough for several days. She has never smoked. Her other health problems include controlled hypertension, osteoarthritis and venous leg ulcers, which limit her mobility. She attends a day hospital 3 days per week, where two other patients have recently been treated for pneumonia with 'atypical features' according to the general practitioner (GP), although you have no further details regarding this. On examination she is mildly confused and drowsy, with mild pyrexia of 37.8°C. Chest examination is abnormal. Routine bloods reveal a neutrophilia with CRP of 220.
Her chest X-ray shows left lower lobe consolidation.

What is the most likely causative organism?

A	*Streptococcus pneumoniae*
B	*Legionella pneumophilia*
C	*Mycoplasma*
D	*Staphylococcus aureus*
E	*Haemophilus influenzae*

Explanation

A	*Streptococcus pneumoniae*

S. pneumoniae is the commonest cause of community-acquired pneumonia in the elderly. Bacteraemic *S. pneumoniae* pneumonia is the number one cause of mortality in community-acquired pneumonia, representing up to 80% of cases and 70% of all deaths. The short history of onset and left lower lobe consolidation are entirely consistent with *S. pneumoniae* versus an atypical cause.

B	*Legionella pneumophilia*

Legionella is associated with a greater burden of confusion which may be linked to hyponatraemia, and other features such as diarrhoea and elevated transaminases.

C	*Mycoplasma*

Mycoplasma presents in epidemics often associated with institutionalisation, for instance amongst recruits in an army barracks. The acute course and lobar pneumonia seen here are more consistent with *S. pneumoniae*.

D	*Staphylococcus aureus*

S. aureus pneumonia is typically described as following an episode of influenza, and leads to focal consolidation with areas of cavitation.

E	*Haemophilus influenzae*

H. influenzae pneumonia is less common in percentage terms than streptococcal infection, and is more likely to be seen in patients with pre-existing chest disease.

6337

Rate this question:

Next Question

Previous Question | Tag Question

Feedback | End Session

Difficulty: Average

Peer Responses %

Session Progress

Responses Correct:	0
Responses Incorrect:	12
Responses Total:	12
Responses - % Correct:	0%

© Pastest 2017

A 66-year-old lady is admitted for an elective hernia repair under the general surgeons. Of note in her past medical history is hypertension, for which she takes bendrofluazide 2.5 mg od. She is an ex-smoker of 4 years. Three days after the operation, the lady's condition deteriorates and the surgeons ask for your advice. When directly questioned she denies any cough, but feels mild breathlessness and fatigue. Her appetite is also depressed. On examination her temperature is 38°C, blood pressure (BP) 135/90 mmHg, pulse 140 beats per minute, oxygen saturation 91% on air. Examination of the chest demonstrates coarse crepitations at the left lower zone with a dull percussion note. Abdominal examination is unremarkable. The operation scar looks clean, with no signs of infection. Chest X-ray (CXR) reveals an ill-defined mass in the left lower zone in an area of consolidation. The opacity contains an air–fluid level.

What is the most likely diagnosis?

A	Aspiration pneumonia
B	Left lower lobe collapse
C	Pulmonary embolus
D	Lung abscess
E	Transudate pleural effusion

6357

Submit

Previous Question Skip Question

Calculator

Normal Values

Blog About Pastest Contact Us Help

© Pastest 2017

A 66-year-old lady is admitted for an elective hernia repair under the general surgeons. Of note in her past medical history is hypertension, for which she takes bendrofluazide 2.5 mg od. She is an ex-smoker of 4 years. Three days after the operation, the lady's condition deteriorates and the surgeons ask for your advice. When directly questioned she denies any cough, but feels mild breathlessness and fatigue. Her appetite is also depressed. On examination her temperature is 38°C, blood pressure (BP) 135/90 mmHg, pulse 140 beats per minute, oxygen saturation 91% on air. Examination of the chest demonstrates coarse crepitations at the left lower zone with a dull percussion note. Abdominal examination is unremarkable. The operation scar looks clean, with no signs of infection. Chest X-ray (CXR) reveals an ill-defined mass in the left lower zone in an area of consolidation. The opacity contains an air–fluid level.

What is the most likely diagnosis?

A	Aspiration pneumonia
B	Left lower lobe collapse
C	Pulmonary embolus
D	Lung abscess
E	Transudate pleural effusion

Explanation

D	Lung abscess

All of the above options could account for deterioration postoperatively, but the clinical findings together with the CXR findings suggest lung abscess to be the most likely complication following the general anaesthetic. An air–fluid level is characteristic of a lung abscess. A contrast-enhanced computerised tomography (CT) scan would show the abscess more clearly.

A	Aspiration pneumonia

Although aspiration pneumonia may cause the pyrexia and shortness of breath seen here, it's much more likely to be associated with right-sided consolidation.

B	Left lower lobe collapse

The air–fluid level directs us more towards an abscess rather than pure collapse as the underlying cause of symptoms here.

C	Pulmonary embolus

At least early on, significant CXR changes in PE would be unexpected. The air–fluid level also suggests an abscess rather than consolidation associated with lung infarction.

E	Transudate pleural effusion

Transudate pleural effusions are more likely to appear as bilateral uncomplicated effusions rather than the picture seen here.

6357

Rate this question:

Next Question

Previous Question | Tag Question

Feedback | End Session

Difficulty: Average

Peer Responses %

Session Progress

Responses Correct:	0
Responses Incorrect:	13
Responses Total:	13
Responses - % Correct:	0%

© Pastest 2017

A 40-year-old single male carpenter presents to casualty with a three-week history of increasing shortness of breath. He is a lifelong non-smoker. Temperature on admission is 38.2°C. On auscultation of his chest he has bilateral inspiratory crepitations. The chest X-ray is reported as patchy opacification throughout both lung fields. There are no signs of peripheral oedema, and he is thin with a BMI of 19.5. You ask him to walk the length of the ward holding a portable pulse oximeter, and note that his oxygen saturation begins to fall rapidly.

Investigations:

ABG	on air
pH	7.36
$p(O_2)$	8.0 kPa
$p(CO_2)$	5.1 kPa
HCO_3	20.1

Which of the following represents the most likely underlying diagnosis in this case?

A	Community-acquired pneumonia
B	Fibrosing alveolitis
C	*Pneumocystis jirovecii* pneumonia (PCP)
D	Pulmonary oedema
E	Pulmonary embolism

6523

Submit

Previous Question | Skip Question

Calculator

Normal Values

© Pastest 2017

A 40-year-old single male carpenter presents to casualty with a three-week history of increasing shortness of breath. He is a lifelong non-smoker. Temperature on admission is 38.2°C. On auscultation of his chest he has bilateral inspiratory crepitations. The chest X-ray is reported as patchy opacification throughout both lung fields. There are no signs of peripheral oedema, and he is thin with a BMI of 19.5. You ask him to walk the length of the ward holding a portable pulse oximeter, and note that his oxygen saturation begins to fall rapidly.

Investigations:

ABG	on air
pH	7.36
$p(O_2)$	8.0 kPa
$p(CO_2)$	5.1 kPa
HCO_3	20.1

Which of the following represents the most likely underlying diagnosis in this case?

A	Community-acquired pneumonia
B	Fibrosing alveolitis
C	*Pneumocystis jirovecii* pneumonia (PCP)
D	Pulmonary oedema
E	Pulmonary embolism

Explanation

C *Pneumocystis jirovecii* pneumonia (PCP)

PCP is most commonly seen related to immunodeficiency in patients who are HIV-positive. The fact that he desaturates on a walk test is typical of this condition, as are the clinical signs which are much more prominent than X-ray changes. Incidence is highest when the CD4 lymphocyte count falls below 100/mm^3. Diagnosis is via sputum to look for cysts of PCP or via bronchioalvelolar lavage fluid if sputum is negative. Treatment is with co-trimoxazole given either orally or IV; alternatives include pentamidine. After one episode of infection, patients should be maintained on prophylactic co-trimoxazole to prevent further acute episodes.

A Community-acquired pneumonia

The subacute course of this patient's disease, coupled with the patchy bilateral areas of consolidation, is inconsistent with common causes of community-acquired pneumonia such as *S. pneumoniae*.

B Fibrosing alveolitis

The time course of this patient's symptoms would be considered too short for the onset of fibrosing alveolitis. The desaturation on exercise is also characteristic of PCP.

D Pulmonary oedema

Patchy consolidation and pyrexia are more consistent with infection versus cardiac failure. The lack of significant cardiac risk factors also counts against pulmonary oedema as the cause of symptoms seen here.

E Pulmonary embolism

Acute-onset pleuritic chest pain is absent from the history given here, and the patchy consolidation and pyrexia don't fit with an acute PE.

6523

Rate this question:

Next Question

Previous Question | Tag Question

Feedback | End Session

Difficulty: Easy

Peer Responses %

Session Progress

Responses Correct:	0
Responses Incorrect:	14
Responses Total:	14
Responses - % Correct:	0%

© Pastest 2017

A 67-year-old obese man with known mild chronic obstructive pulmonary disease (COPD) presents via ambulance. He is drowsy and his wife is unable to rouse him. He usually has a good level of functioning , is able to walk to the local pub, uses a Salbutamol inhaler only, and continues to smoke 5 cigarettes per day.

You arrange a chest X-ray and blood gases:

pH	7.2
$p_a(CO_2)$	8.7 kPa
$p_a(O_2)$	6.3 kPa
HCO_3 (measured)	24.7 mmol/l

Which of the following best describes the blood gas results?

A	Mixed metabolic and respiratory acidosis
B	Metabolic acidosis
C	Fully compensated respiratory acidosis
D	Respiratory acidosis
E	Metabolic alkalosis

6539

Submit

Previous Question | Skip Question

Calculator

Normal Values

© Pastest 2017

A 67-year-old obese man with known mild chronic obstructive pulmonary disease (COPD) presents via ambulance. He is drowsy and his wife is unable to rouse him. He usually has a good level of functioning , is able to walk to the local pub, uses a Salbutamol inhaler only, and continues to smoke 5 cigarettes per day.

You arrange a chest X-ray and blood gases:

pH	7.2
$p_a(CO_2)$	8.7 kPa
$p_a(O_2)$	6.3 kPa
HCO_3 (measured)	24.7 mmol/l

Which of the following best describes the blood gas results?

A	Mixed metabolic and respiratory acidosis
B	Metabolic acidosis
C	Fully compensated respiratory acidosis
D	Respiratory acidosis
E	Metabolic alkalosis

Explanation

This is a respiratory acidosis, characterised by raised $p_a(CO_2)$, decreased pH and serum bicarbonate in the normal range. Exacerbation of COPD is a common cause, although the fact that the bicarbonate is in the normal range suggests his deterioration has been too rapid to allow renal compensation. Pneumonia or abnormalities of the thoracic cage, such as those related to spina bifida may also be responsible. In compliant patients, non-invasive positive pressure ventilation (NIPPV) may be an option. Alternatives include doxapram, a central respiratory stimulant. These would be combined with appropriate antimicrobial therapy. Unfortunately, many patients with COPD are unsuitable for formal intubation and ventilation.

6539

Rate this question:

Next Question

Previous Question | Tag Question

Feedback | End Session

Difficulty: Easy

Peer Responses %

Session Progress

Responses Correct:	0
Responses Incorrect:	15
Responses Total:	15
Responses - % Correct:	0%

© Pastest 2017

A 65-year-old patient presents with increased shortness of breath (SOB) to the Respiratory Outpatient Clinic. This has been progressively worsening over the past 6 months. He is a farmer, a smoker and has two daughters with asthma. There was obvious wheeze and coarse end-inspiratory crackles on examination of the chest. A chest X-ray shows diffuse non-specific changes consistent with lung disease.

Which would be the next most appropriate investigation?

A	Peak expiratory flow rate (PEFR)
B	Spirometry and reversibility
C	Serum precipitins
D	Bronchoalveolar lavage
E	CT thorax

6604

Submit

Previous Question | Skip Question

Calculator

Normal Values

© Pastest 2017

A 65-year-old patient presents with increased shortness of breath (SOB) to the Respiratory Outpatient Clinic. This has been progressively worsening over the past 6 months. He is a farmer, a smoker and has two daughters with asthma. There was obvious wheeze and coarse end-inspiratory crackles on examination of the chest. A chest X-ray shows diffuse non-specific changes consistent with lung disease.

Which would be the next most appropriate investigation?

A	Peak expiratory flow rate (PEFR)
B	Spirometry and reversibility
C	Serum precipitins
D	Bronchoalveolar lavage
E	CT thorax

Explanation

B Spirometry and reversibility

This man either has asthma, chronic obstructive pulmonary disease or farmer's lung. Spirometry and reversibility would be the investigation of choice. A restrictive defect would support a diagnosis of farmer's lung; an obstructive defect with reversibility would support a diagnosis of asthma; respiratory obstruction without reversibility would support a diagnosis of COPD. Management of farmer's lung involves avoidance of exposure to hay moulds. High-dose steroid therapy may be useful in initial resolution of symptoms.

A Peak expiratory flow rate (PEFR)

PEFR would only provide hints as to a diagnosis of obstructive lung disease and wouldn't differentiate between asthma and COPD.

C Serum precipitins

Precipitating antibodies will show evidence of exposure to actinomycetes but may not necessarily indicate disease.

D Bronchoalveolar lavage

This may indicate lymphocytosis in extrinsic allergic alveolitis, but is invasive and wouldn't therefore be an appropriate next test.

E CT thorax

CT thorax is likely to show structural changes, but wouldn't indicate the severity of obstructive or restrictive lung disease.

6604

Rate this question:

Next Question

Previous Question | Tag Question

Feedback | End Session

Difficulty: Average

Peer Responses %

Session Progress

Responses Correct:	0
Responses Incorrect:	16
Responses Total:	16
Responses - % Correct:	0%

© Pastest 2017

A 70-year-old farmer is admitted with a 4-day history of feeling increasingly short of breath. He tells you he was kicked by a cow and was laid up with a swollen leg before the symptoms started. On examination there is extensive bruising and haematoma around the left knee, and the leg is more swollen than the right. He has bilateral basal crackles and occasional wheezes on inspiration, blood pressure (BP) is 110/80 mmHg and pulse is 105 and regular; oxygen saturations 89–91% on pulse oximetry. Chest X-ray reveals nil of note.

Which of the following represents the best treatment choice for this man?

A	Oral prednisolone
B	Anticoagulation
C	Intravenous furosemide
D	Nebulised salbutamol
E	Penicillin IV

6605

Submit

Previous Question | Skip Question

Calculator

Normal Values

© Pastest 2017

A 70-year-old farmer is admitted with a 4-day history of feeling increasingly short of breath. He tells you he was kicked by a cow and was laid up with a swollen leg before the symptoms started. On examination there is extensive bruising and haematoma around the left knee, and the leg is more swollen than the right. He has bilateral basal crackles and occasional wheezes on inspiration, blood pressure (BP) is 110/80 mmHg and pulse is 105 and regular; oxygen saturations 89–91% on pulse oximetry. Chest X-ray reveals nil of note.

Which of the following represents the best treatment choice for this man?

A	Oral prednisolone
B	Anticoagulation
C	Intravenous furosemide
D	Nebulised salbutamol
E	Penicillin IV

Explanation

B	Anticoagulation

We are presented here with a patient who has had a blow to the knee, a period of inactivity and now has hypoxia with circulatory compromise with no signs of severe asthma or heart failure seen on examination or X-ray. Given the differential leg size, pulmonary embolus is the most likely diagnosis and anticoagulation the treatment of choice. The injury to the knee is some days old, and therefore anticoagulation is unlikely to result in increased size of the knee haematoma. He may well also have other lung disease related to his farming occupation that accounts for the wheezes and crackles heard on auscultation.

A	Oral prednisolone

This would be an appropriate treatment for an exacerbation of asthma or COPD. The lack of significant wheeze counts against asthma as the cause of his symptoms here.

C	Intravenous furosemide

This would be an appropriate treatment for cardiac failure/pulmonary oedema. The normal CXR counts against heart failure as the likely cause of his symptoms here.

D	Nebulised salbutamol

This would be an appropriate treatment for an exacerbation of asthma or COPD. The lack of significant wheeze, and relatively acute onset of symptoms, counts against asthma or COPD as the underlying cause of this patient's symptoms.

E	Penicillin IV

This would be an appropriate treatment for pneumonia. The negative chest X-ray and absence of features such as pyrexia and raised inflammatory markers makes pneumonia a less likely diagnosis in this case.

6605

Rate this question:

Next Question

Previous Question | Tag Question

Feedback | End Session

Difficulty: Average

Peer Responses %

Session Progress

Responses Correct:	0
Responses Incorrect:	17
Responses Total:	17
Responses - % Correct:	0%

© Pastest 2017

A 24-year-old patient is admitted with acute asthma. pH is 7.35, $p_a(O_2)$ is 7.1 kPa, and $p_a(CO_2)$ is 5.1 kPa. She has generalised wheeze and poor air entry on clinical examination and looks tired. She normally takes beclomethasone 500 g bd for her asthma.

Investigations:

pH	7.35
$p_a(O_2)$	7.1 kPa
$p_a(CO_2)$	5.1 kPa

Which of the following would be the most appropriate next management step?

A	Back-to-back salbutamol nebulisers and admission to the medical ward
B	Back-to-back salbutamol nebulisers, IV corticosteroids and admission to the medical high-dependency unit (HDU)
C	IV hydrocortisone
D	Nebuliser therapy and later discharge from the Emergency Department
E	Addition of long-acting β-agonists to her therapy

6606

Submit

Previous Question Skip Question

Calculator

Normal Values

© Pastest 2017

A 24-year-old patient is admitted with acute asthma. pH is 7.35, $p_a(O_2)$ is 7.1 kPa, and $p_a(CO_2)$ is 5.1 kPa. She has generalised wheeze and poor air entry on clinical examination and looks tired. She normally takes beclomethasone 500 g bd for her asthma.

Investigations:

pH	7.35
$p_a(O_2)$	7.1 kPa
$p_a(CO_2)$	5.1 kPa

Which of the following would be the most appropriate next management step?

A	Back-to-back salbutamol nebulisers and admission to the medical ward
B	Back-to-back salbutamol nebulisers, IV corticosteroids and admission to the medical high-dependency unit (HDU)
C	IV hydrocortisone
D	Nebuliser therapy and later discharge from the Emergency Department
E	Addition of long-acting β-agonists to her therapy

Explanation

B	Back-to-back salbutamol nebulisers, IV corticosteroids and admission to the medical high-dependency unit (HDU)

Respiratory muscle fatigue and acidosis are known to worsen established hypoxia and lead to a vicious circle of further muscle weakness. As such, early admission to the medical HDU should be considered. It is likely this patient will rapidly need ventilatory support ± intubation. Long-term she is likely to require the addition of long-acting β-agonists to her therapy. A combination inhaler such as salmeterol/fluticasone (sere tide) may be the most effective way to deliver the two drugs together.

A	Back-to-back salbutamol nebulisers and admission to the medical ward

Her O_2 is low and CO_2 raised, indicating a severe asthma attack. Salbutamol nebulisation represents a significant component of her management, but the medical ward represents an inadequate place of care; she should be managed in a critical care area.

C	IV hydrocortisone

This represents an appropriate therapy but should not represent the sole management of her condition.

D	Nebuliser therapy and later discharge from the Emergency Department

This patient is having a severe asthma attack – nebuliser monotherapy and discharge without further investigation/assessment would be inappropriate.

E	Addition of long-acting β-agonists to her therapy

This will likely be required in due course, but does not represent the most appropriate **next** step in her management.

6606

Rate this question:

Next Question

Previous Question | Tag Question

Feedback | End Session

Difficulty: Average

Peer Responses %

Session Progress

Responses Correct:	0
Responses Incorrect:	18
Responses Total:	18
Responses - % Correct:	0%

Blog About Pastest Contact Us Help

© Pastest 2017

A 46-year-old man presents with a persistent dry cough and shortness of breath. There has been a history of fatigue over the past few months and he has recently lost his job. On examination there are diffuse crackles on auscultation of the lung fields. He also has a nodular rash on his shins. Chest X-ray reveals bilateral hilar enlargement. There is a diffuse increase in globulins.

Which of the following represents the best initial step for this patient?

A	Oral prednisolone
B	Oral methotrexate
C	Chemotherapy for myeloma
D	Bronchoscopy to look for mycobacteria
E	Oral azathioprine

6607

Submit

Previous Question | Skip Question

Calculator

Normal Values

© Pastest 2017

A 46-year-old man presents with a persistent dry cough and shortness of breath. There has been a history of fatigue over the past few months and he has recently lost his job. On examination there are diffuse crackles on auscultation of the lung fields. He also has a nodular rash on his shins. Chest X-ray reveals bilateral hilar enlargement. There is a diffuse increase in globulins.

Which of the following represents the best initial step for this patient?

A	Oral prednisolone
B	Oral methotrexate
C	Chemotherapy for myeloma
D	Bronchoscopy to look for mycobacteria
E	Oral azathioprine

Explanation

A	Oral prednisolone

This patient has sarcoidosis, a chronic granulomatous disorder of unknown origin, characterised histologically by the presence of non-caseating granulomas. Work-up involves chest X-ray and biopsy of easily accessible affected tissue. Corticosteroids, namely oral prednisolone, remain the initial mainstay of treatment, although they are reserved for patients with significant symptoms (in this case, cough and shortness of breath) or severe changes on CXR. Steroid-sparing agents such as methotrexate or hydroxychloroquine may be added if required. Most patients achieve remission within 2 years, though as yet there are no curative therapies and relapses are common.

B	Oral methotrexate

In patients who are unresponsive to, or dependent on, steroids, methotrexate can be considered as a steroid-sparing option. It should not be considered a first-line option in patients requiring treatment.

C	Chemotherapy for myeloma

Myeloma tends to present in older patients, with symptoms such as bone pain, fatigue secondary to anaemia, recurrent infections, hypercalcaemia and renal symptoms. The persistent cough and CXR findings are more in keeping with sarcoidosis than myeloma.

D	Bronchoscopy to look for mycobacteria

Mycobacterium tuberculosis is the organism responsible for TB. There is no mention in the history of night sweats or weight loss; the history and examination findings here are more in keeping with sarcoid than TB.

E	Oral azathioprine

In patients who are unresponsive to, or dependent on, steroids, azathioprine can be considered as a steroid-sparing option. It should not be considered a first-line option in patients requiring treatment.

6607

Rate this question:

Next Question

Previous Question	Tag Question
Feedback	End Session

Difficulty: Average

Peer Responses %

Session Progress

Responses Correct:	0
Responses Incorrect:	19
Responses Total:	19
Responses - % Correct:	0%

© Pastest 2017

A 28-year-old man is referred from the Infertility Clinic. He has a past history of recurrent sinusitis and a persistent cough with sputum production. Chest X-ray displays hyperinflated lung fields with shadowing at the lung bases, and it also appears to be mis-labelled with inappropriate left and right markers. Sweat test reveals a sodium concentration of 50 mmol/l.

What is the most likely diagnosis?

A	Bronchiectasis
B	Cystic fibrosis
C	α1-antitrypsin deficiency
D	Situs inversus
E	Kartagener syndrome

6608

Submit

Previous Question | Skip Question

Calculator

Normal Values

© Pastest 2017

A 28-year-old man is referred from the Infertility Clinic. He has a past history of recurrent sinusitis and a persistent cough with sputum production. Chest X-ray displays hyperinflated lung fields with shadowing at the lung bases, and it also appears to be mis-labelled with inappropriate left and right markers. Sweat test reveals a sodium concentration of 50 mmol/l.

What is the most likely diagnosis?

A	Bronchiectasis
B	Cystic fibrosis
C	α1-antitrypsin deficiency
D	Situs inversus
E	Kartagener syndrome

Explanation

E	Kartagener syndrome

This is primary ciliary dyskinesia associated with recurrent sinusitis, bronchiectasis and azoospermia. The CXR is correctly labelled and this patient has situs inversus with transposition of the major organs (as is the case in up to 50% of patients with ciliary dyskinesia). It also causes azoospermia, explaining his infertility. The mainstay of treatment for bronchiectasis is appropriate self-physio with postural drainage. Some physicians advocate the use of rotating antibiotic therapy, but this is associated in many cases with multi-drug resistance.

A	Bronchiectasis

While bronchiectasis is a component of Kartagener syndrome, this alone would not adequately explain his presentation; Kartagener syndrome also consists of sinusitis and dextrocardia, and can cause azoospermia.

B	Cystic fibrosis

This typically presents in infancy with respiratory symptoms and features of pancreatic insufficiency. Cystic fibrosis is diagnosed when the sweat test reveals a chloride concentration of >60 mmol/l.

C	α1-antitrypsin deficiency

This is associated with respiratory symptoms, predominantly cough and dyspnoea, but would not adequately explain his situs inversus or infertility.

D	Situs inversus

While this patient has situs inversus as a component of his Kartagener syndrome, it would not adequately account for his sinusitis and infertility.

6608

Rate this question:

Next Question

Previous Question	Tag Question
Feedback	End Session

Difficulty: Average

Peer Responses %

Session Progress

Responses Correct:	0
Responses Incorrect:	20
Responses Total:	20
Responses - % Correct:	0%

© Pastest 2017

A 64-year-old woman is referred with worsening COPD. She has a 10 pack-year smoking history. Her exercise tolerance has been steadily decreasing due to dyspnoea, and she is only able to walk a short distance on the flat now. FEV1 is now only 38% of predicted. She has tried PRN salbutamol but this has not helped.

Which of the following represents the most appropriate next step for this patient?

A	Switch salbutamol to PRN ipratropium
B	Start BD inhaled beclomethasone
C	Start oral prednisolone 5 mg OD
D	Start oral theophylline
E	Start regular high-dose inhaled fluticasone and inhaled long-acting β-agonist

6609

Submit

Previous Question | Skip Question

Calculator

Normal Values

© Pastest 2017

A 64-year-old woman is referred with worsening COPD. She has a 10 pack-year smoking history. Her exercise tolerance has been steadily decreasing due to dyspnoea, and she is only able to walk a short distance on the flat now. FEV1 is now only 38% of predicted. She has tried PRN salbutamol but this has not helped.

Which of the following represents the most appropriate next step for this patient?

A	Switch salbutamol to PRN ipratropium
B	Start BD inhaled beclomethasone
C	Start oral prednisolone 5 mg OD
D	Start oral theophylline
E	Start regular high-dose inhaled fluticasone and inhaled long-acting β-agonist

Explanation

E	Start regular high-dose inhaled fluticasone and inhaled long-acting β-agonist

This patient has severe COPD. Recent studies have demonstrated that high-dose combination therapy with fluticasone and long-acting β-agonist may slow deterioration in FEV1. Low-dose fluticasone, beclomethasone, ipratropium and ventolin have no impact on the deterioration of lung function. The TORCH study (2007) showed a reduction in exacerbations with respect to dual LABA and inhaled steroid therapy. It did, however, show that the risk of pneumonia was increased in the treated group. Current NICE guidance states that for patients with FEV_1 <50%, either LABA with an inhaled corticosteroid (ICS) in a combination inhaler or LAMA should be offered.

A	Switch salbutamol to PRN ipratropium

NICE guidelines state that a once-daily long-acting muscarinic antagonist should be offered in preference to four-times-daily short-acting muscarinic antagonists to people with stable COPD who remain breathless or have exacerbations despite using short-acting bronchodilators as required.

B	Start BD inhaled beclomethasone

NICE guidelines state that if FEV_1 is <50% predicted then give either LABA with an inhaled corticosteroid (ICS) in a combination inhaler, or LAMA. Corticosteroid monotherapy for COPD is not recommended.

C	Start oral prednisolone 5 mg OD

Prednisolone would be appropriate if the patient had presented acutely with an exacerbation of COPD (though a higher dose would be required), but NICE guidelines state that 'Maintenance use of oral corticosteroid therapy in COPD is not normally recommended'.

D	Start oral theophylline

NICE guidance states that 'Theophylline should only be used after a trial of short-acting bronchodilators and long-acting bronchodilators' and therefore does not represent the most appropriate next step for this patient.

6609

Rate this question:

Next Question

Previous Question | Tag Question

Feedback | End Session

Difficulty: Difficult

Peer Responses %

Session Progress

Responses Correct:	0
Responses Incorrect:	21
Responses Total:	21
Responses - % Correct:	0%

© Pastest 2017

A tall, 23-year-old man presents to the Emergency Department for review following sudden-onset left-sided pleuritic chest pain. On examination, he is 198 cm tall with an arm span of 192 cm, and he is tachycardic at 124 bpm. BP is 128/92 mmHg. There is evidence of reduced air entry on the left-hand side and a 'click' on auscultation. His past medical history includes recurrent shoulder dislocations; he is on no medications.

What is the most likely diagnosis?

A	Pneumothorax
B	Pulmonary embolus
C	Pneumonia
D	Costochondritis
E	Viral pleurisy

6610

Submit

Previous Question Skip Question

Calculator

Normal Values

Blog About Pastest Contact Us Help

© Pastest 2017

A tall, 23-year-old man presents to the Emergency Department for review following sudden-onset left-sided pleuritic chest pain. On examination, he is 198 cm tall with an arm span of 192 cm, and he is tachycardic at 124 bpm. BP is 128/92 mmHg. There is evidence of reduced air entry on the left-hand side and a 'click' on auscultation. His past medical history includes recurrent shoulder dislocations; he is on no medications.

What is the most likely diagnosis?

A	Pneumothorax
B	Pulmonary embolus
C	Pneumonia
D	Costochondritis
E	Viral pleurisy

Explanation

A	Pneumothorax

This patient is tall and thin, with a history of joint dislocation. The suspicion is that he may have Marfan's disease and his symptoms are suggestive of pneumothorax. Management is determined by appearance on chest X-ray and response to air aspiration. Where patients have failed air aspiration, chest drain insertion is the next therapy of choice.

B	Pulmonary embolus

The history does not feature classical risk factors for pulmonary embolus, such as immobility/evidence of DVT. The examination finding of reduced air entry also makes this diagnosis less likely than pneumothorax.

C	Pneumonia

We are not given any history of cough/sputum production or fever. Pneumonia would also be less likely to present with acute chest pain than pneumothorax, and fits less well as an explanation than pneumothorax, given the presumed history of Marfan's and systolic click heard on examination (Hamman's sign).

D	Costochondritis

There is no mention of tenderness to palpation, and this diagnosis would not explain the auscultation findings. Costochondritis would be expected to produce localised pain and tenderness.

E	Viral pleurisy

There is no mention of a viral prodrome. The auscultation findings and presumed history of Marfan's make pneumothorax the most likely diagnosis here.

6610

Rate this question:

Next Question

Previous Question | Tag Question

Feedback | End Session

Difficulty: Average

Peer Responses %

Session Progress

Responses Correct:	0
Responses Incorrect:	22
Responses Total:	22
Responses - % Correct:	0%

© Pastest 2017

A 43-year-old solicitor with breast carcinoma presents to the A&E department complaining of a cough and shortness of breath, associated with fever and sharp chest pain. She has only recently finished her last chemotherapy treatment course. She is currently on no treatment and has no allergies. She has no other significant past medical history. One examination, she is dyspnoeic and tachypnoeic at rest and has a fever of 39°C. Pulse oximetry shows her oxygen saturations to be 90%. Examination of her chest shows a dull percussion note in the right upper region of the lung associated with increased vocal resonance and, on auscultation, bronchial breathing can be heard in the same area associated with coarse crackles. In order to confirm the suspected diagnosis, the patient undergoes a transbronchial biopsy. The specimen stains with Gomori methenamine silver and haematoxylin & eosin stains.

What is the most likely diagnosis?

A	Secondary lung tumour
B	Tuberculosis
C	Invasive aspergillosis
D	*Pneumocystis jirovecii* pneumonia
E	Sarcoidosis

6803

Submit

Previous Question | Skip Question

Calculator

Normal Values

© Pastest 2017

A 43-year-old solicitor with breast carcinoma presents to the A&E department complaining of a cough and shortness of breath, associated with fever and sharp chest pain. She has only recently finished her last chemotherapy treatment course. She is currently on no treatment and has no allergies. She has no other significant past medical history. One examination, she is dyspnoeic and tachypnoeic at rest and has a fever of 39°C. Pulse oximetry shows her oxygen saturations to be 90%. Examination of her chest shows a dull percussion note in the right upper region of the lung associated with increased vocal resonance and, on auscultation, bronchial breathing can be heard in the same area associated with coarse crackles. In order to confirm the suspected diagnosis, the patient undergoes a transbronchial biopsy. The specimen stains with Gomori methenamine silver and haematoxylin & eosin stains.

What is the most likely diagnosis?

A	Secondary lung tumour
B	Tuberculosis
C	Invasive aspergillosis
D	*Pneumocystis jirovecii* pneumonia
E	Sarcoidosis

Explanation

C	Invasive aspergillosis

Aspergillus fumigatus is a fungus transmitted to humans via inhalation. Hence, it primarily affects the lungs, causing five main syndromes: asthma, allergic bronchopulmonary aspergillosis (ABPA), aspergilloma, invasive aspergillosis and extrinsic allergic alveolitis (EAA). Asthma is a type-I hypersensitivity reaction to fungal spores whereas ABPA is a type-III hypersensitivity reaction to *A. fumigatus*. An aspergilloma is a fungal ball within a pre-existing lung cavity that may have resulted from tuberculosis, sarcoidosis or another necrotising pulmonary process. It is usually asymptomatic but may cause cough, torrential haemoptysis and fever. Invasive aspergillosis typically manifests with fever, cough, dyspnoea and pleuritic chest pain in patients with prolonged neutropenia or immunosuppression, such as that which occurs after chemotherapy. The CXR in invasive aspergillosis shows consolidation, and the patient has rapidly progressing and worsening hypoxaemia. This CXR appearance progresses despite the use of broad-spectrum antibiotics. The definitive diagnosis of invasive aspergillosis depends upon the demonstration of the organism in tissue. Haematoxylin and eosin (H&E) stain does not stain most fungi, except *Aspergillus* species and the zygomycetes. In *Pneumocystis jirovecii* pneumonia the typical chest X-ray appearance shows a diffuse central alveolar or interstitial infiltrate, although it may appear normal in early disease.

A	Secondary lung tumour

GMS is used to stain fungi and *Pneumocystis jirovecii*, and would not be expected to stain a tumour.

B	Tuberculosis

We are not given any history of contact with TB, or a history of symptoms such as weight loss or night sweats. GMS is used to stain fungi and *Pneumocystis jirovecii*.

D	*Pneumocystis jirovecii* pneumonia

While this does stain with GMS, PJ typically occurs as opportunistic infection in patients with HIV.

E	Sarcoidosis

There is no mention of symptoms such as erythema nodosum or bilateral hilar lymphadenopathy, which is commonly seen on CXR, nor of non-caseating granulomas on biopsy, which are the hallmark of the disease.

6803

Rate this question:

Next Question

Previous Question | Tag Question

Feedback | End Session

Difficulty: Average

Peer Responses %

Session Progress

Responses Correct:	0
Responses Incorrect:	23
Responses Total:	23
Responses - % Correct:	0%

© Pastest 2017

An 18-year-old male is brought to the Emergency Department by his parents who are concerned about the cough and fever that he has developed. The onset of the cough was about 5 days ago and over this time it has progressively worsened. The patient is also producing purulent sputum and complains of feeling short of breath. He has no past medical history and is not on any medication. On examination, he has a fever of 39°C and is visibly tachypnea. Examination of the chest shows reduced expansion on the right side associated with a reduced percussion note and bronchial breathing on auscultation. In addition to bloods, a CXR is taken which demonstrates a lobar consolidation.

What is the most likely cause of this patients symptoms?

A	Staphylococcal pneumonia
B	*Pneumocystis jirovecii* pneumonia
C	*Legionella* pneumonia
D	*Haemophilus influenzae* pneumonia
E	Pneumococcal pneumonia

6804

Submit

Previous Question | Skip Question

Calculator

Normal Values

© Pastest 2017

An 18-year-old male is brought to the Emergency Department by his parents who are concerned about the cough and fever that he has developed. The onset of the cough was about 5 days ago and over this time it has progressively worsened. The patient is also producing purulent sputum and complains of feeling short of breath. He has no past medical history and is not on any medication. On examination, he has a fever of 39°C and is visibly tachypnea. Examination of the chest shows reduced expansion on the right side associated with a reduced percussion note and bronchial breathing on auscultation. In addition to bloods, a CXR is taken which demonstrates a lobar consolidation.

What is the most likely cause of this patients symptoms?

A	Staphylococcal pneumonia
B	*Pneumocystis jirovecii* pneumonia
C	*Legionella* pneumonia
D	*Haemophilus influenzae* pneumonia
E	Pneumococcal pneumonia

Explanation

E	Pneumococcal pneumonia

Despite appropriate antimicrobial therapy, pneumococcal pneumonia remains a cause of significant mortality owing to the ability of the organism to replicate in host tissues.

Young children and elderly adults are particularly prone to infections with *Streptococcus pneumoniae*. This organism is also the commonest cause of community-acquired pneumonia.

Clinical symptoms of this condition include fever and rigors, malaise, anorexia, cough, shortness of breath, production of purulent sputum and pleuritic chest pain. Clinical signs include tachycardia, hypoxia, fever, tachypnoea and signs of pulmonary consolidation (diminished expansion, dullness to percussion, bronchial breathing and increased tactile fremitus).

CXR classically shows lobar consolidation.

A	Staphylococcal pneumonia

The CXR in staphylococcal pneumonia typically shows a bilateral cavitating bronchopneumonia. Primary staphylococcal pneumonia is more commonly seen in children and young patients, with secondary disease being seen most commonly secondary to influenza infection.

B	*Pneumocystis jirovecii* pneumonia

This is the most common opportunistic infection seen in patients with HIV infection.

C	*Legionella* pneumonia

This is associated with a prodromal period of myalgia and headache, initially dry cough, confusion and patchy lower lobe consolidation on CXR. Pleural effusion is seen in as many as 30% of cases. It is associated with poorly maintained air conditioning systems, e.g. hotels, offices, etc.

D	*Haemophilus influenzae* pneumonia

Haemophilus influenzae infections are rare in patients over the age of 6 years, unless immunocompromised. The most common presentation is with meningitis.

6804

Rate this question:

Next Question

Previous Question | Tag Question

Feedback | End Session

Difficulty: Easy

Peer Responses %

Session Progress

Responses Correct:	0
Responses Incorrect:	24
Responses Total:	24
Responses - % Correct:	0%

© Pastest 2017

As the medical registrar, you are asked on the phone by your FY1 to review a 26-year-old male patient who she has just examined. The patient has presented with progressively worsening dyspnoea and chest discomfort over the previous 24 h. He has no past medical history of note, and is a non-smoker. On examination he is tachycardic at 120 bpm and tachypnoeic at 30 bpm, with bilateral wheeze on auscultation. On examination of the supraclavicular areas and neck there is palpable cutaneous emphysema.

What is the most likely diagnosis?

A	Oesophageal rupture
B	Asthma
C	Gas gangrene
D	Pulmonary embolism
E	Lung malignancy

6805

Submit

Previous Question | Skip Question

Calculator

Normal Values

© Pastest 2017

As the medical registrar, you are asked on the phone by your FY1 to review a 26-year-old male patient who she has just examined. The patient has presented with progressively worsening dyspnoea and chest discomfort over the previous 24 h. He has no past medical history of note, and is a non-smoker. On examination he is tachycardic at 120 bpm and tachypnoeic at 30 bpm, with bilateral wheeze on auscultation. On examination of the supraclavicular areas and neck there is palpable cutaneous emphysema.

What is the most likely diagnosis?

A	Oesophageal rupture
B	Asthma
C	Gas gangrene
D	Pulmonary embolism
E	Lung malignancy

Explanation

B	Asthma

Surgical emphysema, also known as subcutaneous emphysema, is a pathological accumulation of air or gas in the subcutaneous tissues of the body. It is a rare condition, but it can occur from air tracking from the lungs (pneumothorax, COPD, asthma), from trauma – particularly barotrauma (pneumo-mediastinum, mechanical ventilation) or, rarely, a rupture of the oesophagus. However, it can also occur from the production of gas within a tissue by an infection such as in gas gangrene. It causes a crackling sensation felt on palpation of the skin of the neck and chest but it may also cause a diffuse swelling of the chest wall and neck.

A	Oesophageal rupture

This is most commonly associated with procedures such as bronchoscopy, with spontaneous rupture occurring most often in association with vomiting. There may be dysphagia, tachycardia, dyspnoea and fever.

C	Gas gangrene

While this can cause cutaneous emphysema, patients are usually significantly unwell, with evidence of sepsis or septic shock and visible necrotic tissue on examination.

D	Pulmonary embolism

This is not commonly associated with cutaneous emphysema, and we are not given any classical risk factors for DVT/PE.

E	Lung malignancy

While lung malignancy can lead to cutaneous emphysema, it is a relatively rare complication; the patient's young age and absence of risk factors for lung malignancy also make this a less likely option.

6805

Rate this question:

Next Question

Previous Question	Tag Question
Feedback	End Session

Difficulty: Easy

Peer Responses %

Session Progress

Responses Correct:	0
Responses Incorrect:	25
Responses Total:	25
Responses - % Correct:	0%

© Pastest 2017

An 18-year-old male attends his GP complaining of fever and a productive cough present for 2 weeks. He initially thought it was flu but the symptoms have been getting worse and not better. He is concerned since he is the main breadwinner at home for his elderly parents, who have just returned from a trip to India. On further questioning he admits to having lost his appetite recently, and at night-time suffers from terrible sweating, drenching the bed sheets. On the basis of the history and his clinical examination, the GP suspects a diagnosis of tuberculosis. An urgent referral is made to the local Chest Clinic to confirm the diagnosis, and tests confirm that the diagnosis is correct. The patient is commenced on standard treatment for pulmonary tuberculosis. He returns to the GP several weeks later, stating that he has noticed deterioration in his eyesight since his diagnosis.

Which of the following is most likely to be responsible for this side effect?

A	Ethambutol
B	Rifampicin
C	Isoniazid
D	Pyrizinamide
E	Streptomycin

6806

Submit

Previous Question Skip Question

Calculator

Normal Values

Blog About Pastest Contact Us Help

© Pastest 2017

An 18-year-old male attends his GP complaining of fever and a productive cough present for 2 weeks. He initially thought it was flu but the symptoms have been getting worse and not better. He is concerned since he is the main breadwinner at home for his elderly parents, who have just returned from a trip to India. On further questioning he admits to having lost his appetite recently, and at night-time suffers from terrible sweating, drenching the bed sheets. On the basis of the history and his clinical examination, the GP suspects a diagnosis of tuberculosis. An urgent referral is made to the local Chest Clinic to confirm the diagnosis, and tests confirm that the diagnosis is correct. The patient is commenced on standard treatment for pulmonary tuberculosis. He returns to the GP several weeks later, stating that he has noticed deterioration in his eyesight since his diagnosis.

Which of the following is most likely to be responsible for this side effect?

A	Ethambutol
B	Rifampicin
C	Isoniazid
D	Pyrizinamide
E	Streptomycin

Explanation

A	Ethambutol

The standard medical treatment of pulmonary tuberculosis consists of an initial phase of 2 months on rifampicin, isoniazid, pyrazinamide and ethambutol. This is followed by a further 4-month continuation phase on isoniazid and rifampicin only. There are some combination preparations that may also be used, but this depends on their availability. Prior to treatment, it is imperative to stress the importance of compliance. Also, both liver and renal function should be assessed prior to commencing therapy. Visual acuity, colour vision and visual fields should also be tested, preferably by an ophthalmologist, both before and during treatment with ethambutol since ocular toxicity may occur.

B	Rifampicin

This is associated with orange discoloration of secretions such as tears and urine, GI symptoms and alteration of hepatic function.

C	Isoniazid

This is associated with peripheral neuropathy in high doses, GI upset, agranulocytosis and haemolytic anaemia.

D	Pyrizinamide

This is associated with GI upset and hepatotoxicity.

E	Streptomycin

This is associated with vestibular and renal toxicity.

6806

Rate this question:

Next Question

Previous Question	Tag Question
Feedback	End Session

Difficulty: Average

Peer Responses %

Session Progress

Responses Correct:	0
Responses Incorrect:	26
Responses Total:	26
Responses - % Correct:	0%

© Pastest 2017

A 55-year-old man presents to his GP with his wife complaining of 3–4 months of increased shortness of breath, irritability and daytime somnolence. The patient is a known smoker of a pack a day. He reports no other medical problems and is not on any medication. Clinical examination shows the patient to have a BMI of 22, with mild peripheral oedema and cyanosis. The patient is tachypnoeic. Examination of the chest shows hyperinflation with the use of accessory muscles of respiration and quiet breath sounds. Pulse oximetry shows a pa(O_2) of 94%. Appropriate investigations are initiated for the patient, including lung function tests which show non-reversible obstruction and air trapping. Additionally, the patient is referred to the sleep disorders unit of the nearest specialised ear, nose and throat hospital where arterial blood gases show a chronic respiratory acidosis.

The results of the sleep study are below:

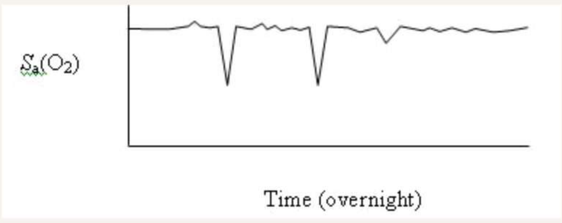

What is the most likely diagnosis for this patient's symptoms?

A	Obstructive sleep apnoea
B	Pickwickian syndrome
C	Chronic obstructive pulmonary disease (COPD) and nocturnal hypoventilation
D	Chronic obstructive pulmonary disease (COPD) and simple snoring
E	Narcolepsy

6807

Submit

Previous Question | Skip Question

Calculator

Normal Values

© Pastest 2017

A 55-year-old man presents to his GP with his wife complaining of 3–4 months of increased shortness of breath, irritability and daytime somnolence. The patient is a known smoker of a pack a day. He reports no other medical problems and is not on any medication. Clinical examination shows the patient to have a BMI of 22, with mild peripheral oedema and cyanosis. The patient is tachypnoeic. Examination of the chest shows hyperinflation with the use of accessory muscles of respiration and quiet breath sounds. Pulse oximetry shows a pa(O_2) of 94%. Appropriate investigations are initiated for the patient, including lung function tests which show non-reversible obstruction and air trapping. Additionally, the patient is referred to the sleep disorders unit of the nearest specialised ear, nose and throat hospital where arterial blood gases show a chronic respiratory acidosis.

The results of the sleep study are below:

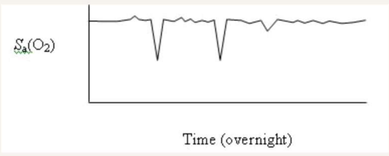

What is the most likely diagnosis for this patient's symptoms?

A	Obstructive sleep apnoea
B	Pickwickian syndrome
C	Chronic obstructive pulmonary disease (COPD) and nocturnal hypoventilation
D	Chronic obstructive pulmonary disease (COPD) and simple snoring
E	Narcolepsy

Explanation

COPD patients commonly suffer from nocturnal oxygen desaturation which is not usually caused by sleep apnoea. Sleep-related hypoxaemia can result in the patient reporting morning headaches and daytime somnolence. The diagnosis is made via overnight home monitoring with a pulse oximeter which shows dramatic falls in saturation levels that occur during REM sleep. Pickwickian syndrome is the combination of severe obesity, a plethoric face and obstructive sleep apnoea causing hypoxia and hypercapnia resulting in marked daytime somnolence. It is named after the 'fat and red-faced boy in a state of somnolency' as described in the novel *The Pickwick Papers* by Charles Dickens. Narcolepsy is a neurological disorder characterised by a sudden and uncontrollable, though often brief, compulsion to sleep sometimes accompanied by cataplexy and sleep paralysis.

6807

Rate this question:

Next Question

Previous Question | Tag Question

Feedback | End Session

Difficulty: Average

Peer Responses %

Session Progress

Responses Correct:	0
Responses Incorrect:	27
Responses Total:	27
Responses - % Correct:	0%

© Pastest 2017

A 30-year-old man who is fit and well is admitted with sudden onset shortness of breath associated with a sharp chest pain made worse with coughing that began suddenly as the patient was working on his computer. He is fit and well and is not on any medication. His BP is 145/70 mmHg and his pulse is 70/min and regular. After clinical examination of the patient, a CXR is requested, which confirms the presence of a pneumothorax.

Which of the following signs would be LEAST likely to have been elicited during the clinical examination/initial investigations?

A	Deviation of the trachea
B	Unilateral reduced expansion
C	Saturation of 97% on air
D	Localised hyperresonant percussion note
E	Unilateral absent breath sounds

6808

Submit

Previous Question | Skip Question

Calculator

Normal Values

© Pastest 2017

A 30-year-old man who is fit and well is admitted with sudden onset shortness of breath associated with a sharp chest pain made worse with coughing that began suddenly as the patient was working on his computer. He is fit and well and is not on any medication. His BP is 145/70 mmHg and his pulse is 70/min and regular. After clinical examination of the patient, a CXR is requested, which confirms the presence of a pneumothorax.

Which of the following signs would be LEAST likely to have been elicited during the clinical examination/initial investigations?

A	Deviation of the trachea
B	Unilateral reduced expansion
C	Saturation of 97% on air
D	Localised hyperresonant percussion note
E	Unilateral absent breath sounds

Explanation

A pneumothorax is air in the intrapleural space that may result in a partial or total collapse of the lung. Often a pneumothorax is spontaneous and this type is more likely to occur in young thin men. A secondary pneumothorax is more likely to occur in the presence of an underlying lung disease. Patients may be asymptomatic or they may present with sudden onset of shortness of breath and pleuritic chest pain. The classical signs of a pneumothorax on clinical examination of the chest include: reduced expansion on the affected side, hyperresonant percussion note and diminished breath sounds. A deviated trachea (away from the affected side) is usually seen more in a tension pneumothorax. Subcutaneous emphysema may also occur with a pneumothorax and is characterised by skin crepitations on palpation.

6808

Rate this question:

Next Question

Previous Question | Tag Question

Feedback | End Session

Difficulty: Average

Peer Responses %

Session Progress

Responses Correct:	0
Responses Incorrect:	28
Responses Total:	28
Responses - % Correct:	0%

© Pastest 2017

A 63-year-old man was brought to the casualty department by a 'blue light' ambulance after having been found at home by his daughter. It transpires that the daughter had gone out for 15 minutes and upon her return had discovered her father collapsed but conscious. She does not live with her father so was not aware of any recent health problems that her father had, but she knew that he was on medication for blood pressure and his heart. She recalls that her father was complaining of some retrosternal discomfort earlier and that he was slightly more short of breath than usual. She reports that he is known to have had a heart attack 6 months previously. The paramedics have initiated volume replacement and protected the airway. In the casualty department, clinical examination shows the patient to be dyspnoeic and tachypnoeic, with a raised JVP. Appropriate bloods are obtained and fluid replacement continued. An ECG is obtained which shows non-specific ST-T-wave abnormalities. Unfortunately, shortly after his arrival in the casualty department his condition deteriorates and he has a cardiac arrest. He is resuscitated and transferred to the ITU where he is ventilated but his condition continues to deteriorate.

What is the most likely diagnosis?

A	Haemothorax
B	Acute pulmonary embolus
C	Left ventricular failure
D	Acute respiratory distress syndrome (ARDS)
E	Fat embolus

6809

Submit

Previous Question | Skip Question

Calculator

Normal Values

© Pastest 2017

A 63-year-old man was brought to the casualty department by a 'blue light' ambulance after having been found at home by his daughter. It transpires that the daughter had gone out for 15 minutes and upon her return had discovered her father collapsed but conscious. She does not live with her father so was not aware of any recent health problems that her father had, but she knew that he was on medication for blood pressure and his heart. She recalls that her father was complaining of some retrosternal discomfort earlier and that he was slightly more short of breath than usual. She reports that he is known to have had a heart attack 6 months previously. The paramedics have initiated volume replacement and protected the airway. In the casualty department, clinical examination shows the patient to be dyspnoeic and tachypnoeic, with a raised JVP. Appropriate bloods are obtained and fluid replacement continued. An ECG is obtained which shows non-specific ST-T-wave abnormalities. Unfortunately, shortly after his arrival in the casualty department his condition deteriorates and he has a cardiac arrest. He is resuscitated and transferred to the ITU where he is ventilated but his condition continues to deteriorate.

What is the most likely diagnosis?

A	Haemothorax
B	Acute pulmonary embolus
C	Left ventricular failure
D	Acute respiratory distress syndrome (ARDS)
E	Fat embolus

Explanation

B	Acute pulmonary embolus

Pulmonary embolism (PE) is an often fatal complication of underlying venous thrombosis in the legs or pelvis. Microthrombi break off and pass through the heart before lodging in the pulmonary circulation. The classical triad of symptoms of PE – haemoptysis, shortness of breath and pleuritic chest pain – occur in less than a fifth of patients eventually diagnosed with PE. Massive PE causes hypotension due to acute right heart failure.

A	Haemothorax

A haemothorax typically occurs in the context of trauma, which is not seen in the history here, and is not as likely a diagnosis as PE in this case.

C	Left ventricular failure

Left ventricular failure can occur after an acute myocardial infarction, but this patient's symptoms (specifically haemoptysis) and the ECG changes are not suggestive of this diagnosis.

D	Acute respiratory distress syndrome (ARDS)

ARDS may be caused by lung injury or may occur secondary to a systemic illness such as sepsis or pancreatitis. ARDS is characterised by respiratory failure not of cardiogenic or hypovolaemic origin, occurring within 1 week of a precipitating trauma/condition, with the presence of bilateral opacities on CXR. Clinical features include dyspnoea, tachypnoea, tachycardia, cyanosis and low pO_2.

E	Fat embolus

Fat embolism occurs following trauma to the long bones or pelvis, following parenteral lipid infusion, or recent corticosteroid administration.

6809

Rate this question:

Next Question

Previous Question | Tag Question

Feedback | End Session

Difficulty: Easy

Peer Responses %

Session Progress

Responses Correct:	0
Responses Incorrect:	29
Responses Total:	29
Responses - % Correct:	0%

© Pastest 2017

A 54-year-old Asian female, who had emigrated from Pakistan 9 months previously, presents to A+E with retrosternal discomfort at the site of her sternotomy wound. She had undergone aortic valve replacement 2 months previously, and subsequently developed a keloid scar. A wound infection at the incision site is diagnosed, and she is admitted by the surgical team for removal of the sternotomy sutures.

At 6 days post-procedure she develops right pleuritic chest pain with a temperature of 38°C, which does not respond to amoxicillin. A CXR is performed which shows a raised right hemidiaphragm and a right hilar mass (also seen on the lateral film).

Two days after starting antibiotic therapy, the patient also develops dorsal back pain for which a CT scan of the thorax and a CT scan of her thoracic spine is performed. The result of the chest CT scan confirms the hilar lymphadenopathy as well as showing a mass within the right psoas muscle. The CT scan of her mid-thoracic spine shows the destruction of the body and the process of T8. She goes onto have a bone scan which identifies several 'hot spots', including over the thoracic spine.

What organism is most likely to be cultured from this abscess?

A	*Escherichia coli*
B	*Mycobacterium tuberculosis*
C	*Streptococcus bovis*
D	*Candida albicans*
E	*Staphylococcus aureus*

6810

Submit

Previous Question | Skip Question

Calculator

Normal Values

© Pastest 2017

A 54-year-old Asian female, who had emigrated from Pakistan 9 months previously, presents to A+E with retrosternal discomfort at the site of her sternotomy wound. She had undergone aortic valve replacement 2 months previously, and subsequently developed a keloid scar. A wound infection at the incision site is diagnosed, and she is admitted by the surgical team for removal of the sternotomy sutures.

At 6 days post-procedure she develops right pleuritic chest pain with a temperature of 38°C, which does not respond to amoxicillin. A CXR is performed which shows a raised right hemidiaphragm and a right hilar mass (also seen on the lateral film).

Two days after starting antibiotic therapy, the patient also develops dorsal back pain for which a CT scan of the thorax and a CT scan of her thoracic spine is performed. The result of the chest CT scan confirms the hilar lymphadenopathy as well as showing a mass within the right psoas muscle. The CT scan of her mid-thoracic spine shows the destruction of the body and the process of T8. She goes onto have a bone scan which identifies several 'hot spots', including over the thoracic spine.

What organism is most likely to be cultured from this abscess?

A	*Escherichia coli*
B	*Mycobacterium tuberculosis*
C	*Streptococcus bovis*
D	*Candida albicans*
E	*Staphylococcus aureus*

Explanation

B	*Mycobacterium tuberculosis*

Pott's disease is also known as tuberculous spondylitis and is one of the oldest diseases to afflict humankind. It is usually secondary to an extra-spinal source of infection, primarily from the lungs or the mediastinal glands through the blood stream. The classical symptoms of tuberculosis of the spine are pain, rigidity, deformity, cold abscess and paraplegia (following vertebral collapse). Although any vertebra may be involved, it is usually the lower thoracic and upper lumbar vertebrae that are affected. Patients also report constitutional symptoms, including fever and weight loss. This patient had tuberculosis of the lung which had spread to her spine. Although upper lobe involvement is most common, tuberculosis can be found in any part of the lung.

A	*Escherichia coli*

This organism is associated with secondary psoas abscess in patients with inflammatory bowel disease or renal sepsis, but would not explain her respiratory or vertebral symptoms.

C	*Streptococcus bovis*

This organism is associated with gastrointestinal malignancy, but would not explain her constellation of respiratory, vertebral and psoas symptoms.

D	*Candida albicans*

Systemic candidial infection is most commonly seen in immunocompromised patients such as those with HIV, and is a less likely diagnosis than TB given the respiratory, vertebral and psoas features seen.

E	*Staphylococcus aureus*

This is the most common cause of primary psoas abscess, and secondary psoas abscess where skeletal infection is the primary cause. In this case, this patient probably has pulmonary TB which has spread to her vertebrae and psoas.

6810

Rate this question:

Next Question

Previous Question | Tag Question

Feedback | End Session

Difficulty: Easy

Peer Responses %

Session Progress

Responses Correct:	0
Responses Incorrect:	30
Responses Total:	30
Responses - % Correct:	0%

© Pastest 2017

A 45-year-old patient presents to his GP with dyspnoea and cough over the past week. He has also noticed recurrent nose bleeds and crusting around his nose over the past month. He is a non-smoker, has no past medical history and is not on any medications.

Spirometry is performed:

Forced expiratory volume in 1 second (FEV_1)	80% predicted
Forced vital capacity (FVC)	65% predicted
Total lung capacity (TLC)	70% predicted
Lung CO transfer factor (T_{LCO})	120% predicted factor
CO transfer coefficient (K_{CO})	120% predicted coefficient

Urine dip: protein ++, blood +

Blood tests show:

Hb	11.2 g/dl
WCC	11.2×10^9/l
PLT	540×10^9/l
MCV	90 fl
eGFR	41

Which is the most likely diagnosis?

A	Pulmonary haemorrhage
B	Pneumonectomy
C	Left-to-right shunt
D	Sarcoidosis
E	Neuromuscular defect

7161

Submit

Previous Question | Skip Question

Calculator

Normal Values

© Pastest 2017

A 45-year-old patient presents to his GP with dyspnoea and cough over the past week. He has also noticed recurrent nose bleeds and crusting around his nose over the past month. He is a non-smoker, has no past medical history and is not on any medications.

Spirometry is performed:

Forced expiratory volume in 1 second (FEV_1)	80% predicted
Forced vital capacity (FVC)	65% predicted
Total lung capacity (TLC)	70% predicted
Lung CO transfer factor (T_{LCO})	120% predicted factor
CO transfer coefficient (K_{CO})	120% predicted coefficient

Urine dip: protein ++, blood +

Blood tests show:

Hb	11.2 g/dl
WCC	11.2 × 10^9/l
PLT	540 × 10^9/l
MCV	90 fl
eGFR	41

Which is the most likely diagnosis?

A Pulmonary haemorrhage

B Pneumonectomy

C Left-to-right shunt

D Sarcoidosis

E Neuromuscular defect

Explanation

A Pulmonary haemorrhage

The spirometry shows a restrictive picture (FEV_1/FVC >80%). This suggests that there is a restrictive cause of the shortness of breath, such as haemorrhage, sarcoidosis, pneumonectomy or reduced work of the respiratory muscles due to a neuromuscular defect. Pulmonary haemorrhage would be a cause of increased K_{CO} and hence is the most likely diagnosis when taken with the history of nose bleeds, making a vasculitis such as granulomatosis with polyangitis (Wegener's) the likely underlying diagnosis. GPA is also associated with collapse of the nasal bridge, leading to a 'saddle nose' deformity.

B Pneumonectomy

This would be expected to result in a reduced transfer factor due to loss of significant volume of alveolar membrane, with normal transfer coefficient assuming the residual lung is normal.

C Left-to-right shunt

While this would cause an increased transfer factor, it does not explain the nose bleeds as adequately as a diagnosis of underlying vasculitis. We are also not given any history of murmurs such as ASD, VSD or PDA on examination, nor features of underlying pulmonary hypertension.

D Sarcoidosis

While this would result in a restrictive pattern of PFTs, we are not given any history of other symptoms such as erythema nodosum, and this does not explain the increased K_{CO} as adequately as pulmonary haemorrhage.

E Neuromuscular defect

While this would result in a restrictive pattern of PFTs, we are not given any other features to suggest a neurological aetiology such as motor or sensory deficit. It also fails to adequately explain the patient's epistaxis.

7161

Rate this question:

Next Question

Previous Question | Tag Question

Feedback | End Session

Difficulty: Average

Peer Responses %

Session Progress

Responses Correct:	0
Responses Incorrect:	31
Responses Total:	31
Responses - % Correct:	0%

© Pastest 2017

A 35-year-old patient presents with a productive cough and shortness of breath on exertion over the past month. He has no personal past medical history, but his father suffered hepatocellular carcinoma at a young age. He is a smoker of 10 pack-years. On examination he has a hyper-expanded chest and bi-basal wheeze on auscultation.

He has spirometry showing the following results:

FEV_1	54% predicted
FVC	82% predicted
Residual volume (RV)	115% predicted
T_{LCO}	68% predicted
K_{CO}	67% predicted

Which of the following diagnoses would best fit the above results?

A	Asthma
B	Emphysema
C	Lymphangitis carcinomatosis
D	Thoracic cage deformity
E	Slowly expanding pneumothorax

7162

Submit

Previous Question | Skip Question

Calculator

Normal Values

© Pastest 2017

A 35-year-old patient presents with a productive cough and shortness of breath on exertion over the past month. He has no personal past medical history, but his father suffered hepatocellular carcinoma at a young age. He is a smoker of 10 pack-years. On examination he has a hyper-expanded chest and bi-basal wheeze on auscultation.

He has spirometry showing the following results:

FEV_1	54% predicted
FVC	82% predicted
Residual volume (RV)	115% predicted
T_{LCO}	68% predicted
K_{CO}	67% predicted

Which of the following diagnoses would best fit the above results?

A	Asthma
B	Emphysema
C	Lymphangitis carcinomatosis
D	Thoracic cage deformity
E	Slowly expanding pneumothorax

Explanation

B Emphysema

The spirometry shows an obstructive picture with raised RV, suggesting air trapping. He also has reduced alveolar function, suggesting a lung parenchymal cause. It is unlikely to be asthma given the short history and poor spirometry; it is more likely to be a rapidly progressive disease such as emphysema in a smoker with α1-antitrypsin. All patients under the age of 35 years presenting with COPD should have their α1-antitrypsin tested. His symptoms do not suggest someone with bad asthma.

A Asthma

The short history and poor spirometry make a rapidly progressive disease such as emphysema in a smoker with α1-antitrypsin deficiency more likely.

C Lymphangitis carcinomatosis

This is lymphangitis as a result of a malignancy, most commonly adenocarcinoma such as breast, lung, stomach or prostate. The patient's young age makes this a less likely diagnosis than emphysema secondary to α1-antitrypsin deficiency. Also, this would be expected to show a restrictive pattern of PFTs, rather than the obstructive picture seen here.

D Thoracic cage deformity

This would be expected to show a restrictive pattern of PFTs, rather than the obstructive picture seen here. The short history also makes this a less likely diagnosis.

E Slowly expanding pneumothorax

This would be expected to show a restrictive pattern of PFTs, rather than the obstructive picture seen here.

7162

Rate this question:

Next Question

Previous Question | Tag Question

Feedback | End Session

Difficulty: Easy

Peer Responses %

Session Progress

Responses Correct:	0
Responses Incorrect:	32
Responses Total:	32
Responses - % Correct:	0%

Blog About Pastest Contact Us Help

© Pastest 2017

A 45-year-old woman complains of shortness of breath, occasional fevers and mild weight loss, all getting worse over the past months. She does not complain of a cough but remembered that she had coughed once and produced a twig-shaped mucoid sputum mass. She has no haemoptysis. She has no past medical history and is on no medications. Her chest X-ray reveals bilateral, perihilar, dense airspace shadowing. She went on to have a HRCT of her thorax, which showed a 'crazy paving' pattern of extensive, dense, white infiltrates. Her spirometry was a restrictive pattern with reduced total lung capacity. She also had a bronchoscopy and lavage, which revealed periodic acid–Schiff (PAS)-positive proteinaceous fluid and elevated levels of surfactant proteins A and D.

What is the most likely diagnosis?

A	Chronic pulmonary eosinophilia
B	Sarcoidosis
C	Extrinsic allergic alveolitis
D	Pulmonary alveolar proteinosis
E	*Pneumocystis jirovecii* infection

7163

Submit

Previous Question | Skip Question

Calculator

Normal Values

© Pastest 2017

A 45-year-old woman complains of shortness of breath, occasional fevers and mild weight loss, all getting worse over the past months. She does not complain of a cough but remembered that she had coughed once and produced a twig-shaped mucoid sputum mass. She has no haemoptysis. She has no past medical history and is on no medications. Her chest X-ray reveals bilateral, perihilar, dense airspace shadowing. She went on to have a HRCT of her thorax, which showed a 'crazy paving' pattern of extensive, dense, white infiltrates. Her spirometry was a restrictive pattern with reduced total lung capacity. She also had a bronchoscopy and lavage, which revealed periodic acid–Schiff (PAS)-positive proteinaceous fluid and elevated levels of surfactant proteins A and D.

What is the most likely diagnosis?

A	Chronic pulmonary eosinophilia
B	Sarcoidosis
C	Extrinsic allergic alveolitis
D	Pulmonary alveolar proteinosis
E	*Pneumocystis jirovecii* infection

Explanation

D	Pulmonary alveolar proteinosis

Pulmonary alveolar proteinosis (PAP) is a rare diffuse lung disease in which the alveolar sacs become filled with protein-rich fluid that characteristically stain sor PAS, a protein derived from surfactant. It usually affects people aged 20–60 years who have no previous lung disease, men more frequently than women. It can be primary or secondary, the latter being related to infections with, for example, *Pneumocystis jirovecii* or atypical mycobacteria, or to immunosuppressants, organic dusts and haematological malignancy. It usually presents with shortness of breath and mild constitutional symptoms. Diagnosis is based on bronchial lavage or biopsy with PAS-positive stains and increased presence of surfactant proteins A and D. HRCT shows a classic picture of dense infiltrates, often referred to as crazy paving. Spirometry shows a restrictive pattern with reduced lung capacity and reduced carbon monoxide diffusion. Most patients do not require treatment unless their shortness of breath is disabling. Treatment is by washing the alveoli out with salt solution. This can be done by bronchoscopy or under general anaesthesia through the trachea. If both lungs need washing then they are done about 5 days apart. The number of washings depends on symptoms. The prognosis is good.

A	Chronic pulmonary eosinophilia

Histology would be expected to show eosinophilic and lymphocytic infiltration of the alveoli and interstitium, with fibrosis. HRCT typically shows non-segmental areas of consolidation, with a peripheral predilection.

B	Sarcoidosis

This is classically associated histologically with the formation of non-caseating granulomas. We are not given any history of cutaneous features such as erythema nodosum. The CT findings also do not fit, with sarcoidosis commonly showing hilar lymphadenopathy and perilymphatic nodule distribution.

C	Extrinsic allergic alveolitis

Hypersensitivity pneumonitis occurs in response to an antigen, such as occurs in, for example, bird fancier's lung, etc. We are not given any history of exposure that would explain this diagnosis, and the CT findings are not in keeping, with a 'ground glass' pattern being more common.

E	*Pneumocystis jirovecii* infection

This is uncommon outwith the context of HIV infection or other cause of immunocompromise.

7163

Rate this question:

Next Question

Previous Question | Tag Question

Feedback | End Session

Difficulty: Difficult

Peer Responses %

Session Progress

Responses Correct:	0
Responses Incorrect:	33
Responses Total:	33
Responses - % Correct:	0%

© Pastest 2017

An HIV-positive patient attends A+E with a history of shortness of breath, fever and a dry cough. On investigation, his CD4 count is 50 cells/mm^3 and his oxygen levels drop after exercise. On further questioning, he admits that he has not been taking his medications recently.

Investigations:

Hb	14.5 g/dl
CD4	50/mm^3
PLT	210 × 10^9/l
pO2 on room air	9.5 kpa

Which of the following is the first-line treatment for this patient?

A	Prednisolone
B	Co-trimoxazole
C	Aciclovir
D	Rifampicin, Isoniazid, Ethambutol and Pyrizinamide quadruple therapy
E	Ganciclovir

7164

Submit

Previous Question | Skip Question

Calculator

Normal Values

Blog About Pastest Contact Us Help

© Pastest 2017

An HIV-positive patient attends A+E with a history of shortness of breath, fever and a dry cough. On investigation, his CD4 count is 50 cells/mm^3 and his oxygen levels drop after exercise. On further questioning, he admits that he has not been taking his medications recently.

Investigations:

Hb	14.5 g/dl
CD4	50/mm^3
PLT	210 × 10^9/l
pO2 on room air	9.5 kpa

Which of the following is the first-line treatment for this patient?

A	Prednisolone
B	Co-trimoxazole
C	Aciclovir
D	Rifampicin, Isoniazid, Ethambutol and Pyrizinamide quadruple therapy
E	Ganciclovir

Explanation

B	Co-trimoxazole

Clinically he is infected with *Pneumocystis jirovecii*, which often presents with a dry cough in HIV-positive patients and other immunosuppressed patients, particularly after organ transplantation and prolonged use of immunosuppressants, and when the CD4 count is very low as here. On examination there is often tachycardia and tachypnoea, and there may be signs of cyanosis; however, the chest may even reveal no abnormality on examination in some patients. The chest X-ray may reveal bilateral hilar infiltrates or even cysts, but the pleura is rarely involved. If there is significant infiltration then crackles will be found on auscultation. Diagnosis is from pulmonary secretions or lung biopsy, looking for organisms using immunofluorescence or methenamine silver staining. The first-line treatment is with co-trimoxazole, but prednisolone can be added if the oxygen level is < 9.3 kPa.

A	Prednisolone

The first-line treatment is with co-trimoxazole but prednisolone can be added as adjuvant therapy.

C	Aciclovir

This is used to treat herpes virus infections. Herpes simplex infection is associated with oral and genital mucous membrane ulceration. It can be associated with headache and neurological symptomatology in the case of simplex encephalitis/meningitis.

D	Rifampicin, Isoniazid, Ethambutol and Pyrizinamide quadruple therapy

This is the treatment for tuberculosis. It is associated with cough, fever, weight loss and night sweats, which are often described as 'drenching' in severity.

E	Ganciclovir

This is the treatment for CMV infections. CMV retinitis, leading to visual symptoms, is the most common manifestation of systemic CMV infection in HIV-positive patients. Other features may include GI upset, or changes in cognition/consciousness in the case of CMV encephalitis.

7164

Rate this question:

Next Question

Previous Question | Tag Question

Feedback | End Session

Difficulty: Difficult

Peer Responses %

Session Progress

Responses Correct:	0
Responses Incorrect:	34
Responses Total:	34
Responses - % Correct:	0%

© Pastest 2017

A 30-year-old woman presents with sudden-onset shortness of breath and chest pain. She had a similar episode earlier in the year. At that time she had a chest X-ray taken and had a needle inserted into her lung, which relieved the problem. Last year she had shortness of breath associated with 'fluid on her lung', which was drained off, and she was told to eat a low-fat diet. She has no other past medical history and is not on any medications.

What is the most likely diagnosis?

A	Histiocytosis
B	Tuberous sclerosis
C	Neurofibromatosis type 1
D	Recurrent Pneumocystis jirovecii infection
E	Lymphangioleiomyomatosis

7165

Submit

Previous Question | Skip Question

Calculator

Normal Values

© Pastest 2017

A 30-year-old woman presents with sudden-onset shortness of breath and chest pain. She had a similar episode earlier in the year. At that time she had a chest X-ray taken and had a needle inserted into her lung, which relieved the problem. Last year she had shortness of breath associated with 'fluid on her lung', which was drained off, and she was told to eat a low-fat diet. She has no other past medical history and is not on any medications.

What is the most likely diagnosis?

A	Histiocytosis
B	Tuberous sclerosis
C	Neurofibromatosis type 1
D	Recurrent Pneumocystis jirovecii infection
E	Lymphangioleiomyomatosis

Explanation

Lymphangioleiomyomatosis is a rare idiopathic disease, affecting women of reproductive years. It is characterised by infiltration of immature muscle cells into the bronchiolar and alveolar walls. This results in destruction of the airways, cyst formation and progressive decline in lung function. Typical radiological findings are of interstitial lung disease, recurrent pneumothoraces and chylous effusions. Treatment is lung transplantation. Patients are asked to avoid taking the oral contraceptive pill, pregnancy and long-haul flights. Conservative management includes progesterone supplements but the response is variable. Management of pneumothorax and chylous effusions is standard. If this occurs in men then tuberous sclerosis should be considered.

7165

Rate this question:

Next Question

Previous Question | Tag Question

Feedback | End Session

Difficulty: Difficult

Peer Responses %

Session Progress

Responses Correct:	0
Responses Incorrect:	35
Responses Total:	35
Responses - % Correct:	0%

© Pastest 2017

A 59-year-old male with a 20 pack-year smoking history presents to A&E with sudden-onset shortness of breath. He is an office worker and does not frequently undertake physical activity. On examination he is tachypnoeic and tachycardic, with a systolic BP of 110 mmHg. He has a past medical history of type 2 diabetes and hypertension, and has recently resumed work following an MI 9 weeks ago, which was complicated by a radial dissection requiring blood transfusion.

Which of the following is his strongest risk factor for PE?

A	Diabetes
B	Obesity
C	Age
D	Blood transfusion
E	Previous MI

7170

Previous Question | Skip Question

Calculator

Normal Values

Blog About Pastest Contact Us Help

© Pastest 2017

A 59-year-old male with a 20 pack-year smoking history presents to A&E with sudden-onset shortness of breath. He is an office worker and does not frequently undertake physical activity. On examination he is tachypnoeic and tachycardic, with a systolic BP of 110 mmHg. He has a past medical history of type 2 diabetes and hypertension, and has recently resumed work following an MI 9 weeks ago, which was complicated by a radial dissection requiring blood transfusion.

Which of the following is his strongest risk factor for PE?

A	Diabetes
B	Obesity
C	Age
D	Blood transfusion
E	Previous MI

Explanation

E	Previous MI

The risk factors for pulmonary embolism broadly correlate with those for DVT, and are related to Virchow's triad for thrombus formation: haemodynamic abnormality such as stasis or turbulent flow; endothelial dysfunction/damage; and hypercoagulability due to the constituents of the blood, e.g. antiphospholipid syndrome, etc. The Geneva and Wells Scores, used to estimate likelihood of PE based on history and examination, take into account a number of these risk factors such as advanced age, previous PE/DVT, surgery or lower limb fracture in the previous month, active malignancy and immobility. MI within 3 months is the only one of the given options classified as a strong risk factor (odds radio >10).

A	Diabetes

This is a weak risk factor, with odds ratio <2. There is a greater prevalence of hospitalisation, obesity and other pro-inflammatory conditions such as rheumatoid arthritis in the diabetic population, all of which serve to increase thrombotic risk, but it is not the *strongest* risk factor mentioned here.

B	Obesity

This is a weak risk factor, with odds ratio <2. Obesity increases intra-abdominal pressure and increases the risk of other conditions such as diabetes and hypertension.

C	Age

Age >65 is considered a risk factor, but is a weak risk factor with odds ratio <2. The same risk factors such as smoking, immobility and genetic predisposition remain in the elderly, with the addition of increased prevalence of risk factors such as malignancy, co-morbidity and immobility, and age-specific risk factors such as decreased efficiency of the calf muscle and increased endothelial dysfunction.

D	Blood transfusion

This is a moderate risk factor, with odds ratio 2–9. Blood transfusion alters the composition of clotting factors in the blood and has the potential to provoke an inflammatory response, both of which are pro-thrombotic actions.

All the clinical histories described in stems A to D would be associated with medium to high risk of pulmonary embolus. Stem E is least suggestive of underlying pulmonary embolic disease. Negative D-dimer testing may be helpful in discounting pulmonary embolus where the clinical history is not suggestive of the condition.

7170

Rate this question:

Next Question

Previous Question | Tag Question

Feedback | End Session

Difficulty: Easy

Peer Responses %

Session Progress

Responses Correct:	0
Responses Incorrect:	36
Responses Total:	36
Responses - % Correct:	0%

© Pastest 2017

An HIV-positive patient is admitted acutely unwell with shortness of breath initially only on exertion, but now present even at rest. He has been prescribed HAART and pentamidine (the first-line agent being unsuitable for him). However, recently he says that he has not had time to come to the clinic for treatment. His chest X-ray shows bilateral air-space shadowing and his arterial blood gas on air shows pO_2 7.9 kPa and pCO_2 5.0 kPa.

What is the most appropriate initial treatment option?

A	Intravenous co-trimoxazole
B	Nebulised pentamidine
C	Intravenous Pentamidine with prednisolone
D	Intravenous cefotaxime and oral clarithromycin
E	IV hydrocortisone

7171

Submit

Previous Question | Skip Question

Calculator

Normal Values

© Pastest 2017

An HIV-positive patient is admitted acutely unwell with shortness of breath initially only on exertion, but now present even at rest. He has been prescribed HAART and pentamidine (the first-line agent being unsuitable for him). However, recently he says that he has not had time to come to the clinic for treatment. His chest X-ray shows bilateral air-space shadowing and his arterial blood gas on air shows pO_2 7.9 kPa and pCO_2 5.0 kPa.

What is the most appropriate initial treatment option?

A	Intravenous co-trimoxazole
B	Nebulised pentamidine
C	Intravenous Pentamidine with prednisolone
D	Intravenous cefotaxime and oral clarithromycin
E	IV hydrocortisone

Explanation

C Intravenous Pentamidine with prednisolone

The patient has an intolerance to co-trimoxazole and has a CD4 count less than 200, so needs pentamidine nebulisers as PCP prophylaxis. If he has not been having these, he is at risk of pneumocystis pneumonia (PCP), which must be treated even before definitive histology can be obtained. The ideal treatment for him is as for severe PCP with respect to antimicrobial therapy, as his pO_2 is below 9.3 kPa. He needs intravenous treatment, of which Pentamidine is second choice after septrin, with oral or intravenous steroids as his pO_2 is below the 9.3 kPa threshold.

A Intravenous co-trimoxazole

This patient is taking pentamidine as co-trimoxazole is unsuitable for him. It would be inappropriate to offer IV co-trimoxazole.

B Nebulised pentamidine

This is an appropriate prophylactic treatment, but is not the best management choice for this patient's acute presentation.

D Intravenous cefotaxime and oral clarithromycin

This antibiotic combination therapy would be suitable if a bacterial aetiology were suspected for his presentation, and may well be appropriate as additional therapy until microbiological confirmation of the organism can be obtained, but the more likely diagnosis of PCP would make this inappropriate as sole therapy.

E IV hydrocortisone

While corticosteroids are an important adjuvant therapy, they are inadequate as monotherapy in the treatment of PCP.

7171

Rate this question:

Next Question

Previous Question | Tag Question

Feedback | End Session

Difficulty: Difficult

Peer Responses %

Session Progress

Responses Correct:	0
Responses Incorrect:	37
Responses Total:	37
Responses - % Correct:	0%

© Pastest 2017

A 54 year old male with a history of alcohol excess presents to A+E with cough, dyspnoea and drenching night sweats. Following investigation, the diagnosis of TB is confirmed, and he is commenced on directly obserbed quadruple anti-TB combination treatment. Prior to beginning treatment, he attends the clinic for discussion of the therapy and potential side effects to be aware of.

Which of the following listed options is a possible side effect of anti-tuberculous therapy?

A	Hepatic obstruction
B	Haematuria
C	Vitamin A deficiency
D	Cortical visual loss
E	Peripheral neuropathy

7172

Submit

Previous Question | Skip Question

Calculator

Normal Values

Blog About Pastest Contact Us Help

© Pastest 2017

A 54 year old male with a history of alcohol excess presents to A+E with cough, dyspnoea and drenching night sweats. Following investigation, the diagnosis of TB is confirmed, and he is commenced on directly obserbed quadruple anti-TB combination treatment. Prior to beginning treatment, he attends the clinic for discussion of the therapy and potential side effects to be aware of.

Which of the following listed options is a possible side effect of anti-tuberculous therapy?

A	Hepatic obstruction
B	Haematuria
C	Vitamin A deficiency
D	Cortical visual loss
E	Peripheral neuropathy

Explanation

E	Peripheral neuropathy

soniazid can cause a peripheral neuropathy, particularly if used in patients with malnourishment, HIV or alcoholism, or other patients at risk of peripheral neuropathy.

Among of the main side effects to be aware of with anti-TB therapy are: peripheral neuropathy with isoniazid; orange-red staining of secretions with rifampicin; and optic neuritis with ethambutol. Rifampicin, isoniazid and pyrazinamide are all associated with GI upset and hepatitis.

A	Hepatic obstruction

Anti-TB therapy is more commonly associated with drug-related hepatitis than obstruction.

B	Haematuria

Rifampicin is known to cause orange-red discoloration of secretions such as urine, sweat and tears, but is not associated with haematuria.

C	Vitamin A deficiency

Rifampicin and isoniazid can cause a relative vitamin D deficiency, probably already present in the patient but unmasked by the anti-TB therapy, but anti-TB therapy is not associated with vitamin A deficiency.

D	Cortical visual loss

Rifampicin causes an orange discolouration of the urine.. Ethambutol tends to cause colour blindness, restriction of visual fields and loss of visual acuity because of optic neuropathy, but not cortical blindness.

7172

Rate this question:

Next Question

Previous Question | Tag Question

Feedback | End Session

Difficulty: Average

Peer Responses %

Session Progress

Responses Correct:	0
Responses Incorrect:	38
Responses Total:	38
Responses - % Correct:	0%

© Pastest 2017

A 57-year-old male patient with a 40 pack-year smoking history attends his GP with incessant daytime sleepiness, making it difficult for him to even attend work. His initial examination reveals a height of 180 cm, weight of 120 kg and neck circumference of 44 cm. He is referred for sleep studies, which show hypnoea/apnoea episodes consistent with the diagnosis of moderate to severe obstructive sleep apnoea (OSA).

Which of the following is the most appropriate treatment option?

A	Overnight continuous positive airways pressure (CPAP)
B	Amitriptyline
C	Long-term oxygen therapy
D	Nocturnal lorazepam
E	Intra-oral device to prevent snoring

7174

Submit

Previous Question | Skip Question

Calculator

Normal Values

© Pastest 2017

A 57-year-old male patient with a 40 pack-year smoking history attends his GP with incessant daytime sleepiness, making it difficult for him to even attend work. His initial examination reveals a height of 180 cm, weight of 120 kg and neck circumference of 44 cm. He is referred for sleep studies, which show hypnoea/apnoea episodes consistent with the diagnosis of moderate to severe obstructive sleep apnoea (OSA).

Which of the following is the most appropriate treatment option?

A	Overnight continuous positive airways pressure (CPAP)
B	Amitriptyline
C	Long-term oxygen therapy
D	Nocturnal lorazepam
E	Intra-oral device to prevent snoring

Explanation

A	Overnight continuous positive airways pressure (CPAP)

The treatment of choice has been shown in studies to be effective in reducing OSA symptoms, and is first line in moderate–severe disease requiring intervention, but does not prevent the cardiovascular mortality associated with OSA. Hypnotics worsen OSA, as do alcohol, smoking and obesity, and so patients should alter their lifestyle appropriately, with weight loss and alcohol and smoking cessation as first-line treatment. Long-term oxygen therapy has not been shown to have any long-term benefit in OSA patients. Modafinil has been shown in some small studies to have beneficial effects in use with CPAP, but not as an alternative. Intra-oral devices may be useful for mild OSA, but not in daytime sleepiness.

B	Amitriptyline

This is an inappropriate treatment option, as hypnotics can worsen OSA.

C	Long-term oxygen therapy

This can be used as an adjunct to CPAP therapy or in cases where patients are unable to adhere to CPAP, but should not be offered first line in preference to CPAP.

D	Nocturnal lorazepam

This is an inappropriate treatment option, as hypnotics can worsen OSA.

E	Intra-oral device to prevent snoring

This may be useful for patients with mild OSA, but this patient has presented with daytime sleepiness and studies consistent with moderate–severe disease.

7174

Rate this question:

Next Question

Previous Question	Tag Question
Feedback	End Session

Difficulty: Average

Peer Responses %

Session Progress

Responses Correct:	0
Responses Incorrect:	39
Responses Total:	39
Responses - % Correct:	0%

© Pastest 2017

A 70-year-old female smoker presents with a 3-day history of loss of sensation of both her lower legs. She also reports a 1-stone (6.53 kg) weight loss and unresolving cough over the last month. Her chest X-ray shows a large hilar mass, not seen on a chest X-ray from 2 months ago. She has no other past medical history and is not on any medication. On examination she has loss of light touch and pain sensation in a stocking distribution, reduced air entry in her right chest, palpable supraclavicular lymph node and a large craggy liver edge.

Investigations:

WCC	6.2 × 10^9/l (4–11 × 10^9/l)
Neutrophils	11.6 g/dl (11.5–16.0 g/dl)
Hb	11.6 g/dl (11.5–16.0 g/dl)
PLT	347 × 10^9/l (150–400 × 10^9/l)

Which of the following is the most likely diagnosis?

A	Small-cell carcinoma
B	Non-Hodgkin's lymphoma
C	Adenocarcinoma
D	Sarcoid
E	Squamous cell carcinoma

7175

Submit

Previous Question | Skip Question

Calculator

Normal Values

© Pastest 2017

A 70-year-old female smoker presents with a 3-day history of loss of sensation of both her lower legs. She also reports a 1-stone (6.53 kg) weight loss and unresolving cough over the last month. Her chest X-ray shows a large hilar mass, not seen on a chest X-ray from 2 months ago. She has no other past medical history and is not on any medication. On examination she has loss of light touch and pain sensation in a stocking distribution, reduced air entry in her right chest, palpable supraclavicular lymph node and a large craggy liver edge.

Investigations:

WCC	6.2 × 10^9/l (4–11 × 10^9/l)
Neutrophils	11.6 g/dl (11.5–16.0 g/dl)
Hb	11.6 g/dl (11.5–16.0 g/dl)
PLT	347 × 10^9/l (150–400 × 10^9/l)

Which of the following is the most likely diagnosis?

A	Small-cell carcinoma
B	Non-Hodgkin's lymphoma
C	Adenocarcinoma
D	Sarcoid
E	Squamous cell carcinoma

Explanation

A Small-cell carcinoma

Given the rapid progression and spread of her pathology and the probable paraneoplastic peripheral neuropathy, this is the most likely diagnosis. Small cell carcinoma accounts for 20% of all lung cancers (National Cancer Intelligence Network, 2012), and it is the morphological subtype of lung cancer most closely associated with smoking. Small cell carcinoma often presents with unilateral hilar enlargement, a perihilar or a mediastinal mass. Less commonly, it may present with a central lesion, often cavitating, and given its rapid growth, with satellite lesions elsewhere in the thorax, characteristically with extensive, bulky mediastinal lymphadenopathy.

B Non-Hodgkin's lymphoma

The rapid spread of disease in this patient would be associated with an abnormal full blood count in non-Hodgkin's lymphoma.

C Adenocarcinoma

Though the most common type of non-small-cell lung cancer, it is usually slow growing. It typically presents as a peripheral mass lesion, or less commonly as an area of segemental ground-glass attenuation.

D Sarcoid

The history of smoking and rapid progression of pathology are suggestive of a malignant process. Sarcoid could cause the neurology seen, but would cause a smooth, enlarged granulomatous liver and widespread generalised lymphadenopathy rather than the craggy liver edge and isolated palpable supraclavicular lymph node noted.

E Squamous cell carcinoma

Like adenocarcinoma, squamous cell carcinoma is much slower growing. It typically presents as a central lesion on chest X-ray, with or without lung collapse due to intraluminal obstruction.

7175

Rate this question:

Next Question

Previous Question | Tag Question

Feedback | End Session

Difficulty: Average

Peer Responses %

Session Progress

Responses Correct:	0
Responses Incorrect:	40
Responses Total:	40
Responses - % Correct:	0%

© Pastest 2017

You are seeing a patient in clinic. Unfortunately all clinic notes in the cardiorespiratory test department, are being audited; however the patient brings along a copy of her lung function results. Her date of birth is missing from the report.

Lung function results:

FEV_1	0.35 (1.2–2.9 predicted)
Total lung capacity	6.8 (4.4–6.8 predicted)
Corrected transfer factor	3.4 (4.2–8.8 predicted)

From these results, which disease do you suspect that she is most likely to have?

A	Severe chronic obstructive pulmonary disease (COPD)
B	Severe asthma
C	Moderate COPD
D	Non-specific interstitial pneumonitis (NSIP)
E	Sarcoidosis

7176

Submit

Previous Question | Skip Question

Calculator

Normal Values

© Pastest 2017

You are seeing a patient in clinic. Unfortunately all clinic notes in the cardiorespiratory test department, are being audited; however the patient brings along a copy of her lung function results. Her date of birth is missing from the report.

Lung function results:

FEV_1	0.35 (1.2–2.9 predicted)
Total lung capacity	6.8 (4.4–6.8 predicted)
Corrected transfer factor	3.4 (4.2–8.8 predicted)

From these results, which disease do you suspect that she is most likely to have?

A	Severe chronic obstructive pulmonary disease (COPD)
B	Severe asthma
C	Moderate COPD
D	Non-specific interstitial pneumonitis (NSIP)
E	Sarcoidosis

Explanation

A	Severe chronic obstructive pulmonary disease (COPD)

COPD is defined as a reduced FEV_1/FVC ratio (where FEV_1 is forced expired volume in 1 second and FVC is forced vital capacity), such that FEV_1/FVC is less than 0.7. Though you are not given an FVC reading, note that the total lung capacity here is within the normal range, yet the FEV_1 is significantly reduced, this fits best with a diagnosis of COPD.

B	Severe asthma

Asthma is associated with a normal or raised transfer factor.

C	Moderate COPD

Predicted FEV_1 in moderate COPD is 50–79%. See table below for classification of COPD.

FEV_1 % predicted	Severity of airflow obstruction
>80%	**
50–79%	Mild
30–49%	Moderate
<30%	Severe

**If FEV_1 is ⩾80% predicted normal, a diagnosis of COPD should only be made in the presence of respiratory symptoms, for example breathlessness or cough.

D	Non-specific interstitial pneumonitis (NSIP)

Restrictive lung disease is associated with a decreased total lung capacity.

E	Sarcoidosis

Like NSIP, sarcoidosis falls under the category of restrictive lung disease, and is associated with a decreased total lung capacity.

7176

Rate this question:

Next Question

Previous Question | Tag Question

Feedback | End Session

Difficulty: Average

Peer Responses %

Session Progress

Responses Correct:	0
Responses Incorrect:	41
Responses Total:	41
Responses - % Correct:	0%

© Pastest 2017

An overweight 55-year-old man complains of daytime sleepiness so much so that he is at risk of losing his job. He also notes morning headaches, and his wife complains that his snoring is getting worse. He is a heavy smoker and drinks about 10 pints a night. His exercise tolerance is only about 500 metres before he feels too short of breath to continue. On examination his BMI is 38.

His arterial blood gas at 10 pm reads:

PaO_2	9.3 kPa
$PaCO_2$	6.2 kPa

A repeat arterial blood gas the following morning reads:

PaO_2	9.8 kPa
$PaCO_2$	8.4 kPa

Which of the following is the most likely diagnosis?

A	Obesity hypoventilation syndrome
B	Central sleep apnoea
C	Chronic obstructive pulmonary disease (COPD)
D	Chronic thromboembolic pulmonary hypertension (CTPH)
E	Motor neurone disease (MND)

7177

Submit

Previous Question | Skip Question

Calculator

Normal Values

© Pastest 2017

An overweight 55-year-old man complains of daytime sleepiness so much so that he is at risk of losing his job. He also notes morning headaches, and his wife complains that his snoring is getting worse. He is a heavy smoker and drinks about 10 pints a night. His exercise tolerance is only about 500 metres before he feels too short of breath to continue. On examination his BMI is 38.

His arterial blood gas at 10 pm reads:

PaO_2	9.3 kPa
$PaCO_2$	6.2 kPa

A repeat arterial blood gas the following morning reads:

PaO_2	9.8 kPa
$PaCO_2$	8.4 kPa

Which of the following is the most likely diagnosis?

A	Obesity hypoventilation syndrome
B	Central sleep apnoea
C	Chronic obstructive pulmonary disease (COPD)
D	Chronic thromboembolic pulmonary hypertension (CTPH)
E	Motor neurone disease (MND)

Explanation

The rise in carbon dioxide in the morning is most likely to be seen in apnoea due to a peripheral cause. Patients with COPD can retain slightly more carbon dioxide in the morning but this does not cause such a profound rise, nor the symptoms of sleep apnoea. If the patient had MND such that it was affecting his diaphragm overnight to cause carbon dioxide retention, you would expect the disease to have presented itself neurologically as well, but the patient is able to walk. CTPH presents itself initially with exertional breathlessness. Where peripheral sleep apnoea is the cause, as here, there are usually pointers to the diagnosis such as obesity. Where central sleep apnoea is the cause there may be pointers to an underlying neurological condition.

7177

Rate this question:

Next Question

Previous Question | Tag Question

Feedback | End Session

Difficulty: Average

Peer Responses %

Session Progress

Responses Correct:	0
Responses Incorrect:	42
Responses Total:	42
Responses - % Correct:	0%

© Pastest 2017

A young alcoholic patient presents with a fever, haemoptysis, green sputum and a left-sided effusion clinically. He has been unwell with swinging fevers for the last week. On further questioning he admits to drinking 8 pints of beer per day and to not eating properly. You are concerned that it may be an empyema.

Which of the following tests would be most useful in supporting your suspicion?

A	Pleural fluid microscopy and culture
B	Pleural fluid white cell count and differential
C	Urinary pneumococcal antigen
D	Serum pneumococcal antigen
E	Pleural fluid pH

7178

Submit

Previous Question | Skip Question

Calculator

Normal Values

© Pastest 2017

A young alcoholic patient presents with a fever, haemoptysis, green sputum and a left-sided effusion clinically. He has been unwell with swinging fevers for the last week. On further questioning he admits to drinking 8 pints of beer per day and to not eating properly. You are concerned that it may be an empyema.

Which of the following tests would be most useful in supporting your suspicion?

A	Pleural fluid microscopy and culture
B	Pleural fluid white cell count and differential
C	Urinary pneumococcal antigen
D	Serum pneumococcal antigen
E	Pleural fluid pH

Explanation

E	Pleural fluid pH

A pleural fluid pH of less than 7.2 is highly suggestive of an empyema.

A	Pleural fluid microscopy and culture

While indispensible if positive in order to tailor antimicrobial therapy, only 60% of pleural fluid cultures are positive.

B	Pleural fluid white cell count and differential

Pleural fluid white cell count and differential are not routinely tested. A raised WCC (>10) is seen in empyema, and more rarely in other exudative effusions.

C	Urinary pneumococcal antigen

While a urine pneumococcal antigen result would be of diagnostic help, neither a positive nor a negative result would confirm the presence of empyema.

D	Serum pneumococcal antigen

As with a urinary pneumococcal antigen test, though a serum pneumococcal antigen result would be of diagnostic help, neither a positive nor a negative result would confirm the presence of empyema. Given the patient's history of alcohol excess, the likelihood of a *Klebsiella* pneumonia, a common cause of empyema, is high, rather than a pneumococcal pneumonia.

7178

Rate this question:

Next Question

Previous Question | Tag Question

Feedback | End Session

Difficulty: Difficult

Peer Responses %

Session Progress

Responses Correct:	0
Responses Incorrect:	43
Responses Total:	43
Responses - % Correct:	0%

© Pastest 2017

You are seeing a patient on the surgical wards as a medical referral. He has had a lymph node dissected from his neck for possible recurrent head and neck cancer. On his postoperative chest X-ray, he has a moderate pleural effusion, which on aspiration drains white, milky fluid.

What is the likely diagnosis of the cause of the effusion?

A	Empyema
B	Mesothelioma
C	Chylous effusion
D	Reactive effusion
E	Malignant effusion

7179

Submit

Previous Question | Skip Question

Calculator

Normal Values

© Pastest 2017

You are seeing a patient on the surgical wards as a medical referral. He has had a lymph node dissected from his neck for possible recurrent head and neck cancer. On his postoperative chest X-ray, he has a moderate pleural effusion, which on aspiration drains white, milky fluid.

What is the likely diagnosis of the cause of the effusion?

A	Empyema
B	Mesothelioma
C	Chylous effusion
D	Reactive effusion
E	Malignant effusion

Explanation

C	Chylous effusion

A chylous effusion is suggested by the white milky fluid aspirated on thoracocentesis. Cardiothoracic and head or neck surgery, including excision of cervical lymph nodes, can result in damage to the thoracic duct resulting in a chylothorax. To confirm the diagnosis, test for pleural fluid triglycerides and cholesterol levels.

A	Empyema

Aspiration of frankly purulent fluid would indicate an empyema.

B	Mesothelioma

Though mesothelioma can present with a pleural effusion alone, the history in this case is not suggestive of this diagnosis.

D	Reactive effusion

You would not aspirate white, milky fluid in a reactive effusion. The fluid may be cloudy or even slightly clear. Reactive effusions are principally lymphocytic infiltrates secondary to the movement of interstitial fluid. The underlying aetiology is varied, and includes congestive heart failure and collagen vascular disease.

E	Malignant effusion

Malignant effusions can present as either serous or serosanginous fluid.

7179

Rate this question:

Next Question

Previous Question | Tag Question

Feedback | End Session

Difficulty: Average

Peer Responses %

Session Progress

Responses Correct:	0
Responses Incorrect:	44
Responses Total:	44
Responses - % Correct:	0%

© Pastest 2017

A 51-year-old man, while an inpatient for a routine hernia operation, was noted to have a pneumothorax on his pre-op chest X-ray. He has a history of chronic bronchitis, and a 50 pack-year smoking history. His chest X-ray is shows a unilateral pneumothorax of 2.2 cm. He is not breathless, but has chest pain.

Which of the following would be the ideal management for the clinical scenario described?

A	You decide to aspirate the pneumothorax with a 16G cannula
B	You decide to insert a 14 French gauge chest drain
C	You decide to give the patient 10 litres of oxygen by mask
D	You decide to admit the patient for observation only
E	You decide to discharge the patient to outpatient ambulatory clinic in 2 weeks

7181

Submit

Previous Question | Skip Question

Calculator

Normal Values

© Pastest 2017

A 51-year-old man, while an inpatient for a routine hernia operation, was noted to have a pneumothorax on his pre-op chest X-ray. He has a history of chronic bronchitis, and a 50 pack-year smoking history. His chest X-ray is shows a unilateral pneumothorax of 2.2 cm. He is not breathless, but has chest pain.

Which of the following would be the ideal management for the clinical scenario described?

A	You decide to aspirate the pneumothorax with a 16G cannula
B	You decide to insert a 14 French gauge chest drain
C	You decide to give the patient 10 litres of oxygen by mask
D	You decide to admit the patient for observation only
E	You decide to discharge the patient to outpatient ambulatory clinic in 2 weeks

Explanation

B	You decide to insert a 14 French gauge chest drain

This patient has a secondary pneumothorax as he is over the age of 50 and has a significant smoking history. The British Thoracic Guidelines suggest you should insert a chest drain 8-14Fr if the pneumothorax is greater than 2 cm in size or the patient is breathless. The intrapleural distance should be measured at the level of the hilum.

A	You decide to aspirate the pneumothorax with a 16G cannula

An attempt at aspirating a secondary pneumothorax should only be made where the pneumothorax is between 1 and 2 cm, and the patient is not breathless.

C	You decide to give the patient 10 litres of oxygen by mask

High-flow oxygen may be used as a treatment option for secondary pneumothoraces less than 1 cm in size, provided you do not suspect the patient is at risk of oxygen sensitivity.

D	You decide to admit the patient for observation only

Admission without intervention can be considered for patients with secondary pneumothoraces where the pneumothorax less than 1 cm in size, and the patient asymptomatic (not breathless).

E	You decide to discharge the patient to outpatient ambulatory clinic in 2 weeks

Admission without intervention can be considered for patients with secondary pneumothoraces where the pneumothorax less than 1 cm in size, and the patient asymptomatic (not breathless).

7181

Rate this question:

Next Question

Previous Question | Tag Question

Feedback | End Session

Difficulty: Difficult

Peer Responses %

Session Progress

Responses Correct:	0
Responses Incorrect:	45
Responses Total:	45
Responses - % Correct:	0%

© Pastest 2017

A 27-year-old known asthmatic patient is brought into the Emergency Department by the ambulance crew after an acute severe attack of asthma. On arrival, he is cyanosed, his respiratory rate is 9 breaths/min and his heart rate is 48 bpm. You immediately start him on high-flow oxygen (non-rebreather mask). While assessing him, the patient suddenly develops respiratory arrest. The patient still has radial pulse of 50 bpm and you start intubating him. While trying to intubate him, he starts to actively vomit a little.

What would be the immediate next appropriate step?

A	Tell your colleague to apply firm cricoid pressure
B	Tell your colleague to release the cricoid and perform suctioning
C	Go ahead and intubate quickly
D	Call the anaesthetist
E	Turn the patient over

7503

Submit

Previous Question Skip Question

Calculator

Normal Values

Blog About Pastest Contact Us Help

© Pastest 2017

A 27-year-old known asthmatic patient is brought into the Emergency Department by the ambulance crew after an acute severe attack of asthma. On arrival, he is cyanosed, his respiratory rate is 9 breaths/min and his heart rate is 48 bpm. You immediately start him on high-flow oxygen (non-rebreather mask). While assessing him, the patient suddenly develops respiratory arrest. The patient still has radial pulse of 50 bpm and you start intubating him. While trying to intubate him, he starts to actively vomit a little.

What would be the immediate next appropriate step?

A	Tell your colleague to apply firm cricoid pressure
B	Tell your colleague to release the cricoid and perform suctioning
C	Go ahead and intubate quickly
D	Call the anaesthetist
E	Turn the patient over

Explanation

B	Tell your colleague to release the cricoid and perform suctioning

During emergency intubation, to minimise the risk of gastric aspiration, the Sellick manoeuvre (firm pressure over the cricoid cartilage) may be initiated as soon as positive pressure ventilation is started and should normally be continued until inflation of the tracheal cuff of the endotracheal tube in the trachea. However active vomiting, which creates oesophageal pressures greater than 60 cmH_2O, is a contraindication to using this technique. In this case, the appropriate action is therefore to release the cricoid and suction.

A	Tell your colleague to apply firm cricoid pressure

Active vomiting, which creates oesophageal pressures greater than 60 cm H_2O is a contraindication to using the Sellick manoeuvre. Applying firm cricoid pressure in this case can result in the rupture of the oesophagus.

C	Go ahead and intubate quickly

The priority in this case is to minimise the risk of gastric aspiration, followed by return to pre-oxygenation with 100% oxygen.

D	Call the anaesthetist

Though senior specialist support should be sought, initial measures must be undertaken to stabilise, and prevent further deterioration of the patient.

E	Turn the patient over

In the context of a respiratory arrest, the risk of gastric aspiration is best minimised by suctioning aspirates rather than repositioning the patient.

7503

Rate this question:

Next Question

Previous Question | Tag Question

Feedback | End Session

Difficulty: Average

Peer Responses %

Session Progress

Responses Correct:	0
Responses Incorrect:	46
Responses Total:	46
Responses - % Correct:	0%

© Pastest 2017

A 56-year-old lady comes into the Emergency Department with palpitations and shortness of breath. She is known to have mild chronic obstructive pulmonary disease (COPD) and is on the following inhalers: salbutamol, ipratropium bromide and beclomethasone, according to her notes she does have a mild degree of reversibility. On examination, the patient is dyspnoeic with a blood pressure is 154/88 mmHg and pulse rate of > 100/min (AF). She underwent echocardiography 6 months ago that showed normal ventricular function and no structural abnormality.

Her admission arterial blood gases (ABG) are:

pH	7.32
$p_a(O_2)$	8.1 kPa
$p_a(CO_2)$	6.2 kPa
Bicarbonate	28 mmol/l

You start the patient on 28% oxygen, nebulisers (salbutamol 5 mg and ipratropium 0.5 mg) and repeat the blood gases after 30 minutes:

pH	7.36
$p_a(O_2)$	9.6 kPa
$p_a(CO_2)$	5.8 kPa
Bicarbonate	29 mmol/l

You reassure her that she is improving on the current medication but she tells you that she is still having palpitations. You do a 12-lead electrocardiogram (ECG), which reveals multi-focal atrial tachycardia (MAT) with a rate of 118/min. Her BP has fallen to 110/70 mmHg.

How would you control this arrhythmia?

A	DC – cardioversion
B	Start her on metoprolol
C	Start her on verapamil
D	Increase inspired oxygen to 40%
E	Just observe her

7504

Submit

Previous Question | Skip Question

Calculator

Normal Values

© Pastest 2017

A 56-year-old lady comes into the Emergency Department with palpitations and shortness of breath. She is known to have mild chronic obstructive pulmonary disease (COPD) and is on the following inhalers: salbutamol, ipratropium bromide and beclomethasone, according to her notes she does have a mild degree of reversibility. On examination, the patient is dyspnoeic with a blood pressure is 154/88 mmHg and pulse rate of > 100/min (AF). She underwent echocardiography 6 months ago that showed normal ventricular function and no structural abnormality.

Her admission arterial blood gases (ABG) are:

pH	7.32
$p_a(O_2)$	8.1 kPa
$p_a(CO_2)$	6.2 kPa
Bicarbonate	28 mmol/l

You start the patient on 28% oxygen, nebulisers (salbutamol 5 mg and ipratropium 0.5 mg) and repeat the blood gases after 30 minutes:

pH	7.36
$p_a(O_2)$	9.6 kPa
$p_a(CO_2)$	5.8 kPa
Bicarbonate	29 mmol/l

You reassure her that she is improving on the current medication but she tells you that she is still having palpitations. You do a 12-lead electrocardiogram (ECG), which reveals multi-focal atrial tachycardia (MAT) with a rate of 118/min. Her BP has fallen to 110/70 mmHg.

How would you control this arrhythmia?

A	DC – cardioversion
B	Start her on metoprolol
C	Start her on verapamil
D	Increase inspired oxygen to 40%
E	Just observe her

Explanation

MAT commonly occurs in critically ill patients with obstructive airways disease who may be hypoxic and hypercapnic. It is characterised by at least three different P-wave morphologies with varying PP and PR intervals. Aim to improve the $p_a(O_2)$ and $p_a(CO_2)$.

Whilst AF control may not be required as her pulmonary status improves, it is likely that in the acute phase, especially with repeated salbutamol nebulisers that she wil suffer from worsening symptoms of tachycardia. As such verapamil would be an appropriate option. It can be given in small boluses of 5mg intravenously and then as an oral dose of 40-120mg TDS. It is a moot point whether she will require long term AF control, if post the acute episode she remains in sinus rhythm, a 72hr ECG monitor may be appropriate prior to commiting her to new medication.

7504

Rate this question:

Next Question

Previous Question | Tag Question

Feedback | End Session

Difficulty: Average

Peer Responses %

Session Progress

Responses Correct:	0
Responses Incorrect:	47
Responses Total:	47
Responses - % Correct:	0%

© Pastest 2017

A patient comes to the Emergency Department with difficulty in breathing which started the previous night. He has difficult giving history, as his lower jaw is painful when he tries to talk. On examination, he is dyspnoeic, febrile and anxious. His lower jaw is inflamed, swollen, oedematous and tender.

What is the immediate appropriate step in the management of this patient?

A	Examine the inside of his mouth with a spatula
B	Request for an urgent chest X-ray
C	Take blood cultures
D	Take bloods for U/E, full blood count (FBC) and C-reactive protein (CRP)
E	Call for an anaesthetist

7505

Submit

Previous Question | Skip Question

Calculator

Normal Values

© Pastest 2017

A patient comes to the Emergency Department with difficulty in breathing which started the previous night. He has difficult giving history, as his lower jaw is painful when he tries to talk. On examination, he is dyspnoeic, febrile and anxious. His lower jaw is inflamed, swollen, oedematous and tender.

What is the immediate appropriate step in the management of this patient?

A	Examine the inside of his mouth with a spatula
B	Request for an urgent chest X-ray
C	Take blood cultures
D	Take bloods for U/E, full blood count (FBC) and C-reactive protein (CRP)
E	Call for an anaesthetist

Explanation

E	Call for an anaesthetist

This patient has most likely got Ludwig's angina, which is a rapidly spreading, life-threatening cellulitis of the sublingual and submandibular spaces that usually starts in an infected lower molar. Airway obstruction may result as the infection spreads to the supraglottic tissues.

A	Examine the inside of his mouth with a spatula

This patient's breathless may be secondary to partial airway obstruction. An anaesthetist should be called to visualise the airway and institute definitive management as required.

B	Request for an urgent chest X-ray

This patient is at significant risk of airway obstruction; therefore management of their airway is the most appropriate next immediate step.

C	Take blood cultures

Following definitive management of the patient's airway, treatment with intravenous antibiotics active against streptococci and oral anaerobes should be started.

D	Take bloods for U/E, full blood count (FBC) and C-reactive protein (CRP)

Routine bloods will be helpful in tracking the patient's progress over coming days, but taking them is not an immediate priority.

7505

Rate this question:

Next Question

Previous Question | Tag Question

Feedback | End Session

Difficulty: Average

Peer Responses %

Session Progress

Responses Correct:	0
Responses Incorrect:	48
Responses Total:	48
Responses - % Correct:	0%

© Pastest 2017

A 70-year-old lady is referred to the Medical Clinic by her general practitioner (GP) following shortness of breath. She has been seeing her GP over the last couple of months for increasing shortness of breath on exercise. Her GP had done some investigations but still could not explain her shortness of breath on exercise. She has had a dry cough which has been on and off for the last 4 months. On examination, her blood pressure is 135/80 mmHg, pulse 70 bpm and regular. Her jugular venous pulse is not raised and her heart sounds are normal. Her breathing is noisy but her chest is clinically clear on auscultation.

Which investigation is likely to be most helpful in determining where any obstruction lies?

A	Chest X-ray
B	Bronchoscopy
C	Flow volume loop
D	Polysomnography
E	Arterial blood gases

7506

Submit

Previous Question | Skip Question

Calculator

Normal Values

© Pastest 2017

A 70-year-old lady is referred to the Medical Clinic by her general practitioner (GP) following shortness of breath. She has been seeing her GP over the last couple of months for increasing shortness of breath on exercise. Her GP had done some investigations but still could not explain her shortness of breath on exercise. She has had a dry cough which has been on and off for the last 4 months. On examination, her blood pressure is 135/80 mmHg, pulse 70 bpm and regular. Her jugular venous pulse is not raised and her heart sounds are normal. Her breathing is noisy but her chest is clinically clear on auscultation.

Which investigation is likely to be most helpful in determining where any obstruction lies?

A	Chest X-ray
B	Bronchoscopy
C	Flow volume loop
D	Polysomnography
E	Arterial blood gases

Explanation

C	Flow volume loop

This patient likely has a partial upper airway obstruction. The causes in this age group would include: a tumour, a multinodular goitre or an aneurysm. A flow loop volume would show characteristic patterns with intrathoracic/extrathoracic obstruction.

A	Chest X-ray

This patient has signs suggestive of partial upper airway obstruction. A chest X-ray would not help determining where the upper airway obstruction lies. A significant multinodular goitre may, however, be an incidental finding on chest X-ray.

B	Bronchoscopy

Though bronchoscopy is important in the diagnosis and management of central airway obstruction, its role in the diagnosis of upper airway obstruction is limited.

D	Polysomnography

This test would not help determine the location of the upper airway obstruction. Polysomnography is used in the diagnosis of sleep disorders.

E	Arterial blood gases

In the context of the history given, there is no indication for an arterial blood gas.

7506

Rate this question:

Next Question

Previous Question | Tag Question

Feedback | End Session

Difficulty: Average

Peer Responses %

Session Progress

Responses Correct:	0
Responses Incorrect:	49
Responses Total:	49
Responses - % Correct:	0%

© Pastest 2017

A 62-year-old lady presents to the Emergency Admission with a cough, which she has had for the past 3 days. She was previously well until she got this cough, which is productive of purulent sputum. She also has right-sided chest pains, fever and some shortness of breath. On examination, she is confused, febrile with a blood pressure of 89/60 mmHg, pulse rate of 102/min and a respiratory rate of 31/min. Her oxygen saturation is 89%. She has right-sided upper lobe bronchial sounds on auscultation. Her abdominal examination is unremarkable.

The following results are obtained:

Haemoglobin	12.3 g/dl
Mean cell volume	89 fl
Platelets	178 x 10^9/l
White cell count	15.1 x 10^9/l
Sodium	133 mmol/l
Potassium	3.2 mmol/l
Urea	8.1 mmol/l
Creatinine	112 mol/l
C-reactive protein (CRP)	59
Chest X-ray	right upperconsolidation

What would be the most appropriate next step in her immediate management?

A	Start her on oral antibiotics
B	Intravenous fluids
C	High flow oxygen mask for delivery of 60-80% F_iO_2
D	Hypertonic saline solution
E	Potassium supplements

7507

Submit

Previous Question | Skip Question

Calculator

Normal Values

© Pastest 2017

A 62-year-old lady presents to the Emergency Admission with a cough, which she has had for the past 3 days. She was previously well until she got this cough, which is productive of purulent sputum. She also has right-sided chest pains, fever and some shortness of breath. On examination, she is confused, febrile with a blood pressure of 89/60 mmHg, pulse rate of 102/min and a respiratory rate of 31/min. Her oxygen saturation is 89%. She has right-sided upper lobe bronchial sounds on auscultation. Her abdominal examination is unremarkable.

The following results are obtained:

Haemoglobin	12.3 g/dl
Mean cell volume	89 fl
Platelets	178 x 10^9/l
White cell count	15.1 x 10^9/l
Sodium	133 mmol/l
Potassium	3.2 mmol/l
Urea	8.1 mmol/l
Creatinine	112 mol/l
C-reactive protein (CRP)	59
Chest X-ray	right upperconsolidation

What would be the most appropriate next step in her immediate management?

A	Start her on oral antibiotics
B	Intravenous fluids
C	High flow oxygen mask for delivery of 60-80% F_IO_2
D	Hypertonic saline solution
E	Potassium supplements

Explanation

This lady has severe pneumonia, which has a mortality of about 10% of patients admitted to the hospital. Features of severity include: confusion, urea > 7.0 mmol/l, respiratory rate ⩾ 30/min, blood pressure (BP) less than 90 systolic. Score of > 2 indicates severe pneumonia. She would of course as rapidly as possible need intravenous antibiotics, fluids, % and analgesia. In this situation the most marked abnormality is the O_2 saturation of 89%, this should therefore be addressed first.

7507

Rate this question:

Next Question

Previous Question | Tag Question

Feedback | End Session

Difficulty: Easy

Peer Responses %

Session Progress

Responses Correct:	0
Responses Incorrect:	50
Responses Total:	50
Responses - % Correct:	0%

© Pastest 2017

A 55-year-old man presents to the Emergency Admission with dry cough and shortness of breath, which he has had for the past 4 days. He also complains of some abdominal discomfort, nausea, vomiting, diarrhoea and a headache. He was previously well before he developed these symptoms and is not on any medication. On examination, he is unwell with a blood pressure of 123/67 mmHg, pulse of 92/min and a respiratory rate of 22/min. On auscultation of his chest, he has bi-basal crackles. His cardiovascular examination is unremarkable.

The following results are obtained:

Haemoglobin	14.3 g/dl
Mean cell volume	89 fl
Platelets	278 x 10^9 /l
White cell count	16.1 x 10^9 /l
Sodium	129 mmol/l
Potassium	3.5 mmol/l
Urea	8.1 mmol/l
Creatinine	112 mol/l
C-reactive protein (CRP)	69
Urinalysis	protein ++, blood ++, glucose –

What is the likely diagnosis?

A	Streptococcal pneumoniae
B	Mycoplasma pneumoniae
C	Chlamydia pneumoniae
D	Legionella pneumophila
E	Viral pneumonia

7508

Submit

Previous Question | Skip Question

Calculator

Normal Values

© Pastest 2017

A 55-year-old man presents to the Emergency Admission with dry cough and shortness of breath, which he has had for the past 4 days. He also complains of some abdominal discomfort, nausea, vomiting, diarrhoea and a headache. He was previously well before he developed these symptoms and is not on any medication. On examination, he is unwell with a blood pressure of 123/67 mmHg, pulse of 92/min and a respiratory rate of 22/min. On auscultation of his chest, he has bi-basal crackles. His cardiovascular examination is unremarkable.

The following results are obtained:

Haemoglobin	14.3 g/dl
Mean cell volume	89 fl
Platelets	278 x 10^9 /l
White cell count	16.1 x 10^9 /l
Sodium	129 mmol/l
Potassium	3.5 mmol/l
Urea	8.1 mmol/l
Creatinine	112 mol/l
C-reactive protein (CRP)	69
Urinalysis	protein ++, blood ++, glucose –

What is the likely diagnosis?

A	Streptococcal pneumoniae
B	Mycoplasma pneumoniae
C	Chlamydia pneumoniae
D	Legionella pneumophila
E	Viral pneumonia

Explanation

The most likely diagnosis is legionella pneumophila. It usually infects middle-aged men; more severe in smokers and has an incubation period of 2-10 days. Male to female ratio is 2:1. It causes moderate leucocytosis (neutrophilia, lymphopenia), hyponatraemia, deranged LFTs, proteinuria, haematuria and myoglobinuria. Diagnosis: Legionella urinary antigen. Usual treatment is with macrolide antibiotics such as clarithromycin. Fluoroquinolones and doxycycline are reasonable alternatives. Rifampacin is usually only considered for combination therapy with macrolide when there is severe pneumonia or significant co-morbidity.

http://www.ncbi.nlm.nih.gov/pubmed/21775694

7508

Rate this question:

Next Question

Previous Question | Tag Question

Feedback | End Session

Difficulty: Easy

Peer Responses %

Session Progress

Responses Correct:	0
Responses Incorrect:	51
Responses Total:	51
Responses - % Correct:	0%

© Pastest 2017

A 55-year-old man presents to the Emergency Admission with dry cough and shortness of breath, which he has had for the past 4 days. He has recently returned from a winter holiday to an all inclusive hotel in Spain. He also complains of some abdominal discomfort, nausea, vomiting, diarrhoea and a headache. He was previously well before he developed these symptoms and is not on any medication. On examination, he is unwell with a blood pressure of 123/67 mmHg, pulse of 92/min and a respiratory rate of 22/min. On auscultation of his chest, he has bi-basal crackles. His cardiovascular examination is unremarkable.

The following results are obtained:

Haemoglobin	14.3 g/dl
Mean cell volume	89 fl
Platelets	278 x 10^9 /l
White Cell Count	16.1 x 10^9 /l
Sodium	129 mmol/l
Potassium	3.5 mmol/l
Urea	8.1 mmol/l
Creatinine	112 mol/l
C-reactive protein (CRP)	69

What initial investigation is most likely to be helpful in elucidating the diagnosis?

A	Urinary immunoglobulin titres
B	Sputum microscopy and culture
C	Stool microscopy and culture
D	Bronchoalveolar lavage
E	Urinary antigen testing

7509

Submit

Previous Question | Skip Question

Calculator

Normal Values

© Pastest 2017

A 55-year-old man presents to the Emergency Admission with dry cough and shortness of breath, which he has had for the past 4 days. He has recently returned from a winter holiday to an all inclusive hotel in Spain. He also complains of some abdominal discomfort, nausea, vomiting, diarrhoea and a headache. He was previously well before he developed these symptoms and is not on any medication. On examination, he is unwell with a blood pressure of 123/67 mmHg, pulse of 92/min and a respiratory rate of 22/min. On auscultation of his chest, he has bi-basal crackles. His cardiovascular examination is unremarkable.

The following results are obtained:

Haemoglobin	14.3 g/dl
Mean cell volume	89 fl
Platelets	278 x 10^9 /l
White Cell Count	16.1 x 10^9 /l
Sodium	129 mmol/l
Potassium	3.5 mmol/l
Urea	8.1 mmol/l
Creatinine	112 mol/l
C-reactive protein (CRP)	69

What initial investigation is most likely to be helpful in elucidating the diagnosis?

A	Urinary immunoglobulin titres
B	Sputum microscopy and culture
C	Stool microscopy and culture
D	Bronchoalveolar lavage
E	Urinary antigen testing

Explanation

The most likely diagnosis is legionella pneumophila. It usually infects middle-aged men; more severe in smokers, is twice as common in men and has an incubation period of 2-10 days. It causes moderate leucocytosis (neutrophilia, lymphopenia), hyponatraemia, deranged LFTs, proteinuria, haematuria and myoglobinuria. Diagnosis: urinary antigen testing, rise in specific IgM and IgG titres in the urine, blood and sputum or by direct immunofluorescent staining of the organism via bronchial washings. Treatment is with a macrolide antibiotic such as clarithromycin.

7509

Rate this question:

Next Question

Previous Question | Tag Question

Feedback | End Session

Difficulty: Easy

Peer Responses %

Session Progress

Responses Correct:	0
Responses Incorrect:	52
Responses Total:	52
Responses - % Correct:	0%

© Pastest 2017

A 27-year-old pregnant lady is referred to the Emergency Admission for sudden development of shortness of breath. She was well until 2 days ago when she developed shortness of breath. She has some slight left-sided chest pains but no cough or haemoptysis. She is 28 weeks pregnant and has had no problems with the pregnancy. There is no history of long flights or swelling of her legs. On examination, she appears anxious with a blood pressure of 110/60 mmHg, pulse rate of 92/min and a respiratory rate of 26/min. Her oxygen saturation on air is 98%. Her abdomen is distended and fetal movements are seen. Her chest is clinically clear. Her cardiovascular and lower limb examinations are unremarkable.

The following results are obtained:

Haemoglobin	11.3 g/dl
Mean cell volume	89 fl
Platelets	278 x 10^9/l
White cell count	10.1 x 10^9/l
Sodium	139 mmol/l
Potassium	3.5 mmol/l
Urea	6.1 mmol/l
Creatinine	112 mol/l
C-reactive protein (CRP)	6 mg/l (<10)
D-dimers	0.62 mg/l (normal is < 0.25 mg/l)

Which of the following investigations would be the most appropriate initial investigation in her case?

A	Bilateral leg dopplers
B	Ventilation/perfusion (V/Q) scan
C	Chest X-ray
D	Pulmonary angiography
E	Echocardiogram

7510

Submit

Previous Question | Skip Question

Calculator

Normal Values

© Pastest 2017

A 27-year-old pregnant lady is referred to the Emergency Admission for sudden development of shortness of breath. She was well until 2 days ago when she developed shortness of breath. She has some slight left-sided chest pains but no cough or haemoptysis. She is 28 weeks pregnant and has had no problems with the pregnancy. There is no history of long flights or swelling of her legs. On examination, she appears anxious with a blood pressure of 110/60 mmHg, pulse rate of 92/min and a respiratory rate of 26/min. Her oxygen saturation on air is 98%. Her abdomen is distended and fetal movements are seen. Her chest is clinically clear. Her cardiovascular and lower limb examinations are unremarkable.

The following results are obtained:

Haemoglobin	11.3 g/dl
Mean cell volume	89 fl
Platelets	278 x 10^9/l
White cell count	10.1 x 10^9/l
Sodium	139 mmol/l
Potassium	3.5 mmol/l
Urea	6.1 mmol/l
Creatinine	112 mol/l
C-reactive protein (CRP)	6 mg/l (<10)
D-dimers	0.62 mg/l (normal is < 0.25 mg/l)

Which of the following investigations would be the most appropriate initial investigation in her case?

A	Bilateral leg dopplers
B	Ventilation/perfusion (V/Q) scan
C	Chest X-ray
D	Pulmonary angiography
E	Echocardiogram

Explanation

Ventilation/perfusion (V/Q) imaging is well established for imaging PE and clinical surveys have indicated that it is the most commonly chosen investigation to rule out PE in pregnancy. A negative scan excludes PE but the group with indeterminate or high probability results may not in fact have PE (up to 20% false positive rate).

CTPA is now a well-validated investigation with a sensitivity and specificity between 94% and 100%, being therefore superior in this regard to V/Q scanning.

Concerns regarding radiation dose associated with CT scanning must be balanced against the risk to the mother of undiagnosed PE or the (unnecessary) treatment of unconfirmed PE.

Recent studies have shown that the fetal radiation exposure for CTPA varies from 3.3 Gy to 130.0 Gy; the dose increasing during each trimester as the fetus enlarges and approaches the imaged area in the thorax. However, the estimated fetal radiation dose for V/Q scanning is estimated as 100–370 Gy, i.e. the dose may be more than 3 times greater than for CTPA.

In addition to the radiation risk to the fetus, the breast radiation dose from CTPA must be considered.

It has been suggested that an appropriate plan of investigation could consist of the following steps: initially, estimation of pre-test probability, based on assessment by a senior clinician and measurement of D-dimers (in the first 2 trimesters). If further investigation is deemed necessary, CXR is seen as the next step in the absence of leg signs. In the presence of leg signs, bilateral leg Doppler can be performed. If leg Doppler is positive, chest x-ray and then CTPA are the next recommended steps.

If there are no leg signs then the recommendation is to progress to x-ray and CTPA if clinical suspicion is very high.

7510

Rate this question:

Next Question

Previous Question | Tag Question

Feedback | End Session

Difficulty: Average

Peer Responses %

Session Progress

Responses Correct:	0
Responses Incorrect:	53
Responses Total:	53
Responses - % Correct:	0%

© Pastest 2017

A 27-year-old pregnant lady is referred to the Emergency Admission for sudden development of shortness of breath. She was well until 2 days ago when she developed shortness of breath. She has some slight left-sided chest pains but no cough or haemoptysis. She is 28 weeks pregnant and has had no problems with the pregnancy. There is no history of long flights or swelling of her legs. On examination, she appears anxious with a blood pressure of 110/60 mmHg, pulse rate of 92/min and a respiratory rate of 26/min. Her oxygen saturation on air is 98%. Her abdomen is distended and fetal movements are seen. Her chest is clinically clear. Her cardiovascular and lower limb examinations are unremarkable.

The following results are obtained:

Haemoglobin	11.3 g/dl
Mean cell volume	89 fl
Platelets	278 x 10^9/l
White cell count	10.1 x 10^9/l
Sodium	139 mmol/l
Potassium	3.5 mmol/l
Urea	6.1 mmol/l
Creatinine	112 mol/l
C-reactive protein (CRP)	6 mg/l
D-dimers	0.62 mg/l (normal is < 0.25 mg/l)
pH	7.45
pa(O_2) on air	13.0 kPa
pa(CO_2) on air	3.9 kPa
CXR	no focal abnormality
V/Q scan	low probability of pulmonary embolism (PE)

What would be the most appropriate step in her immediate management?

A	Start her on a low molecular weight heparin
B	Start her on warfarin
C	Arrange for her discharge
D	Start her on low-dose aspirin
E	Thrombolyse her

7511

Submit

Previous Question | Skip Question

Calculator

Normal Values

© Pastest 2017

A 27-year-old pregnant lady is referred to the Emergency Admission for sudden development of shortness of breath. She was well until 2 days ago when she developed shortness of breath. She has some slight left-sided chest pains but no cough or haemoptysis. She is 28 weeks pregnant and has had no problems with the pregnancy. There is no history of long flights or swelling of her legs. On examination, she appears anxious with a blood pressure of 110/60 mmHg, pulse rate of 92/min and a respiratory rate of 26/min. Her oxygen saturation on air is 98%. Her abdomen is distended and fetal movements are seen. Her chest is clinically clear. Her cardiovascular and lower limb examinations are unremarkable.

The following results are obtained:

Haemoglobin	11.3 g/dl
Mean cell volume	89 fl
Platelets	278 x 10^9/l
White cell count	10.1 x 10^9/l
Sodium	139 mmol/l
Potassium	3.5 mmol/l
Urea	6.1 mmol/l
Creatinine	112 mol/l
C-reactive protein (CRP)	6 mg/l
D-dimers	0.62 mg/l (normal is < 0.25 mg/l)
pH	7.45
pa(O_2) on air	13.0 kPa
pa(CO_2) on air	3.9 kPa
CXR	no focal abnormality
V/Q scan	low probability of pulmonary embolism (PE)

What would be the most appropriate step in her immediate management?

A	Start her on a low molecular weight heparin
B	Start her on warfarin
C	Arrange for her discharge
D	Start her on low-dose aspirin
E	Thrombolyse her

Explanation

A low probability V/Q scan has a low clinical suspicion of pulmonary emboli (PE) and should prompt a search for another cause for the patient's symptoms. A negative D-dimer makes a PE highly unlikely, but D-dimers are often raised for other reasons apart from PE, reasons include advancing age, pregnancy (as in this case), trauma, malignancy and inflammatory states. This lady is probably just anxious as reflected by the hyperventilation and arterial blood gases. She can safely be discharged, reassured and told to call back if she has any concerns.

7511

Rate this question:

Next Question

Previous Question | Tag Question

Feedback | End Session

Difficulty: Very difficult

Peer Responses %

Session Progress

Responses Correct:	0
Responses Incorrect:	54
Responses Total:	54
Responses - % Correct:	0%

© Pastest 2017

A 27-year-old pregnant lady is referred to the Emergency Admission for sudden development of shortness of breath. She was well until 2 days ago when she developed shortness of breath. She has some slight left sided chest pains but no cough or haemoptysis. She is 28 weeks pregnant and has had no problems with the pregnancy. There is no history of long flights or swelling of her legs. On examination, she appears anxious with a blood pressure of 110/60 mmHg, pulse rate of 92/min and a respiratory rate of 26/min. Her oxygen saturation on air is 98%. Her abdomen is distended and fetal movements are seen. Her chest is clinically clear. Her cardiovascular and lower limb examinations are unremarkable.

The following results are obtained:

Sodium	139 mmol/l
Potassium	3.5 mmol/l
Urea	6.1 mmol/l
Creatinine	112 mol/l
C-reactive protein (CRP)	6
D-dimers	0.62 mg/l (normal is < 0.25 mg/l)
Haemoglobin	11.3 g/dl
Mean cell volume	89 fl
Platelets	278 x 10^9 /l
White cell count	10.1 x 10^9 /l
pH	7.45
$p_a(O_2)$	9.3 kPa
$p_a(CO_2)$	3.9 kPa
V/Q scan	high probability of pulmonary embolism (PE)

What would be the most appropriate step in her immediate management?

A	Start her on a low molecular weight heparin
B	Start her on warfarin
C	Arrange for her discharge
D	Start her on low-dose aspirin
E	Thrombolyse her

7512

Submit

Previous Question | Skip Question

Calculator

Normal Values

© Pastest 2017

A 27-year-old pregnant lady is referred to the Emergency Admission for sudden development of shortness of breath. She was well until 2 days ago when she developed shortness of breath. She has some slight left sided chest pains but no cough or haemoptysis. She is 28 weeks pregnant and has had no problems with the pregnancy. There is no history of long flights or swelling of her legs. On examination, she appears anxious with a blood pressure of 110/60 mmHg, pulse rate of 92/min and a respiratory rate of 26/min. Her oxygen saturation on air is 98%. Her abdomen is distended and fetal movements are seen. Her chest is clinically clear. Her cardiovascular and lower limb examinations are unremarkable.

The following results are obtained:

Sodium	139 mmol/l
Potassium	3.5 mmol/l
Urea	6.1 mmol/l
Creatinine	112 mol/l
C-reactive protein (CRP)	6
D-dimers	0.62 mg/l (normal is < 0.25 mg/l)
Haemoglobin	11.3 g/dl
Mean cell volume	89 fl
Platelets	278 x 10^9 /l
White cell count	10.1 x 10^9 /l
pH	7.45
$p_a(O_2)$	9.3 kPa
$p_a(CO_2)$	3.9 kPa
V/Q scan	high probability of pulmonary embolism (PE)

What would be the most appropriate step in her immediate management?

A	Start her on a low molecular weight heparin
B	Start her on warfarin
C	Arrange for her discharge
D	Start her on low-dose aspirin
E	Thrombolyse her

Explanation

The whole clinical picture is highly suggestive of a pulmonary emboli (PE) and she should be treated with low-molecular weight heparin. A high probability scan is strongly associated with a PE. In PE arterial blood gases typically show a low pa(O_2) and a low pa(CO_2) as in this case.She is 28 weeks pregnant and thrombolysis should clearly be avoided.

7512

Rate this question:

Next Question

Previous Question | Tag Question

Feedback | End Session

Difficulty: Average

Peer Responses %

Session Progress

Responses Correct:	0
Responses Incorrect:	55
Responses Total:	55
Responses - % Correct:	0%

© Pastest 2017

A 24-year-old man presents to the Emergency Admission for being unwell over the last couple of days. He tells you that he has had flu for the last 4 days. He complains of a dry cough, headache, fever, malaise and muscle pains. On examination, he is unwell with a blood pressure of 110/60 mmHg, pulse 92/min and a respiratory rate of 22/min. His oxygen saturation is 95% on air. On auscultation, he has scattered crackles in both lung fields. His cardiovascular and abdominal examinations are unremarkable.

The following results are obtained:

Sodium	130 mmol/l
Potassium	3.5 mmol/l
Urea	8.1 mmol/l
Creatinine	112 mol/l
C-reactive protein (CRP)	76
Haemoglobin	9.8 g/dl
Mean cell volume	89 fl
Platelets	278 x 10^9 /l
White cell count	12.1 x 10^9 /l
Blood film	fragmented red cells, reticulocytosis

What is the likely diagnosis?

A	Streptococcal pneumoniae
B	Mycoplasma pneumoniae
C	Chlamydia pneumoniae
D	Legionella pneumophila
E	Viral pneumonia

7513

Submit

Previous Question Skip Question

Calculator

Normal Values

© Pastest 2017

A 24-year-old man presents to the Emergency Admission for being unwell over the last couple of days. He tells you that he has had flu for the last 4 days. He complains of a dry cough, headache, fever, malaise and muscle pains. On examination, he is unwell with a blood pressure of 110/60 mmHg, pulse 92/min and a respiratory rate of 22/min. His oxygen saturation is 95% on air. On auscultation, he has scattered crackles in both lung fields. His cardiovascular and abdominal examinations are unremarkable.

The following results are obtained:

Sodium	130 mmol/l
Potassium	3.5 mmol/l
Urea	8.1 mmol/l
Creatinine	112 mol/l
C-reactive protein (CRP)	76
Haemoglobin	9.8 g/dl
Mean cell volume	89 fl
Platelets	278 x 10^9 /l
White cell count	12.1 x 10^9 /l
Blood film	fragmented red cells, reticulocytosis

What is the likely diagnosis?

A	Streptococcal pneumoniae
B	Mycoplasma pneumoniae
C	Chlamydia pneumoniae
D	Legionella pneumophila
E	Viral pneumonia

Explanation

Mycoplasma pneumoniae is a disease of young adults. It presents with flu-like symptoms with low-grade fever, dry cough, headache and myalgia. Cold agglutinins may cause an autoimmune haemolytic anaemia. Coombs' test is positive. The low sodium is related to SIADH.

7513

Rate this question:

Next Question

Previous Question | Tag Question

Feedback | End Session

Difficulty: Easy

Peer Responses %

Session Progress

Responses Correct:	0
Responses Incorrect:	56
Responses Total:	56
Responses - % Correct:	0%

© Pastest 2017

A 24-year-old man presents to the Emergency Admission for being unwell over the last couple of days. He tells you that he has had flu for the last 4 days. He complains of a dry cough, headache, fever, malaise and muscle pains. On examination, he is unwell with a blood pressure of 110/60 mmHg, pulse 92/min and a respiratory rate of 22/min. His oxygen saturation is 95% on air. On auscultation, he has scattered crackles in both lung fields. His cardiovascular and abdominal examinations are unremarkable.

The following results are obtained:

Sodium	130 mmol/l
Potassium	3.5 mmol/l
Urea	8.1 mmol/l
Creatinine	112 mol/l
C-reactive protein (CRP)	76
Haemoglobin	9.8 g/dl
Mean cell volume	89 fl
Platelets	278 x 10^9 /l
White cell count	12.1 x 10^9 /l
Blood film	fragmented red cells, reticulocytosis
Coombs' test	positive

How would you treat this patient?

A	Clarithromycin
B	Flucloxacillin
C	Rifampicin
D	Gentamicin
E	Ciprofloxacin

7514

Submit

Previous Question Skip Question

Calculator

Normal Values

© Pastest 2017

A 24-year-old man presents to the Emergency Admission for being unwell over the last couple of days. He tells you that he has had flu for the last 4 days. He complains of a dry cough, headache, fever, malaise and muscle pains. On examination, he is unwell with a blood pressure of 110/60 mmHg, pulse 92/min and a respiratory rate of 22/min. His oxygen saturation is 95% on air. On auscultation, he has scattered crackles in both lung fields. His cardiovascular and abdominal examinations are unremarkable.

The following results are obtained:

Sodium	130 mmol/l
Potassium	3.5 mmol/l
Urea	8.1 mmol/l
Creatinine	112 mol/l
C-reactive protein (CRP)	76
Haemoglobin	9.8 g/dl
Mean cell volume	89 fl
Platelets	278 x 10^9 /l
White cell count	12.1 x 10^9 /l
Blood film	fragmented red cells, reticulocytosis
Coombs' test	positive

How would you treat this patient?

A	Clarithromycin
B	Flucloxacillin
C	Rifampicin
D	Gentamicin
E	Ciprofloxacin

Explanation

Mycoplasma pneumoniae is a disease of young adults. It presents with flu-like symptoms with low-grade fever, dry cough, headache and myalgia. Cold agglutinins may cause an autoimmune haemolytic anaemia. Coombs' test is positive. Treatment is with erythromycin/clarithromycin or tetracycline.

7514

Rate this question:

Next Question

Previous Question | Tag Question

Feedback | End Session

Difficulty: Average

Peer Responses %

Session Progress

Responses Correct:	0
Responses Incorrect:	57
Responses Total:	57
Responses - % Correct:	0%

© Pastest 2017

A 72-year-old lady is brought to the Emergency Department by ambulance after her daughter found her unresponsive. The daughter who lives next door frequently visits her mother. Today her mother did not respond to the doorbell and when she opened the door she found her mother sprawled on the couch. She also found the gas heater switched on but there was no flame. She then quickly called the ambulance. On examination, the patient is drowsy with a Glasgow Coma Scale of 12/15, blood pressure of 154/90, pulse of 98/min and a respiratory rate of 28/min. The patient has already been started on high flow oxygen via a non-rebreather mask.

What single initial investigation would be most helpful in determining the prognosis for this patient?

A	Toxicology screen
B	Carboxyhaemoglobin (COHb)
C	12-lead electrocardiogram
D	Full blood count (FBC), U and E, creatine phosphokinase (CPK) and cardiac enzymes
E	Oxygen saturation with pulse oximeter

7515

Submit

Previous Question Skip Question

Calculator

Normal Values

Blog About Pastest Contact Us Help

© Pastest 2017

A 72-year-old lady is brought to the Emergency Department by ambulance after her daughter found her unresponsive. The daughter who lives next door frequently visits her mother. Today her mother did not respond to the doorbell and when she opened the door she found her mother sprawled on the couch. She also found the gas heater switched on but there was no flame. She then quickly called the ambulance. On examination, the patient is drowsy with a Glasgow Coma Scale of 12/15, blood pressure of 154/90, pulse of 98/min and a respiratory rate of 28/min. The patient has already been started on high flow oxygen via a non-rebreather mask.

What single initial investigation would be most helpful in determining the prognosis for this patient?

A	Toxicology screen
B	Carboxyhaemoglobin (COHb)
C	12-lead electrocardiogram
D	Full blood count (FBC), U and E, creatine phosphokinase (CPK) and cardiac enzymes
E	Oxygen saturation with pulse oximeter

Explanation

COHb levels have prognostic implications in carbon monoxide poisoning, the diagnosis here:

<30% cause only headaches and dizziness, 40-60% produces syncope, tachypnea, tachycardia and fits, >60% cause increasing risk of cardiorespiratory failure and death.

Apply a tight-fitting non-rebreather mask and give 100% oxygen. If the patient is comatose, she should be intubated and ventilated with 100% oxygen. Hyperbaric oxygen will shorten the wash-out of COHb.

7515

Rate this question:

Next Question

Previous Question | Tag Question

Feedback | End Session

Difficulty: Average

Peer Responses %

Session Progress

Responses Correct:	0
Responses Incorrect:	58
Responses Total:	58
Responses - % Correct:	0%

© Pastest 2017

A 72-year-old lady is brought to the Emergency Department by ambulance after her daughter found her unresponsive. The daughter who lives next door frequently visits her mother. Today her mother did not respond to the doorbell and when she opened the door she found her mother sprawled on the couch. She also found the gas stove switched on but there was no flame. She then quickly called the ambulance. On examination, the patient is drowsy with a Glasgow Coma Scale of 12/15, blood pressure of 154/90; pulse of 98/min and a respiratory rate of 28/min. Oxygen saturation is 99%. The patient has already been started on high flow oxygen via a non-rebreather mask.

The following results are obtained:

$p_a(O_2)$	9.8 kPa
$p_a(CO_2)$	4.8 kPa
Bicarbonate	15 mmol/l
Carboxyhaemoglobin (COHb)	45%

What is the significance of the COHb, oxygen saturation and arterial blood gas results?

A	The acidosis should be treated with bicarbonate infusion
B	The $p_a(CO_2)$ has prognostic implications
C	Oxygen saturation by pulse oximeter can be used to monitor tissue oxygen saturation
D	The level of COHb increases the risk of fits
E	This patient is at high risk of sudden death

7516

Submit

Previous Question | Skip Question

Calculator

Normal Values

© Pastest 2017

A 72-year-old lady is brought to the Emergency Department by ambulance after her daughter found her unresponsive. The daughter who lives next door frequently visits her mother. Today her mother did not respond to the doorbell and when she opened the door she found her mother sprawled on the couch. She also found the gas stove switched on but there was no flame. She then quickly called the ambulance. On examination, the patient is drowsy with a Glasgow Coma Scale of 12/15, blood pressure of 154/90; pulse of 98/min and a respiratory rate of 28/min. Oxygen saturation is 99%. The patient has already been started on high flow oxygen via a non-rebreather mask.

The following results are obtained:

$p_a(O_2)$	9.8 kPa
$p_a(CO_2)$	4.8 kPa
Bicarbonate	15 mmol/l
Carboxyhaemoglobin (COHb)	45%

What is the significance of the COHb, oxygen saturation and arterial blood gas results?

A	The acidosis should be treated with bicarbonate infusion
B	The $p_a(CO_2)$ has prognostic implications
C	Oxygen saturation by pulse oximeter can be used to monitor tissue oxygen saturation
D	The level of COHb increases the risk of fits
E	This patient is at high risk of sudden death

Explanation

COHb levels have prognostic implications in carbon monoxide poisoning, the diagnosis here:

<30% cause only headache and dizziness, 40-60% produces syncope, tachypnea, tachycardia and fits, >60% cause increasing risk of cardiorespiratory failure and death.

Monitoring oxygen saturation with a pulse oximeter is unhelpful since it will not distinguish HbO_2 and COHb. Fits should be controlled by intravenous diazepam (5–10 mg). The metabolic acidosis corrects itself when the hypoxia is treated and does not require treatment with intravenous bicarbonate.

7516

Rate this question:

Next Question

Previous Question | Tag Question

Feedback | End Session

Difficulty: Easy

Peer Responses %

Session Progress

Responses Correct:	0
Responses Incorrect:	59
Responses Total:	59
Responses - % Correct:	0%

© Pastest 2017

A 72-year-old lady is brought to the Emergency Department by ambulance after her daughter found her unresponsive. The daughter who lives next door frequently visits her mother. Today her mother did not respond to the doorbell and when she opened the door she found her mother sprawled on the couch. She also found the gas stove switched on but there was no flame. She then quickly called the ambulance. On examination, the patient is drowsy with a Glasgow Coma Scale of 12/15, blood pressure of 154/90; pulse of 98/min and a respiratory rate of 28/min. Oxygen saturation is 99%.

The following results are obtained:

pH	7.27
$p_a(O_2)$	9.8 kPa
$p_a(CO_2)$	2.8 kPa
Bicarbonate	20 mmol/l
Carboxyhaemoglobin (COHb)	45%

What would be the most appropriate step in her immediate management?

A	Apply a tight-fitting non-rebreather mask and give 100% oxygen
B	Patient should be intubated and ventilated with 100%
C	Treat the metabolic acidosis with bicarbonate infusion
D	Put the patient on a cardiac monitor
E	Hyperbaric oxygen

7517

© Pastest 2017

A 72-year-old lady is brought to the Emergency Department by ambulance after her daughter found her unresponsive. The daughter who lives next door frequently visits her mother. Today her mother did not respond to the doorbell and when she opened the door she found her mother sprawled on the couch. She also found the gas stove switched on but there was no flame. She then quickly called the ambulance. On examination, the patient is drowsy with a Glasgow Coma Scale of 12/15, blood pressure of 154/90; pulse of 98/min and a respiratory rate of 28/min. Oxygen saturation is 99%.

The following results are obtained:

pH	7.27
$p_a(O_2)$	9.8 kPa
$p_a(CO_2)$	2.8 kPa
Bicarbonate	20 mmol/l
Carboxyhaemoglobin (COHb)	45%

What would be the most appropriate step in her immediate management?

A	Apply a tight-fitting non-rebreather mask and give 100% oxygen
B	Patient should be intubated and ventilated with 100%
C	Treat the metabolic acidosis with bicarbonate infusion
D	Put the patient on a cardiac monitor
E	Hyperbaric oxygen

Explanation

COHb levels have prognostic implications in carbon monoxide poisoning, the diagnosis here:

<30% cause only headache and dizziness, 40-60% produces syncope, tachypnea, tachycardia and fits, >60% cause increasing risk of cardiorespiratory failure and death.

Apply a tight-fitting non-rebreather mask and give 100% oxygen. If the patient is comatose, she should be intubated and ventilated with 100% oxygen. Hyperbaric oxygen will shorten the wash-out of COHb but access and transfer times to a hyperbaric chamber can make this not practical. Of course, it should be considered here post the fitting of the non-rebreather.

7517

Rate this question:

Next Question

Previous Question | Tag Question

Feedback | End Session

Difficulty: Difficult

Peer Responses %

Session Progress

Responses Correct:	0
Responses Incorrect:	60
Responses Total:	60
Responses - % Correct:	0%

© Pastest 2017

The medical registrar on the grand round shows a CXR of a male patient who has an industrial lung disease. The CXR shows small rounded opacities mostly in the upper lobes and no calcification is visible. There is no hilar lymphadenopathy.

Of the known industrial lung dust diseases, which is the most likely cause given these CXR findings?

A	Asbestos
B	Coal dust
C	Silica
D	Beryllium
E	Iron dust

7623

Submit

Previous Question | Skip Question

Calculator

Normal Values

© Pastest 2017

The medical registrar on the grand round shows a CXR of a male patient who has an industrial lung disease. The CXR shows small rounded opacities mostly in the upper lobes and no calcification is visible. There is no hilar lymphadenopathy.

Of the known industrial lung dust diseases, which is the most likely cause given these CXR findings?

A	Asbestos
B	Coal dust
C	Silica
D	Beryllium
E	Iron dust

Explanation

Pneumoconiosis is a chronic reaction of the lung parenchyma as a consequence of chronic dust inhalation. The effects of dust inhalation depend on the size of the dust particle, their shape and their chemical reactivity, and consequently some dust particles are more reactive than others.

In general, the typical CXR appearances of the different dust particles are listed below:

Coal	Multiple small round opacities, typically 1–10 mm in diameter, mostly in the upper lobes
Asbestos	Pleural plaques and fibrosis more marked in the lower zones
Silica	Multiple small nodules scattered diffusely throughout the lungs and egg-shell calcification of the hilar nodes
Beryllium	Acute pneumonitis that may continue to a granulomatous reaction (compare with sarcoidosis) with lymphadenopathy
Iron dust	Nodular pulmonary pattern with greater density but with less marked fibrosis

7623

Rate this question:

Next Question

Previous Question | Tag Question

Feedback | End Session

Difficulty: Average

Peer Responses %

Session Progress

Responses Correct:	0
Responses Incorrect:	61
Responses Total:	61
Responses - % Correct:	0%

© Pastest 2017

A 12-year-old boy presents to his GP with his parents with a complaint of a dry and hacking chronic cough. The patient has become quite short of breath on exertion and the parents are quite concerned since it means the patient is no longer able to do any sporting activities at school. On further questioning, the parents report that the patient has lost his appetite and consequently some weight. The mother is also concerned since she has noticed a change in appearance of the child's stool which is very difficult to flush down the toilet. On general examination, the patient is afebrile and slightly dyspnoeic. Examination of the chest reveals a hyperresonant percussion note and on auscultation, a generalised wheeze is heard associated with coarse inspiratory crackles. The abdomen is slightly distended. The GP arranges for the child to have an urgent CXR.

Which of the following statements about the suspected diagnosis is TRUE?

A	The condition has an X-linked pattern of inheritance
B	The absence of panopacification of the sinuses on sinus radiography is strongly suggestive of the diagnosis
C	Chest X-ray may show hyperinflation with flattening of the domes of the diaphragm and peribronchial thickening
D	The condition has no effect on the fertility of affected patients
E	The disease rarely manifests before 1 year of age

7624

Submit

Previous Question | Skip Question

Calculator

Normal Values

© Pastest 2017

A 12-year-old boy presents to his GP with his parents with a complaint of a dry and hacking chronic cough. The patient has become quite short of breath on exertion and the parents are quite concerned since it means the patient is no longer able to do any sporting activities at school. On further questioning, the parents report that the patient has lost his appetite and consequently some weight. The mother is also concerned since she has noticed a change in appearance of the child's stool which is very difficult to flush down the toilet. On general examination, the patient is afebrile and slightly dyspnoeic. Examination of the chest reveals a hyperresonant percussion note and on auscultation, a generalised wheeze is heard associated with coarse inspiratory crackles. The abdomen is slightly distended. The GP arranges for the child to have an urgent CXR.

Which of the following statements about the suspected diagnosis is TRUE?

A	The condition has an X-linked pattern of inheritance
B	The absence of panopacification of the sinuses on sinus radiography is strongly suggestive of the diagnosis
C	Chest X-ray may show hyperinflation with flattening of the domes of the diaphragm and peribronchial thickening
D	The condition has no effect on the fertility of affected patients
E	The disease rarely manifests before 1 year of age

Explanation

Cystic fibrosis (CF) is an autosomal recessive disorder that affects exocrine gland function, and therefore involves a multiple number of organ systems but end-stage lung disease is the main cause of death. The condition can be diagnosed anytime in childhood up to early adulthood with the median age of survival being 30 years. Males appear to be less affected than females with the mean age of death being younger in the female patients. However, male patients are frequently infertile because of the absence of the vas deferens but fertility is maintained, albeit reduced, in female patients. Diagnosis is based on family history, clinical signs and symptoms, and a positive result on a sweat test. Sinus radiography shows panopacification of the sinuses to be present in almost all patients with CF. CXR can be normal or can show a variety of appearances such as hyperinflation and peribronchial thickening reflecting changes secondary to bronchiectasis and mucous plugging; these changes are better demonstrated using high-resolution CT.

7624

Rate this question:

Next Question

Previous Question | Tag Question

Feedback | End Session

Difficulty: Average

Peer Responses %

Session Progress

Responses Correct:	0
Responses Incorrect:	62
Responses Total:	62
Responses - % Correct:	0%

© Pastest 2017

A 47-year-old hotel cleaner presents with a fever of 39°C, malaise and myalgia followed by the development of a dry and non-productive cough. Other non-specific symptoms include headache, anorexia, nausea and non-specific abdominal pain. Positive findings on general examination include tachycardia, tachypnoea and bibasal crackles on auscultation of the chest. The CXR shows early bibasal consolidation. Blood investigations show hyponatraemia and deranged LFTs and urine dipstix shows the presence of protein and blood.

Infection with Legionella pneumophilia is suspected and whilst waiting serological confirmation of the diagnosis, which of the following would be the most appropriate antibiotic(s) to use to treat the patient?

A	Erythromycin
B	Tetracycline
C	Ciprofloxacin
D	Cefuroxime and metronidazole
E	Gentamicin and penicillin

7625

Submit

Previous Question Skip Question

Calculator

Normal Values

Blog About Pastest Contact Us Help

© Pastest 2017

A 47-year-old hotel cleaner presents with a fever of 39°C, malaise and myalgia followed by the development of a dry and non-productive cough. Other non-specific symptoms include headache, anorexia, nausea and non-specific abdominal pain. Positive findings on general examination include tachycardia, tachypnoea and bibasal crackles on auscultation of the chest. The CXR shows early bibasal consolidation. Blood investigations show hyponatraemia and deranged LFTs and urine dipstix shows the presence of protein and blood.

Infection with Legionella pneumophilia is suspected and whilst waiting serological confirmation of the diagnosis, which of the following would be the most appropriate antibiotic(s) to use to treat the patient?

A	Erythromycin
B	Tetracycline
C	Ciprofloxacin
D	Cefuroxime and metronidazole
E	Gentamicin and penicillin

Explanation

Legionella pneumophila is the organism that causes Legionnaires' disease (LD) and is a relatively common cause of community-acquired pneumonia in adults. Transmission of the organism occurs through aspiration of water contaminated with Legionella organisms. The organism is able to colonize water tanks kept at <60°C (e.g. air conditioning units). Treatment of the pneumonia — which is the predominant clinical manifestation of LD — is with high dose erythromycin, although the newer agents of clarithromycin and azithromycin may be preferred since they provide higher penetration into lung tissues. Treatment is usually for 2 weeks in patients with mild disease but in patients who are immunocompromised or who have severe disease, treatment is continued for 3 weeks. Ciprofloxacin is a recognised alternative to macrolides.

7625

Rate this question:

Next Question

Previous Question | Tag Question

Feedback | End Session

Difficulty: Average

Peer Responses %

Session Progress

Responses Correct:	0
Responses Incorrect:	63
Responses Total:	63
Responses - % Correct:	0%

© Pastest 2017

A 68-year-old man with a 10-year history of chronic obstructive pulmonary disease presents with a 6-month history of increasing exertional dyspnoea and fatigue. He also has a cough productive of yellow sputum, episodes of chest pain, nausea and anorexia. He stopped smoking 2 years ago. On examination he had a raised jugular venous pressure, right parasternal heave, a loud second heart sound and an ejection systolic murmur at the left second intercostal space. On chest auscultation he had scattered expiratory wheeze. He had pitting leg oedema.

Investigation results are below:

Haemoglobin (Hb)	18.0 g/dl
Na^+	135 mmol/l
Bilirubin	16 µmol/l
White cell count (WCC)	8.0 x 10^9/l
K^+	4.2 mmol/l
Alanine transferase (ALT)	50 iu/l
Platelets	220 x 10^9/l
Urea	4.6 mmol/l
Alkaline phosphatase	120 iu/l
Creatinine	110 µmmol/l
Gamma glutamyl transferase (GGT)	100 iu/l
Electrocardiogram (ECG)	right ventricular hypertrophy, peaked P waves
Chest radiograph	oligaemic peripheral lung fields

Which of the following therapies is most likely to improve long-term prognosis?

A	High-dose furosemide
B	Long-term oxygen therapy
C	Angiotensin-converting enzyme inhibitor
D	Regular venesection
E	Daily amoxicillin

7713

Submit

Previous Question | Skip Question

Calculator

Normal Values

© Pastest 2017

A 68-year-old man with a 10-year history of chronic obstructive pulmonary disease presents with a 6-month history of increasing exertional dyspnoea and fatigue. He also has a cough productive of yellow sputum, episodes of chest pain, nausea and anorexia. He stopped smoking 2 years ago. On examination he had a raised jugular venous pressure, right parasternal heave, a loud second heart sound and an ejection systolic murmur at the left second intercostal space. On chest auscultation he had scattered expiratory wheeze. He had pitting leg oedema.

Investigation results are below:

Haemoglobin (Hb)	18.0 g/dl
Na^+	135 mmol/l
Bilirubin	16 µmol/l
White cell count (WCC)	8.0 x 10^9/l
K^+	4.2 mmol/l
Alanine transferase (ALT)	50 iu/l
Platelets	220 x 10^9/l
Urea	4.6 mmol/l
Alkaline phosphatase	120 iu/l
Creatinine	110 µmmol/l
Gamma glutamyl transferase (GGT)	100 iu/l
Electrocardiogram (ECG)	right ventricular hypertrophy, peaked P waves
Chest radiograph	oligaemic peripheral lung fields

Which of the following therapies is most likely to improve long-term prognosis?

A	High-dose furosemide
B	Long-term oxygen therapy
C	Angiotensin-converting enzyme inhibitor
D	Regular venesection
E	Daily amoxicillin

Explanation

This man has developed cor pulmonale, which is defined as right-heart failure secondary to pulmonary hypertension. Causes include any chronic lung disease, pulmonary vascular disease, hypoventilation neuromuscular disorders and thoracic cage abnormalities. Long-term home oxygen therapy for at least 15 h per day can reduce hypoxia, which lowers pulmonary resistance and can improve symptoms and increase life expectancy. Diuretics can be used for right ventricular failure but care should be taken to avoid excessive fluid depletion. In contrast to left ventricular impairment, angiotensin-converting enzyme (ACE) inhibitors do not have any prognostic benefit and may in fact make matters worse.

7713

Rate this question:

Next Question

Previous Question | Tag Question

Feedback | End Session

Difficulty: Average

Peer Responses %

Session Progress

Responses Correct:	0
Responses Incorrect:	64
Responses Total:	64
Responses - % Correct:	0%

© Pastest 2017

A 76-year-old man with a 10-year history of chronic obstructive pulmonary disease was admitted to hospital with a 2-day history of progressively worsening dyspnoea and a cough productive of mucoid sputum. His wife stated that he is on home oxygen therapy for up to 12 h per day and home nebulisers. He is breathless on minimal exertion and rarely leaves the house. He has several exacerbations per year requiring hospital admission and these have become more frequent over the last few years, although he has never required ventilation before. He stopped smoking 2 years ago.

On examination he was acutely dyspnoeic with a respiratory rate of 32/min and was using accessory muscles of respiration. He was apyrexial, pulse 120/min and regular, blood pressure 182/92 mmHg. He was able to speak in broken sentences. Auscultation of his chest revealed generalised poor air entry and widespread expiratory wheeze.

His chest radiograph is shown below:

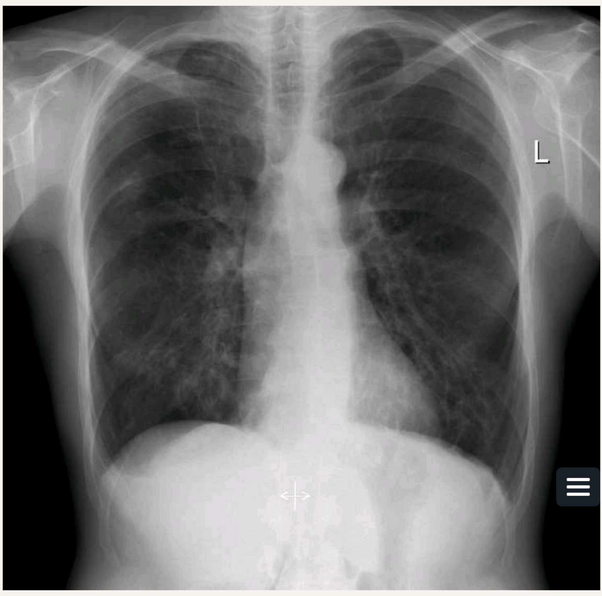

Arterial blood gases (on 24% oxygen via Venturi mask) were:

pH	7.32
$p_a(O_2)$	6.2 kPa
$p_a(CO_2)$	7.2 kPa

His inspired oxygen concentration was increased to 28% and he was treated with intravenous hydrocortisone, salbutamol and ipratropium nebulisers and an aminophylline infusion. After 1 h he had made little improvement and was tiring.

Repeat blood gases on 28% oxygen showed:

pH	7.26
$p_a(O_2)$	6.8 kPa
$p_a(CO_2)$	9.2 kPa

What is the next most appropriate step in management?

A	Immediate intubation and ventilation
B	Intravenous doxapram
C	Bilevel positive airway pressure (BiPAP)
D	Increase inspired oxygen concentration to 35%
E	Continuous positive airways pressure (CPAP)

9143

Submit

Previous Question | Skip Question

Calculator

Normal Values

© Pastest 2017

A 76-year-old man with a 10-year history of chronic obstructive pulmonary disease was admitted to hospital with a 2-day history of progressively worsening dyspnoea and a cough productive of mucoid sputum. His wife stated that he is on home oxygen therapy for up to 12 h per day and home nebulisers. He is breathless on minimal exertion and rarely leaves the house. He has several exacerbations per year requiring hospital admission and these have become more frequent over the last few years, although he has never required ventilation before. He stopped smoking 2 years ago.

On examination he was acutely dyspnoeic with a respiratory rate of 32/min and was using accessory muscles of respiration. He was apyrexial, pulse 120/min and regular, blood pressure 182/92 mmHg. He was able to speak in broken sentences. Auscultation of his chest revealed generalised poor air entry and widespread expiratory wheeze.

His chest radiograph is shown below:

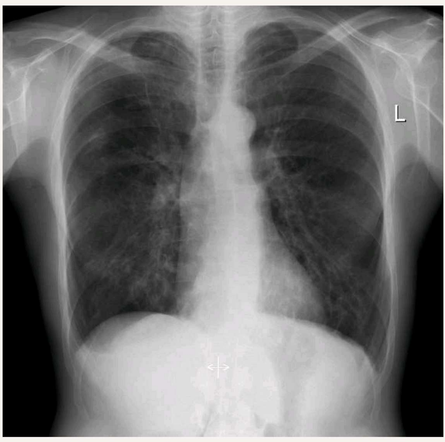

Arterial blood gases (on 24% oxygen via Venturi mask) were:

pH	7.32
$p_a(O_2)$	6.2 kPa
$p_a(CO_2)$	7.2 kPa

His inspired oxygen concentration was increased to 28% and he was treated with intravenous hydrocortisone, salbutamol and ipratropium nebulisers and an aminophylline infusion. After 1 h he had made little improvement and was tiring.

Repeat blood gases on 28% oxygen showed:

pH	7.26
$p_a(O_2)$	6.8 kPa
$p_a(CO_2)$	9.2 kPa

What is the next most appropriate step in management?

A	Immediate intubation and ventilation
B	Intravenous doxapram
C	Bilevel positive airway pressure (BiPAP)
D	Increase inspired oxygen concentration to 35%
E	Continuous positive airways pressure (CPAP)

Explanation

This man is in type 2 respiratory failure due to a severe exacerbation of chronic obstructive pulmonary disease (COPD), and is not improving despite maximal medical therapy. His poor premorbid functional status and lack of an acute precipitating event make him a poor candidate for the intensive therapy unit. Non-invasive ventilation is the best option in this situation and may be life saving, with respect to BiPAP vs CPAP, outcome evidence is much more widely available for BiPAP, which drives the correct answer here. It has been shown to reduce respiratory acidosis, increase clearance of secretions and re-expand collapsed lung segments. However, it is only suitable for patients who are conscious, co-operative and able to protect their airway. Doxapram is a respiratory stimulant and should only be used when BiPAP is unavailable or in the case of reduced respiratory drive due to sedatives or anaesthetic agents. Doxapram also has a number of contraindications, which include hypertension (relative contraindication), such that concomitant therapy and past medical history should be carefully reviewed prior to starting therapy.

9143

Rate this question:

Next Question

Previous Question | Tag Question

Feedback | End Session

Difficulty: Easy

Peer Responses %

Session Progress

Responses Correct:	0
Responses Incorrect:	65
Responses Total:	65
Responses - % Correct:	0%

© Pastest 2017

An acutely unwell 62-year-old man is brought to the emergency department by his wife. They had returned from holiday to Spain 3 days ago. Apart from some mild flu-like symptoms he had been otherwise well on returning to the UK. Over the last 24 h he had developed a severe headache, violent shivers and muscle pains. He also had some abdominal pain with several episodes of diarrhoea. He had no significant past medical history and was on no medication. He had consumed some seafood on holiday, but his wife had eaten the same dish and had no symptoms.

On examination he was confused and agitated with a fever of 40°C. His respiratory rate was 32/min, pulse 110/min, blood pressure 100/62 mmHg. His heart sounds were normal and he had right basal crepitations on chest auscultation. His abdomen was soft and non-specifically tender with scanty bowel sounds. There was no focal neurology.

Results of investigations are below:

Haemoglobin (Hb)	13.6 g/dl
White cell count (WCC)	12.0 × 10^9/l

Differential count:

Neutrophils	10.2 10^9/l
Lymphocytes	0.5 × 10^9/l
Monocytes	0.8 × 10^9/l
Eosinophils	0.4 × 10^9/l
Basophils	0.1 × 10^9/l
Platelets	380 × 10^9/l
Na^+	122 mmol/l
K^+	3.2 mmol/l
Urea	7.6 mmol/l
Gamma-glutamyl transferase (GGT)	65 IU/l
Creatinine	170 mol/l
Total Ca^{2+}	2.06 mmol/l
Bilirubin	16 mol/l
Alanine aminotransferase (ALT)	92 IU/l
Albumin	30 g/l
Alkaline phosphatase (ALP)	98 IU/l
Urinalysis	Blood +++, protein +
Chest radiograph	Patchy shadowing at right lower zone
Electrocardiogram (ECG)	Sinus tachycardia

What is the most likely causative organism?

A	*Legionella pneumophila*
B	*Mycoplasma pneumoniae*
C	*Coxiella burnetii* (Q fever)
D	*Salmonella typhi*
E	*Chlamydia pneumoniae*

9144

Submit

Previous Question | Skip Question

Calculator

Normal Values

© Pastest 2017

An acutely unwell 62-year-old man is brought to the emergency department by his wife. They had returned from holiday to Spain 3 days ago. Apart from some mild flu-like symptoms he had been otherwise well on returning to the UK. Over the last 24 h he had developed a severe headache, violent shivers and muscle pains. He also had some abdominal pain with several episodes of diarrhoea. He had no significant past medical history and was on no medication. He had consumed some seafood on holiday, but his wife had eaten the same dish and had no symptoms.

On examination he was confused and agitated with a fever of 40°C. His respiratory rate was 32/min, pulse 110/min, blood pressure 100/62 mmHg. His heart sounds were normal and he had right basal crepitations on chest auscultation. His abdomen was soft and non-specifically tender with scanty bowel sounds. There was no focal neurology.

Results of investigations are below:

Haemoglobin (Hb)	13.6 g/dl
White cell count (WCC)	12.0 × 10^9/l

Differential count:

Neutrophils	10.2 10^9/l
Lymphocytes	0.5 × 10^9/l
Monocytes	0.8 × 10^9/l
Eosinophils	0.4 × 10^9/l
Basophils	0.1 × 10^9/l
Platelets	380 × 10^9/l
Na^+	122 mmol/l
K^+	3.2 mmol/l
Urea	7.6 mmol/l
Gamma-glutamyl transferase (GGT)	65 IU/l
Creatinine	170 mol/l
Total Ca^{2+}	2.06 mmol/l
Bilirubin	16 mol/l
Alanine aminotransferase (ALT)	92 IU/l
Albumin	30 g/l
Alkaline phosphatase (ALP)	98 IU/l
Urinalysis	Blood +++, protein +
Chest radiograph	Patchy shadowing at right lower zone
Electrocardiogram (ECG)	Sinus tachycardia

What is the most likely causative organism?

A	*Legionella pneumophila*
B	*Mycoplasma pneumoniae*
C	*Coxiella burnetii* (Q fever)
D	*Salmonella typhi*
E	*Chlamydia pneumoniae*

Explanation

This man has the typical features of Legionnaire's disease. Legionnella infection is said to be the cause of between 1% and 5% of adult pneumonias. The organism is a small coccobacillus which is not seen on Gram staining and can only be cultured on special media. Infection is spread by the aerosol route and usually acquired from contaminated air-conditioning or shower systems in institutions such as hotels and hospitals. Investigations may show hyponatraemia, normal or slightly elevated white cell count with lymphopaenia, hypoalbuminaemia and raised liver enzymes. Chest X-ray may show multilobar involvement or a pleural effusion. Haematuria and renal failure can occur. Diagnosis is made by a fourfold increase in antibody titre or by a highly specific urine antigen test. Treatment is with a macrolide antibiotic e.g. clarithromycin. Ciprofloxacin and rifampicin can also be used in severely ill patients. Mortality is 15–30%, particularly in the elderly.

9144

Rate this question:

Next Question

Previous Question | Tag Question

Feedback | End Session

Difficulty: Easy

Peer Responses %

Session Progress

Responses Correct:	0
Responses Incorrect:	66
Responses Total:	66
Responses - % Correct:	0%

© Pastest 2017

A 32-year-old homosexual man who has been HIV positive for 5 years and started highly active anti-retroviral therapy several months ago presented with several days of malaise, rigors, a cough productive of blood-streaked green sputum and pleuritic chest pain. His latest CD4 count was 320 × 10^6/l, several weeks ago. On examination he was unwell, with a pyrexia of 39°C, pulse 110/min, blood pressure 100/70 mmHg, $S_a(O_2)$ 91% on air. On auscultation of his chest he had bronchial breathing and coarse crepitations at the left lower zone. His chest radiograph showed consolidation of the left lower lobe.

What is the most likely diagnosis?

A	*Pneumocystis jirovecii* pneumonia
B	Streptococcal pneumonia
C	Staphylococcal pneumonia
D	*Mycobacterium avium intacellulare* infection
E	Lymphoid interstitial pneumonitis

9145

Submit

Previous Question | Skip Question

Calculator

Normal Values

© Pastest 2017

A 32-year-old homosexual man who has been HIV positive for 5 years and started highly active anti-retroviral therapy several months ago presented with several days of malaise, rigors, a cough productive of blood-streaked green sputum and pleuritic chest pain. His latest CD4 count was 320 × 10^6/l, several weeks ago. On examination he was unwell, with a pyrexia of 39°C, pulse 110/min, blood pressure 100/70 mmHg, $S_a(O_2)$ 91% on air. On auscultation of his chest he had bronchial breathing and coarse crepitations at the left lower zone. His chest radiograph showed consolidation of the left lower lobe.

What is the most likely diagnosis?

A	*Pneumocystis jirovecii* pneumonia
B	Streptococcal pneumonia
C	Staphylococcal pneumonia
D	*Mycobacterium avium intacellulare* infection
E	Lymphoid interstitial pneumonitis

Explanation

B Streptococcal pneumonia

This man has a community-acquired pneumonia, 60–75% of which are caused by *Streptococcus pneumoniae*. Disseminated bacterial sepsis is common in HIV patients and may be seen in the early stages of infection, before a significant decline in the CD4 count.

A *Pneumocystis jirovecii* pneumonia

P. jirovecii (previously *carinii*) pneumonia and *Mycobacterium avium intracellulare* infection are AIDS-defining conditions and require a CD4 count <200 × 10^9/l to develop. PCP also usually develops as a dry cough with desaturation on exercise, and patchy interstitial shadowing on chest X-ray.

C Staphylococcal pneumonia

Staphylococcal pneumonia tends to occur post-influenza infection or in intravenous drug users, and causes cavitation and multiple lung abscesses. There is no indication of previous influenza as a driver for infection here.

D *Mycobacterium avium intacellulare* infection

Atypical mycobacterial infection, like PCP, occurs in patients with a significant fall in their CD4 count and is an AIDS defining condition.

E Lymphoid interstitial pneumonitis

Lymphoid interstitial pneumonitis is due to infiltration of the alveolar tissue by lymphocytes and plasma cells, and presents with dry cough, dyspnoea and reticulo-nodular shadowing on the chest X-ray. It is uncommon in adult but well described in paediatric HIV infection.

9145

Rate this question:

Next Question

Previous Question | Tag Question

Feedback | End Session

Difficulty: Average

Peer Responses %

Session Progress

Responses Correct:	0
Responses Incorrect:	67
Responses Total:	67
Responses - % Correct:	0%

© Pastest 2017

A 56-year-old man is referred to the endocrine clinic with an 18-month history of constant tiredness. He works as a taxi driver and on one occasion fell asleep at the wheel. He finds it difficult to concentrate during the day and has frequent morning headaches. His wife stated that he is restless and snores loudly at night and occasionally has 'choking' episodes. He has also had very poor libido recently. He is a smoker of 30 cigarettes per day and drinks 4 pints of lager every night. His only medication is an inhaler for 'bronchitis', and he has had a chronic cough with sputum over the last few years.
On examination he was a large man with coarse features and was clinically obese, with body mass index (BMI) of 35. His heart sounds were normal, there was some scattered wheezing in the chest and he had early pitting ankle oedema.

What would be the most practical investigation to establish the diagnosis?

A	Thyroid function tests
B	Overnight home sleep oximetry
C	Formal respiratory function tests
D	CT thorax
E	Epworth sleepiness score

9146

Submit

Previous Question Skip Question

Calculator

Normal Values

Blog About Pastest Contact Us Help

© Pastest 2017

A 56-year-old man is referred to the endocrine clinic with an 18-month history of constant tiredness. He works as a taxi driver and on one occasion fell asleep at the wheel. He finds it difficult to concentrate during the day and has frequent morning headaches. His wife stated that he is restless and snores loudly at night and occasionally has 'choking' episodes. He has also had very poor libido recently. He is a smoker of 30 cigarettes per day and drinks 4 pints of lager every night. His only medication is an inhaler for 'bronchitis', and he has had a chronic cough with sputum over the last few years.
On examination he was a large man with coarse features and was clinically obese, with body mass index (BMI) of 35. His heart sounds were normal, there was some scattered wheezing in the chest and he had early pitting ankle oedema.

What would be the most practical investigation to establish the diagnosis?

A	Thyroid function tests
B	Overnight home sleep oximetry
C	Formal respiratory function tests
D	CT thorax
E	Epworth sleepiness score

Explanation

B	Overnight home sleep oximetry

The diagnosis is obstructive sleep apnoea, which affects 1–2% of the population and is most commonly found in obese male smokers with a background of chronic obstructive pulmonary disease (COPD). Rarer causes include acromegaly, Cushing's disease, nasal deformities and tonsillar enlargement. Apnoea occurs when the walls of the pharynx collapse during sleep, which leads to hypoxia and increasingly strenuous respiratory efforts until the resistance is overcome. Apnoea can occur hundreds of times per night, resulting in reduction of REM sleep. The diagnosis can usually be made by a good history from the sleeping partner, supported by non-invasive oximetry performed at home. Full polysomnographic studies are rarely required for diagnosis but can be useful for research purposes. Management includes treating any underlying cause, weight reduction and avoidance of sedative drugs and alcohol. Continuous positive airway pressure (CPAP), which keeps the walls of the pharynx open, is the mainstay of treatment and can lead to a dramatic improvement in symptoms.

A	Thyroid function tests

Although this patient is obese, it's most likely this is related to his lifestyle rather than to any underlying hypothyroidism. Hence TFT is unlikely to be of value here.

C	Formal respiratory function tests

These may show evidence of obstructive lung disease and/or obesity hypoventilation syndrome, although this wouldn't prove or disprove obstructive sleep apnoea.

D	CT thorax

This may show early changes consistent with COPD, although this won't prove or disprove obstructive sleep apnoea.

E	Epworth sleepiness score

The Epworth sleepiness score is merely a pointer to daytime sleepiness associated with OSA; it isn't a confirmatory test.

9146

Rate this question:

Next Question

Previous Question	Tag Question
Feedback	End Session

Difficulty: Easy

Peer Responses %

Session Progress

Responses Correct:	0
Responses Incorrect:	68
Responses Total:	68
Responses - % Correct:	0%

© Pastest 2017

A 44-year-old man presented with a rash on his legs and feeling generally unwell with malaise, weight loss and fevers. He also had recently noticed some loss of sensation over the top of his right foot, with the foot dragging when he walked. He had been diagnosed with asthma by his general practitioner many years ago and used a salbutamol inhaler as required. He also had a constant watery nasal discharge, but no epistaxis. He was a non-smoker. On examination he had a low-grade pyrexia and scattered wheeze in his chest. Heart sounds were normal. His abdomen was soft and non-tender, with no masses. He had a purpuric rash on his lower limbs and several tender subcutaneous nodules on his forearms. He had a right foot drop but no other neurological abnormalities.

Investigations:

Hb	10.6 g/dl
WCC	10.9×10^9/l
PLT	390×10^9/l
Neutrophils	6.2×10^9/l
Eosinophils	2.2×10^9/l
Monocytes	1.6×10^9/l
Basophils	0.1×10^9/l
MCV	94 fl
ESR	82 mm/h
Na^+	120 mmol/l
K^+	4.2 mmol/l
ALP	80 IU/l
ALT	30 IU/l
Urea	5.2 mmol/l
GGT	42 IU/l
Bilirubin	14 mol/l
Creatinine	110 mol/l
Antinuclear antibody	-
Anti-neutrophil cytoplasmic antibody (pANCA)	+
Urinalysis	Normal
CXR	Patchy shadowing at hilar regions, small pleural effusion

What is the most likely diagnosis?

A	Systemic lupus erythematosus
B	Polyarteritis nodosa
C	Eosinophilic granulomatosis with polyangitis
D	Anti-GBM disease
E	Granulomatosis with polyangitis

9147

Submit

Previous Question | Skip Question

Calculator

Normal Values

© Pastest 2017

A 44-year-old man presented with a rash on his legs and feeling generally unwell with malaise, weight loss and fevers. He also had recently noticed some loss of sensation over the top of his right foot, with the foot dragging when he walked. He had been diagnosed with asthma by his general practitioner many years ago and used a salbutamol inhaler as required. He also had a constant watery nasal discharge, but no epistaxis. He was a non-smoker. On examination he had a low-grade pyrexia and scattered wheeze in his chest. Heart sounds were normal. His abdomen was soft and non-tender, with no masses. He had a purpuric rash on his lower limbs and several tender subcutaneous nodules on his forearms. He had a right foot drop but no other neurological abnormalities.

Investigations:

Hb	10.6 g/dl
WCC	10.9×10^9/l
PLT	390×10^9/l
Neutrophils	6.2×10^9/l
Eosinophils	2.2×10^9/l
Monocytes	1.6×10^9/l
Basophils	0.1×10^9/l
MCV	94 fl
ESR	82 mm/h
Na^+	120 mmol/l
K^+	4.2 mmol/l
ALP	80 IU/l
ALT	30 IU/l
Urea	5.2 mmol/l
GGT	42 IU/l
Bilirubin	14 mol/l
Creatinine	110 mol/l
Antinuclear antibody	-
Anti-neutrophil cytoplasmic antibody (pANCA)	+
Urinalysis	Normal
CXR	Patchy shadowing at hilar regions, small pleural effusion

What is the most likely diagnosis?

A Systemic lupus erythematosus

B Polyarteritis nodosa

C Eosinophilic granulomatosis with polyangitis

D Anti-GBM disease

E Granulomatosis with polyangitis

Explanation

C Eosinophilic granulomatosis with polyangitis

This man presents with the classic triad of asthma, eosinophilia and systemic vasculitis. There is usually a prodromal period for many years consisting of allergic rhinitis and late-onset asthma, which can be difficult to control.

The chest X-ray may show nodules, transient hilar lymphadenopathy and pulmonary infiltrates. There may also be pleural or pericardial effusions. Mononeuritis multiplex can occur. Anti-neutrophil cytoplasmic antibody (ANCA) is positive in approximately 40% of cases. Renal involvement is rare. Treatment is with high-dose corticosteroids, azathioprine or cyclophosphamide.

A Systemic lupus erythematosus

Although SLE is associated with an erythematous rash on sun-exposed areas, the eosinophilia, negative ANA and positive pANCA would be unusual for a diagnosis of lupus.

B Polyarteritis nodosa

pANCA is classically not positive in patients with PAN. In addition, the symptoms of significant asthma poorly responsive to conventional therapies, and eosinophilia, are inconsistent with a diagnosis of PAN.

D Anti-GBM disease

This presents with rapidly progressive pulmonary and renal disease, accompanied by haemoptysis and renal failure due to glomerulonephritis. Eosinophilia isn't a feature, nor is mononeuritis multiplex.

E Granulomatosis with polyangitis

This is associated with pulmonary and renal vasculitis with haemoptysis and a progressive rise in serum creatinine. There is usually sinusitis. cANCA rather than pANCA is more likely to be positive, and eosinophils are not elevated.

9147

Rate this question:

Next Question

Previous Question | Tag Question

Feedback | End Session

Peer Responses %

Session Progress

Responses Correct:	0
Responses Incorrect:	69
Responses Total:	69
Responses - % Correct:	0%

Blog About Pastest Contact Us Help

© Pastest 2017

A 62-year-old man presents with progressively increasingly dyspnoea over several months and a dry cough. He also had some malaise and arthralgia, but no other systemic symptoms. He is an ex-smoker who stopped 5 years ago. Apart from a small myocardial infarction 2 years ago and controlled hypertension, he has no other significant past medical history. He is a retired carpenter who used to work in a pine warehouse. He has no family history of respiratory disease, although he thinks his mother had hepatitis.

On examination he was dyspnoeic at rest with a respiratory rate of 24/min. He was centrally cyanosed and had finger clubbing. His heart sounds were normal. He had bi-basal fine end-inspiratory crepitations on chest auscultation. His jugular venous pressure was raised and he had early pitting ankle oedema. His GP has previously tried oral steroids with no significant response.

Investigation results are below:

Haemoglobin (Hb)	17 g/dl
White cell count (WCC)	6.0 × 10^9/l
Platelets	200 × 10^9/l
Erythrocyte sedimentation rate (ESR)	40 mm/h
Na^+	136 mmol/l
K^+	4.0 mmol/l
Gamma-glutamyl transferase(GGT)	44 IU/l
Alanine aminotransferase (ALT)	36 IU/l
Creatinine	110 mol/l
Alkaline phosphatase	90 IU/l
Bilirubin	14 mol/l
Urea	5.2 mmol/l
Antinuclear antibody	Positive
Rheumatoid factor	Weakly positive

High-resolution computed tomography (CT) of the chest is shown below:

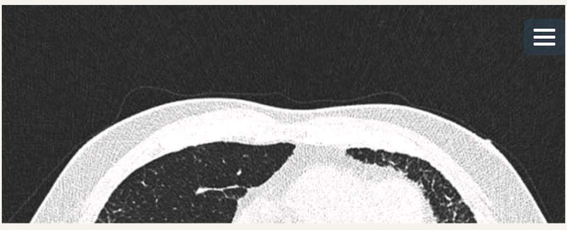

What is the most likely diagnosis?

A	Congestive cardiac failure
B	Idiopathic pulmonary fibrosis
C	Extrinsic allergic alveolitis
D	Rheumatoid lung fibrosis
E	Systemic lupus erythematosis

9148

Submit

Previous Question | Skip Question

Calculator

Normal Values

© Pastest 2017

A 62-year-old man presents with progressively increasingly dyspnoea over several months and a dry cough. He also had some malaise and arthralgia, but no other systemic symptoms. He is an ex-smoker who stopped 5 years ago. Apart from a small myocardial infarction 2 years ago and controlled hypertension, he has no other significant past medical history. He is a retired carpenter who used to work in a pine warehouse. He has no family history of respiratory disease, although he thinks his mother had hepatitis.

On examination he was dyspnoeic at rest with a respiratory rate of 24/min. He was centrally cyanosed and had finger clubbing. His heart sounds were normal. He had bi-basal fine end-inspiratory crepitations on chest auscultation. His jugular venous pressure was raised and he had early pitting ankle oedema. His GP has previously tried oral steroids with no significant response.

Investigation results are below:

Haemoglobin (Hb)	17 g/dl
White cell count (WCC)	6.0 × 10^9/l
Platelets	200 × 10^9/l
Erythrocyte sedimentation rate (ESR)	40 mm/h
Na^+	136 mmol/l
K^+	4.0 mmol/l
Gamma-glutamyl transferase(GGT)	44 IU/l
Alanine aminotransferase (ALT)	36 IU/l
Creatinine	110 mol/l
Alkaline phosphatase	90 IU/l
Bilirubin	14 mol/l
Urea	5.2 mmol/l
Antinuclear antibody	Positive
Rheumatoid factor	Weakly positive

High-resolution computed tomography (CT) of the chest is shown below:

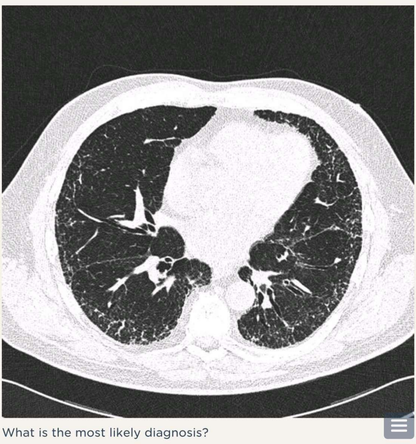

What is the most likely diagnosis?

A	Congestive cardiac failure
B	Idiopathic pulmonary fibrosis
C	Extrinsic allergic alveolitis
D	Rheumatoid lung fibrosis
E	Systemic lupus erythematosis

Explanation

The answer is Idiopathic pulmonary fibrosis -

Idiopathic pulmonary fibrosis is a disorder of unknown aetiology causing diffuse pulmonary fibrosis. It has an incidence of 6–10/100 000 per year and is most common in middle-aged male smokers. There is some association with exposure to metal or wood dusts. Respiratory function tests show a restrictive defect with reduced transfer factor. Rheumatoid factor and antinuclear antibody are positive in 30–50% of cases. The diagnosis can usually be made by a combination of clinical features, respiratory function tests and high-resolution computed tomography which shows honeycombing and reticular opacities. Histological confirmation by transbronchial biopsy is occasionally required. Treatment is with steroids, azathioprine or cyclophosphamide, although many patients are steroid unresponsive. Median survival is 5 years. Lung transplantation is occasionally indicated.

There are no significant symptoms of joint disease to fit with a diagnosis of rheumatoid, and no rashes to support a diagnosis of SLE. In extrinsic allergic alveolitis we are usually presented with a precipitins result as a pointer to the underlying diagnosis. The CT appearance is incompatible with a diagnosis of congestive cardiac failure.

9148

Rate this question:

Next Question

Previous Question | Tag Question

Feedback | End Session

Difficulty: Easy

Peer Responses %

Session Progress

Responses Correct:	0
Responses Incorrect:	70
Responses Total:	70
Responses - % Correct:	0%

Blog About Pastest Contact Us Help

© Pastest 2017

A 42-year-old man presented with massive haemoptysis. He smokes 20 cigarettes per day and admits to a chronic cough with night sweats and gradual weight loss over the past 6–9 months. He has not consulted medical services as he is currently living rough.

His chest radiograph is shown below:

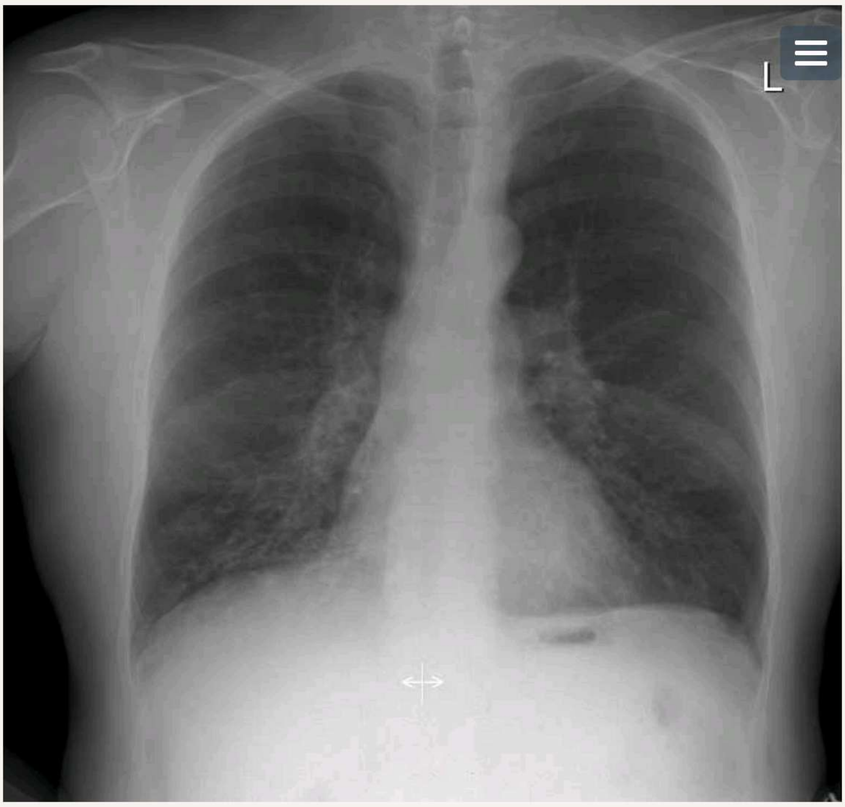

What is the underlying cause for the haemoptysis?

A	Granulomatosis with polyangitis
B	Pulmonary tuberculosis
C	Aspergilloma
D	Bronchiectasis
E	Anti-GBM disease

9149

Submit

Previous Question | Skip Question

Calculator

Normal Values

© Pastest 2017

A 42-year-old man presented with massive haemoptysis. He smokes 20 cigarettes per day and admits to a chronic cough with night sweats and gradual weight loss over the past 6–9 months. He has not consulted medical services as he is currently living rough.

His chest radiograph is shown below:

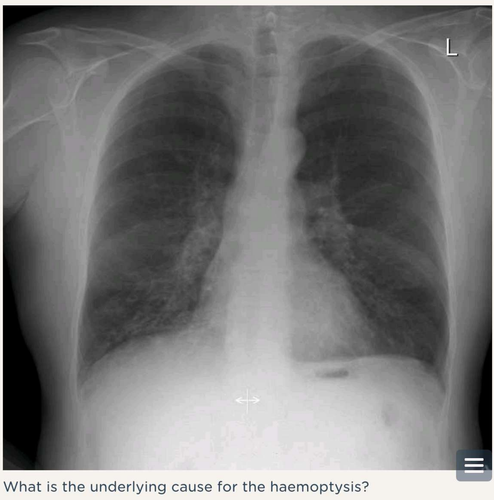

What is the underlying cause for the haemoptysis?

A	Granulomatosis with polyangitis
B	Pulmonary tuberculosis
C	Aspergilloma
D	Bronchiectasis
E	Anti-GBM disease

Explanation

D	Bronchiectasis

The chest X-ray shows the typical appearance of bronchiectasis, with dilated, thickened, oedematous bronchial walls (tramline and ring shadows: see expanded radiograph below). Sometimes multiple, fluid-filled cysts are also seen. Surgery for partial lung resection is usually avoided in bronchiectasis, but might be considered where there is massive haemoptysis and localised infection. Other causes of massive haemoptysis include bronchial carcinoma, TB and cavitating lung lesions (e.g. aspergilloma).

A	Granulomatosis with polyangitis

This is associated with patchy interstitial shadowing rather than the features of bronchiectasis seen here.

B	Pulmonary tuberculosis

In tuberculosis, evidence of upper zone fibrosis with potential calcification and hilar lymphadenopathy would be expected.

C	Aspergilloma

Aspergillomas are ball-shaped lesions which occur within an old cavity, usually from previous tuberculosis infection.

E	Anti-GBM disease

Like granulomatosis with polyangitis, this is associated with pulmonary haemorrhage and consequent patchy interstitial shadowing on CXR.

9149

Rate this question:

Next Question

Previous Question | Tag Question

Feedback | End Session

Difficulty: Average

Peer Responses %

Session Progress

Responses Correct:	0
Responses Incorrect:	71
Responses Total:	71
Responses - % Correct:	0%

© Pastest 2017

A 52-year-old farmer presented with a 5-month history of progressively worsening exertional dyspnoea and a persistent dry cough. He also described 6 kg weight loss and general malaise over this time period. He had no significant past medical history or family history. He was an ex-smoker who stopped 10 years ago and drank 10–12 units of alcohol per week.

On examination he was dyspnoeic on minimal exertion, but not at rest. He was not cyanosed and there was no finger clubbing. He had a low-grade pyrexia of 37.4°C. His heart sounds were normal, jugular venous pressure was not raised and there was no peripheral oedema. He had bilateral fine basal crepitations on chest auscultation. Abdominal and neurological examinations were unremarkable.

Investigations:

Hb	11.2 g/dl
WCC	12.4× 10^9/l
PLT	420 × 10^9/l
Na^+	140 mmol/l
K^+	3.6 mmol/l
Creatinine	110 mol/l
Ca^{2+}	2.42 mmol/l
Bilirubin	14 µmol/l
Urea	6.1 mmol/l
ALT	32 IU/l
ALP	92 IU/l
GGT	44 IU/l
MCV	92 fl
ESR	60 mm/h
Pulmonary function tests	Restrictive defect, reduced gas transfer

A high-resolution computed tomography (CT) scan of the thorax is shown below:

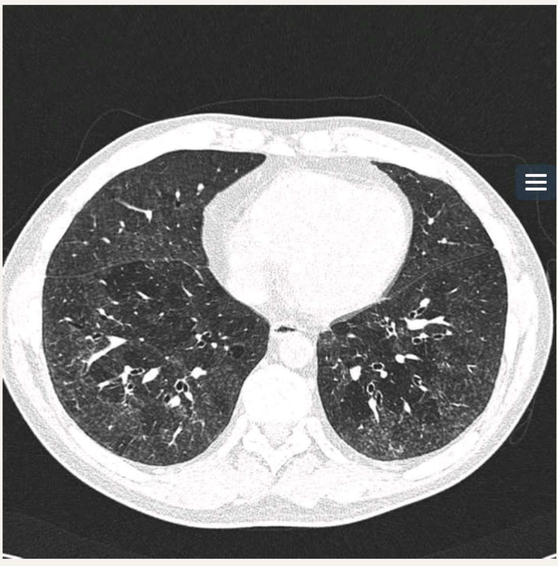

What is the most likely diagnosis?

A	Sarcoidosis
B	Allergic bronchopulmonary aspergillosis
C	Idiopathic pulmonary fibrosis
D	Extrinsic allergic alveolitis
E	Pulmonary tuberculosis

9150

Submit

Previous Question | Skip Question

Calculator

Normal Values

© Pastest 2017

A 52-year-old farmer presented with a 5-month history of progressively worsening exertional dyspnoea and a persistent dry cough. He also described 6 kg weight loss and general malaise over this time period. He had no significant past medical history or family history. He was an ex-smoker who stopped 10 years ago and drank 10–12 units of alcohol per week.

On examination he was dyspnoeic on minimal exertion, but not at rest. He was not cyanosed and there was no finger clubbing. He had a low-grade pyrexia of 37.4°C. His heart sounds were normal, jugular venous pressure was not raised and there was no peripheral oedema. He had bilateral fine basal crepitations on chest auscultation. Abdominal and neurological examinations were unremarkable.

Investigations:

Hb	11.2 g/dl
WCC	12.4× 10^9/l
PLT	420 × 10^9/l
Na^+	140 mmol/l
K^+	3.6 mmol/l
Creatinine	110 mol/l
Ca^{2+}	2.42 mmol/l
Bilirubin	14 μmol/l
Urea	6.1 mmol/l
ALT	32 IU/l
ALP	92 IU/l
GGT	44 IU/l
MCV	92 fl
ESR	60 mm/h
Pulmonary function tests	Restrictive defect, reduced gas transfer

A high-resolution computed tomography (CT) scan of the thorax is shown below:

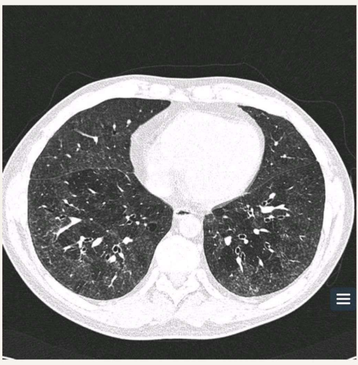

What is the most likely diagnosis?

A	Sarcoidosis
B	Allergic bronchopulmonary aspergillosis
C	Idiopathic pulmonary fibrosis
D	Extrinsic allergic alveolitis
E	Pulmonary tuberculosis

Explanation

D	Extrinsic allergic alveolitis

This man has chronic extrinsic allergic alveolitis (EAA). This is caused by inhaled allergens provoking a hypersensitivity reaction in the lungs and resulting in diffuse inflammation involving the small airways and alveoli. In the chronic form, lymphocytic and giant cell infiltration can eventually lead to pulmonary fibrosis. Typical allergens include microbial spores, especially *Micropolyspora faeni* in mouldy hay, which causes farmer's lung, and avian proteins causing bird fancier's lung. The diagnosis can be made by a combination of imaging, respiratory function tests, serum precipitins and bronchoalveolar lavage. The computed tomography (CT) scan shows multiple small, ill-defined nodules throughout both lungs, with areas of ground-glass opacity in the basal segments. Treatment consists of avoidance of the causative allergen and long-term corticosteroid therapy. In some patients progression to end-stage fibrosis and respiratory failure cannot be prevented.

A	Sarcoidosis

Sarcoidosis is associated with progressive pulmonary fibrosis if there is marked disease activity which is left untreated, but other features associated with active sarcoid, such as erythema nodosum and elevated serum calcium, appear absent here.

B	Allergic bronchopulmonary aspergillosis

ABPA is associated with exaggerated asthma symptoms that do not respond to inhaled therapies, rather than the restrictive lung picture seen here.

C	Idiopathic pulmonary fibrosis

Idiopathic pulmonary fibrosis in this case is a diagnosis of exclusion. The occupation as a farmer means that disease related to exposure to inhaled allergens should be excluded first.

E	Pulmonary tuberculosis

There is no suggestion of TB exposure, and the CT image is suggestive of fibrosis rather than showing any sign of focal infection.

9150

Rate this question:

Next Question

Previous Question | Tag Question

Feedback | End Session

Difficulty: Average

Peer Responses %

Session Progress

Responses Correct:	0
Responses Incorrect:	72
Responses Total:	72
Responses - % Correct:	0%

Blog About Pastest Contact Us Help

© Pastest 2017

This 66-year-old man presented with several months history of dyspnoea and chest pain which has not responded to inhalers or to medication for angina. He is a retired boilermaker, who smoked 40 cigarettes per day until 4 years ago. On examination his BP is 152/92, with pulse 80 and regular. There is wheeze on auscultation of the chest, and pitting oedema of both ankles.

His chest radiograph is shown below.

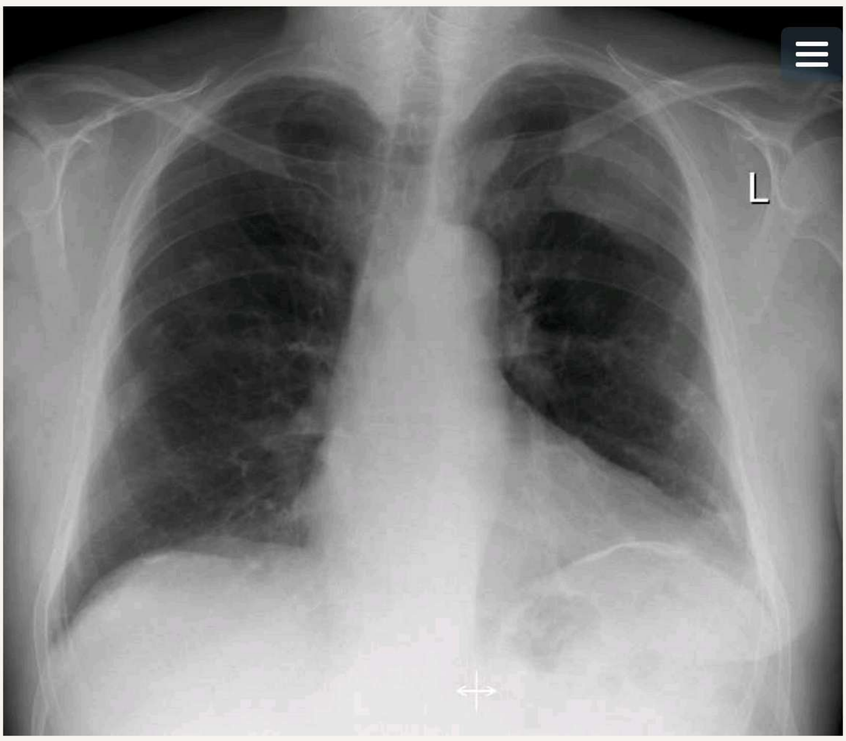

What is the most likely cause for the main abnormalities shown?

A	Cigarette smoking
B	Tuberculosis
C	Asbestos exposure
D	Silica exposure
E	Previous trauma

9151

Submit

Previous Question | Skip Question

Calculator

Normal Values

© Pastest 2017

This 66-year-old man presented with several months history of dyspnoea and chest pain which has not responded to inhalers or to medication for angina. He is a retired boilermaker, who smoked 40 cigarettes per day until 4 years ago. On examination his BP is 152/92, with pulse 80 and regular. There is wheeze on auscultation of the chest, and pitting oedema of both ankles.

His chest radiograph is shown below.

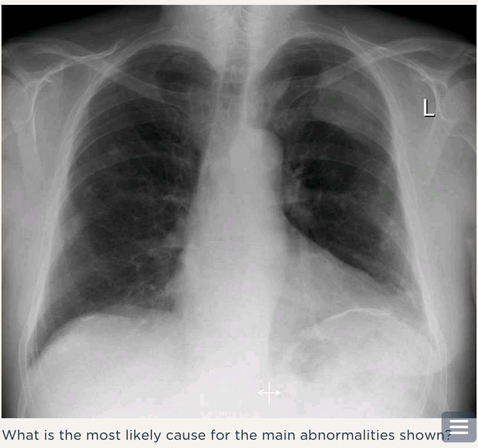

What is the most likely cause for the main abnormalities shown?

A	Cigarette smoking
B	Tuberculosis
C	Asbestos exposure
D	Silica exposure
E	Previous trauma

Explanation

C Asbestos exposure

The chest radiograph shows a mesothelioma at the left apex which is invading the underlying rib (see expanded radiograph, below). There are also calcified pleural plaques on the surface of both hemi-diaphragms. These appearances are consistent with asbestos exposure. Extensive occupational history is essential to establish any entitlement to compensation, as mesothelioma can develop up to 40 years after the initial exposure (often presenting with a unilateral pleural effusion). It is rarely suitable for surgical resection and is not responsive to chemotherapy. Palliative radiotherapy may be indicated. The prognosis is extremely poor, with an average survival of 1–2 years from diagnosis.

A Cigarette smoking

Cigarette smoking could not account for the mesothelioma seen in the left upper zone on CXR, nor the calcified pleural plaques.

B Tuberculosis

This leads to fibrotic changes and lymphadenopathy, but could not account for the left upper zone lesion or the calcified plaques seen here.

D Silica exposure

This leads to 'eggshell' calcification rather than pleural plaques, and is not associated with mesothelioma.

E Previous trauma

Previous trauma is more likely to be associated with evidence of old rib fractures and calcification, rather than the pleural changes seen here. It would also not account for the mesothelioma.

9151

Rate this question:

Next Question

Previous Question | Tag Question

Feedback | End Session

Difficulty: Average

Peer Responses %

Session Progress

Responses Correct:	0
Responses Incorrect:	73
Responses Total:	73
Responses - % Correct:	0%

© Pastest 2017

A 58-year-old man presented to hospital with a 12 h history of acute, severe epigastric pain which radiated to the back, and profuse vomiting. He had a long history of alcohol excess and admitted to a drinking binge 24 h prior to the onset of pain. He also smoked 30 cigarettes per day. His past medical history includes stable angina, hypertension and several admissions to the Emergency Department with alcohol-related problems.
On examination he was unwell, clammy and distressed with pain. He had a pyrexia of 38°C, pulse 120/min and regular, blood pressure 92/60 mmHg, Sa(O_2) 91% on air. Heart sounds were normal, with few basal crepitations on chest auscultation. He was very tender in the upper abdomen, with rebound and guarding and absent bowel sounds.

Investigations:

Hb	12.8 g/dl
WCC	21.0 × 10^9/l
PLT	140 × 10^9/l
Na^+	142 mmol/l
K^+	3.7 mmol/l
Creatinine	140 mol/l
MCV	106 fl
Ca^{2+}	1.96 mmol/l
Bilirubin	19 mol/l
ALT	50 IU/l
Urea	6.2 mmol/l
ALP	120 IU/l
GGT	110 IU/l
INR	1.1
Glucose	11.0 mmol/l
Amylase	1320 IU/l
CRP	350 mg/l
ECG	Sinus tachycardia, no acute changes
CXR	Patchy shadowing lower zones, no free air under diaphragm

Arterial blood gases (on air):

pH	7.160
$p_a(O_2)$	7.8 kPa
$p_a(CO_2)$	3.2 kPa

He was treated with oxygen, intravenous fluids and antibiotics and opiate analgesia. However, 24 h later, he had not improved and was getting progressively more breathless and hypoxic.

His repeat chest radiograph is shown below.

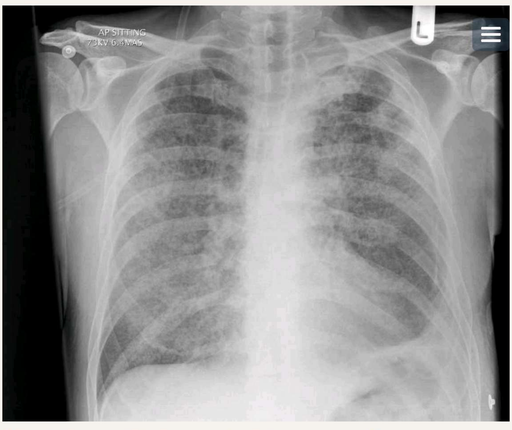

What is the most likely cause for this appearance?

A	Acute respiratory distress syndrome (ARDS)
B	Bilateral hospital-acquired pneumonia
C	Cardiogenic pulmonary oedema
D	Pulmonary haemorrhage
E	Fat embolism

9152

Submit

Previous Question | Skip Question

Calculator

Normal Values

© Pastest 2017

A 58-year-old man presented to hospital with a 12 h history of acute, severe epigastric pain which radiated to the back, and profuse vomiting. He had a long history of alcohol excess and admitted to a drinking binge 24 h prior to the onset of pain. He also smoked 30 cigarettes per day. His past medical history includes stable angina, hypertension and several admissions to the Emergency Department with alcohol-related problems.
On examination he was unwell, clammy and distressed with pain. He had a pyrexia of 38°C, pulse 120/min and regular, blood pressure 92/60 mmHg, $Sa(O_2)$ 91% on air. Heart sounds were normal, with few basal crepitations on chest auscultation. He was very tender in the upper abdomen, with rebound and guarding and absent bowel sounds.

Investigations:

Hb	12.8 g/dl
WCC	21.0 × 10^9/l
PLT	140 × 10^9/l
Na^+	142 mmol/l
K^+	3.7 mmol/l
Creatinine	140 mol/l
MCV	106 fl
Ca^{2+}	1.96 mmol/l
Bilirubin	19 mol/l
ALT	50 IU/l
Urea	6.2 mmol/l
ALP	120 IU/l
GGT	110 IU/l
INR	1.1
Glucose	11.0 mmol/l
Amylase	1320 IU/l
CRP	350 mg/l
ECG	Sinus tachycardia, no acute changes
CXR	Patchy shadowing lower zones, no free air under diaphragm

Arterial blood gases (on air):

pH	7.160
$p_A(O_2)$	7.8 kPa
$p_A(CO_2)$	3.2 kPa

He was treated with oxygen, intravenous fluids and antibiotics and opiate analgesia. However, 24 h later, he had not improved and was getting progressively more breathless and hypoxic.

His repeat chest radiograph is shown below.

What is the most likely cause for this appearance?

A	Acute respiratory distress syndrome (ARDS)
B	Bilateral hospital-acquired pneumonia
C	Cardiogenic pulmonary oedema
D	Pulmonary haemorrhage
E	Fat embolism

Explanation

A	Acute respiratory distress syndrome (ARDS)

This man has developed ARDS as a complication of severe acute pancreatitis. It is defined as acute respiratory failure with non-cardiogenic pulmonary oedema secondary to severe pulmonary or systemic illness, and may be associated with multi-organ failure. The most common cause is sepsis. There is increased permeability of the pulmonary micro-circulation due to inflammation causing leakage of fluid into the lungs. Later features include pulmonary vasoconstriction and hypertension secondary to hypoxia, and lung exudates which lead to reduced compliance. ARDS is always managed on an Intensive Care Unit. Supportive measures include positive-pressure ventilation, circulatory support with inotropes and treatment of sepsis. Inhaled nitrogen oxide and haemofiltration can also be used. Mortality is currently around 20–30%.

B	Bilateral hospital-acquired pneumonia

The time course is too short to fit with hospital-acquired pneumonia, and the patchy opacification versus lobar changes would be unusual for acute pneumonia.

C	Cardiogenic pulmonary oedema

Cardiogenic pulmonary oedema is a possible differential, although the proximity to acute pancreatitis is more likely to be associated with ARDS, and the lower lobe changes are more consistent with ARDS than pulmonary oedema.

D	Pulmonary haemorrhage

Pulmonary haemorrhage isn't associated with pancreatitis, although it is associated with CXR changes similar to those seen here.

E	Fat embolism

Fat embolism is associated with acute-onset shortness of breath, and is usually linked to repair or displacement of a long bone fracture.

9152

Rate this question:

Next Question

Previous Question | Tag Question

Feedback | End Session

Difficulty: Average

Peer Responses %

Session Progress

Responses Correct:	0
Responses Incorrect:	74
Responses Total:	74
Responses - % Correct:	0%

Blog About Pastest Contact Us Help

© Pastest 2017

A 68-year-old retired teacher presents with a 3-month history of recurrent haemoptysis. She had not sought medical advice at first as it had only been tiny, but the last few times there was a large amount of blood, which alarmed her. She had also noticed a persistent cough with some malaise and weight loss. She had a past medical history of tuberculosis when aged 19 years. She was an ex-smoker who stopped 15 years ago and did not drink alcohol. Physical examination was unremarkable.

The chest radiograph is shown below:

What is the most likely diagnosis?

A	Apical lung carcinoma
B	Aspergilloma
C	Reactivation of pulmonary tuberculosis
D	Lung abscess
E	Mesothelioma

9153

Submit

Previous Question | Skip Question

Calculator

Normal Values

© Pastest 2017

A 68-year-old retired teacher presents with a 3-month history of recurrent haemoptysis. She had not sought medical advice at first as it had only been tiny, but the last few times there was a large amount of blood, which alarmed her. She had also noticed a persistent cough with some malaise and weight loss. She had a past medical history of tuberculosis when aged 19 years. She was an ex-smoker who stopped 15 years ago and did not drink alcohol. Physical examination was unremarkable.

The chest radiograph is shown below:

What is the most likely diagnosis?

A	Apical lung carcinoma
B	Aspergilloma
C	Reactivation of pulmonary tuberculosis
D	Lung abscess
E	Mesothelioma

Explanation

This is a ball of Aspergillus fungus which forms inside an area of damaged lung tissue, most commonly secondary to TB, but occasionally bronchiectasis, neoplasm or abscess cavity. The chest X-ray typically shows a round opacity in the upper zone, with a surrounding halo of air. It is usually asymptomatic, but may cause massive haemoptysis. Treatment is usually surgical excision of the affected lung segment. Other diseases caused by Aspergillus fumigatus are allergic bronchopulmonary aspergillosis and invasive aspergillosis.

9153

Rate this question:

Next Question

Previous Question | Tag Question

Feedback | End Session

Difficulty: Average

Peer Responses %

Session Progress

Responses Correct:	0
Responses Incorrect:	75
Responses Total:	75
Responses - % Correct:	0%

© Pastest 2017

This high-resolution computed tomography (CT) scan is from a 42-year-old man with chronic dyspnoea and cough. PaO_2 is 8.9 kPa on air on arterial blood gas testing.

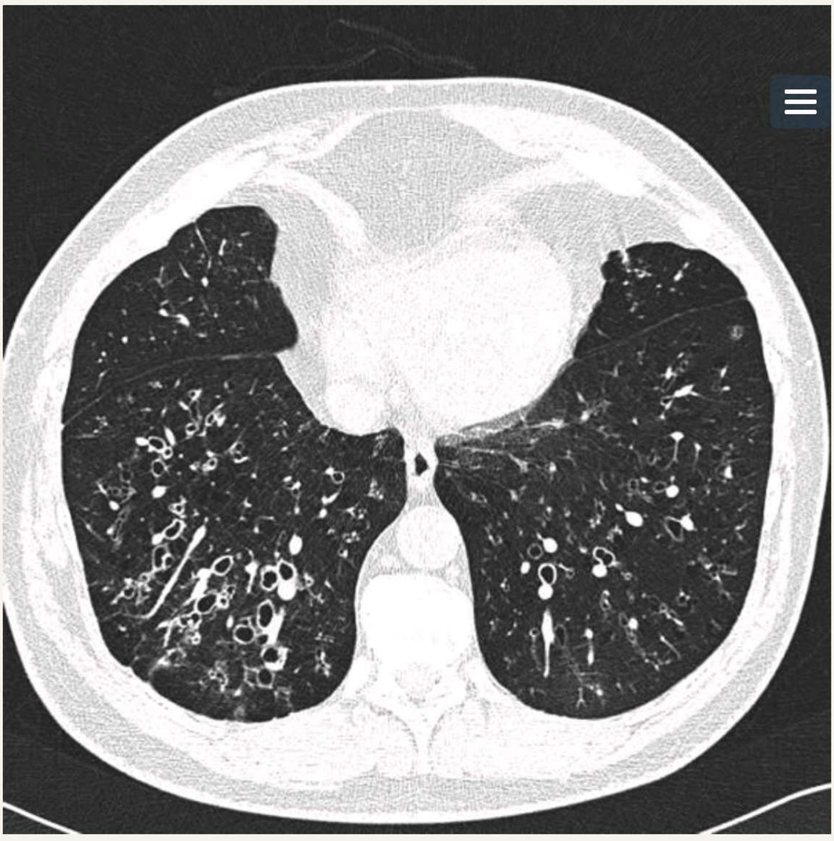

What is the most appropriate management strategy for this condition?

A	Oral corticosteroids
B	Antibiotics and regular postural drainage
C	Long-term home oxygen therapy
D	Intravenous cyclophosphamide
E	Anti-mycobacterial therapy

9154

Submit

Previous Question | Skip Question

Calculator

Normal Values

© Pastest 2017

This high-resolution computed tomography (CT) scan is from a 42-year-old man with chronic dyspnoea and cough. PaO_2 is 8.9 kPa on air on arterial blood gas testing.

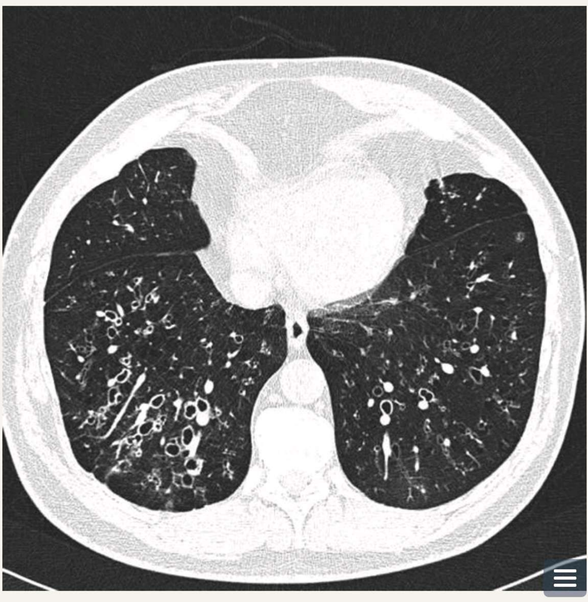

What is the most appropriate management strategy for this condition?

A	Oral corticosteroids
B	Antibiotics and regular postural drainage
C	Long-term home oxygen therapy
D	Intravenous cyclophosphamide
E	Anti-mycobacterial therapy

Explanation

This computed tomography (CT) scan shows the typical appearance of bronchiectasis, with dilated, thickened bronchi. Causes of this condition include cystic fibrosis, post-infective TB, immune deficiency and Kartagener's syndrome. Management includes daily postural drainage, antibiotic therapy for infective exacerbations, which should be guided by sputum culture, and bronchodilators. Surgical resection for localised areas of bronchiectasis is rarely indicated. Heart lung transplantation is an option in end stage disease with cor pulmonale. Colonisation with Pseudomonas aeruginosa is a common problem. Complications of bronchiectasis include massive haemoptysis, empyema, pneumothorax and metastatic infections (e.g. brain abscess).

9154

Rate this question:

Next Question

Previous Question | Tag Question

Feedback | End Session

Difficulty: Average

Peer Responses %

Session Progress

Responses Correct:	0
Responses Incorrect:	76
Responses Total:	76
Responses - % Correct:	0%

© Pastest 2017

A 28-year-old woman with mild asthma since childhood attends the chest clinic. Her last appointment was 6 months ago, at which time her symptoms were well controlled on inhaled beclomethasone 400 µg twice per day with occasional use of her salbutamol inhaler when required. She now describes worsening of her symptoms over the last few weeks, with a dry cough and wheeze, particularly at night. She had also noticed some morning dipping of her peak flow readings. She otherwise feels systemically well. She reports two episodes of oral thrush that she thinks were related to her inhaled steroids.

On examination she was mildly dyspnoeic, but able to speak in full sentences. She was apyrexial, pulse 72/min, blood pressure 120/82 mmHg, respiratory rate 16/min. She had scattered expiratory wheeze in her chest, with good air entry bilaterally. Her peak expiratory flow rate in clinic was 70% that of predicted.

What is the next most appropriate step in management?

A	Oral theophylline
B	Monteleukast
C	Increase inhaled beclomethasone to 800 mcg BD
D	Add inhaled long-acting beta-2 agonist therapy
E	Home nebuliser for bronchodilation

9155

Submit

Previous Question Skip Question

Calculator

Normal Values

Blog About Pastest Contact Us Help

© Pastest 2017

A 28-year-old woman with mild asthma since childhood attends the chest clinic. Her last appointment was 6 months ago, at which time her symptoms were well controlled on inhaled beclomethasone 400 µg twice per day with occasional use of her salbutamol inhaler when required. She now describes worsening of her symptoms over the last few weeks, with a dry cough and wheeze, particularly at night. She had also noticed some morning dipping of her peak flow readings. She otherwise feels systemically well. She reports two episodes of oral thrush that she thinks were related to her inhaled steroids.

On examination she was mildly dyspnoeic, but able to speak in full sentences. She was apyrexial, pulse 72/min, blood pressure 120/82 mmHg, respiratory rate 16/min. She had scattered expiratory wheeze in her chest, with good air entry bilaterally. Her peak expiratory flow rate in clinic was 70% that of predicted.

What is the next most appropriate step in management?

A	Oral theophylline
B	Monteleukast
C	Increase inhaled beclomethasone to 800 mcg BD
D	Add inhaled long-acting beta-2 agonist therapy
E	Home nebuliser for bronchodilation

Explanation

D	Add inhaled long-acting beta-2 agonist therapy

This patient is poorly controlled on a moderate dose of inhaled corticosteroids. Given the episodes of oral thrush she has suffered, adding inhaled long acting beta agonist is preferred to increasing the total dose of inhaled corticosteroid.

A	Oral theophylline

Providing the inhaler technique is adequate, there is little incremental benefit to be gained from oral beta-agonist therapy in this situation.

B	Monteleukast

Monteleukast is considered in patients where control isn't gained on high-dose inhaled corticosteroids or the combination of mid-dose corticosteroids and inhaled long-acting beta-agonist.

C	Increase inhaled beclomethasone to 800 mcg BD

Given her two previous episodes of oral candida, adding a LABA is preferable to increasing the inhaled steroid dose at this point.

E	Home nebuliser for bronchodilation

Providing the inhaler technique is appropriate, there is little incremental benefit from moving to home nebulisers, at significant extra acquisition cost.

9155

Rate this question:

Next Question

Previous Question | Tag Question

Feedback | End Session

Difficulty: Easy

Peer Responses %

Session Progress

Responses Correct:	0
Responses Incorrect:	77
Responses Total:	77
Responses - % Correct:	0%

© Pastest 2017

A 21-year-old man presents with a 3-month history of progressive wheeze and dyspnoea. Over the last few weeks, he has been coughing up thick, rubbery 'plugs' of mucus. There is no haemoptysis. He has a background of mild asthma, which was well controlled until a few months ago and eczema. He has had recurrent chest infections recently, requiring several courses of antibiotics from his general practitioner, and he attributes this to the damp autumn weather. He also has a feeling of general malaise. He had been more acutely short of breath for the last few days. On examination he was dyspnoeic at rest, but not cyanosed. His temperature was 37.8°C, pulse 100/min, blood pressure 132/86 mmHg, $S_a(O_2)$ 94% on air, respiratory rate 22/min. His heart sounds were normal. On auscultation of his chest he had widespread expiratory wheeze, with some coarse crepitations in the mid-zones and reduced air entry in the right lower zone. Abdominal and neurological examinations were unremarkable.

Investigation results are below:

Haemoglobin (Hb)	15 g/dl
White cell count(WCC)	13.1 × 10^9/l

Differential count:

Neutrophils	9.2 × 10^9/l
Lymphocytes	2.2 × 10^9/l
Monocytes	0.2 × 10^9/l
Eosinophils	1.4 × 10^9/l
Basophils	0.1 × 10^9/l
Platelets	390 × 10^9/l
Na^+	138 mmol/l
Bilirubin	14 mol/l
K^+	4.2 mmol/l
Alkaline phosphatase	90 IU/l
Urea	5.2 mmol/l
Alanine aminotransferase (ALT)	32 IU/l
Creatinine	100 mol/l
Gamma-glutamyl transferase (GGT)	30 IU/l
Chest radiograph	Patchy infiltrates throughout both lung fields

What is the most likely diagnosis?

A	Cystic fibrosis
B	Invasive pulmonary aspergillosis
C	Cryptogenic eosinophilic pneumonia
D	Churg–Strauss syndrome
E	Allergic bronchopulmonary aspergillosis (ABPA)

9156

Submit

Previous Question | Skip Question

Calculator

Normal Values

© Pastest 2017

A 21-year-old man presents with a 3-month history of progressive wheeze and dyspnoea. Over the last few weeks, he has been coughing up thick, rubbery 'plugs' of mucus. There is no haemoptysis. He has a background of mild asthma, which was well controlled until a few months ago and eczema. He has had recurrent chest infections recently, requiring several courses of antibiotics from his general practitioner, and he attributes this to the damp autumn weather. He also has a feeling of general malaise. He had been more acutely short of breath for the last few days. On examination he was dyspnoeic at rest, but not cyanosed. His temperature was 37.8°C, pulse 100/min, blood pressure 132/86 mmHg, $S_a(O_2)$ 94% on air, respiratory rate 22/min. His heart sounds were normal. On auscultation of his chest he had widespread expiratory wheeze, with some coarse crepitations in the mid-zones and reduced air entry in the right lower zone. Abdominal and neurological examinations were unremarkable.

Investigation results are below:

Haemoglobin (Hb)	15 g/dl
White cell count(WCC)	13.1 × 10^9/l

Differential count:

Neutrophils	9.2 × 10^9/l
Lymphocytes	2.2 × 10^9/l
Monocytes	0.2 × 10^9/l
Eosinophils	1.4 × 10^9/l
Basophils	0.1 × 10^9/l
Platelets	390 × 10^9/l
Na^+	138 mmol/l
Bilirubin	14 mol/l
K^+	4.2 mmol/l
Alkaline phosphatase	90 IU/l
Urea	5.2 mmol/l
Alanine aminotransferase (ALT)	32 IU/l
Creatinine	100 mol/l
Gamma-glutamyl transferase (GGT)	30 IU/l
Chest radiograph	Patchy infiltrates throughout both lung fields

What is the most likely diagnosis?

A	Cystic fibrosis
B	Invasive pulmonary aspergillosis
C	Cryptogenic eosinophilic pneumonia
D	Churg–Strauss syndrome
E	Allergic bronchopulmonary aspergillosis (ABPA)

Explanation

ABPA is due to endo-bronchial colonisation by the *Aspergillus fumigatus* fungus. It tends to present in early adult life on a background of worsening asthma. There is initially bronchospasm which can progress to proximal bronchiectasis and occasionally upper zone lung fibrosis, similar to TB.

Exacerbations are more common in the autumn and winter months. Patients often get recurrent episodes of eosinophilic pneumonia and fleeting infiltrates can often be seen on the chest X-ray. Mucus plugging can sometimes cause lobar collapse.

The diagnosis is made by skin prick testing, which causes an immediate hypersensitivity reaction. Serum precipitins are present in 90% of cases, and there is a high peripheral eosinophil count.

Treatment is with oral prednisolone, which usually results in a rapid clinical and radiological improvement. Sometimes maintenance steroids are needed to prevent relapse.

A number of studies have suggested a possible role for itraconazole therapy, e.g. Wark et al, Journal of Clinical Immunology 2003, and this may be a useful adjunctive therapy in some patients.

9156

Rate this question:

Next Question

Previous Question | Tag Question

Feedback | End Session

Difficulty: Average

Peer Responses %

Session Progress

Responses Correct:	0
Responses Incorrect:	78
Responses Total:	78
Responses - % Correct:	0%

© Pastest 2017

You are asked to review a 58-year-old care worker who has complained of diffuse, non-specific left-sided chest pain increasing over the past few months. She smokes 20 cigarettes per day and has no past medical history of note. Her husband works as a plumber and had worked as a boiler engineer for many years before that. Her chest X-ray reveals left-sided pleural thickening and evidence of an infiltrative lesion. A previous chest X-ray taken 12 months earlier was described as unremarkable.

Which of the following diagnoses fits best with the features of this case?

A	Adenocarcinoma of the bronchus
B	Small cell carcinoma of the bronchus
C	Mesothelioma
D	Benign pleural plaques
E	Asbestosis

9280

Submit

Previous Question | Skip Question

Calculator

Normal Values

© Pastest 2017

You are asked to review a 58-year-old care worker who has complained of diffuse, non-specific left-sided chest pain increasing over the past few months. She smokes 20 cigarettes per day and has no past medical history of note. Her husband works as a plumber and had worked as a boiler engineer for many years before that. Her chest X-ray reveals left-sided pleural thickening and evidence of an infiltrative lesion. A previous chest X-ray taken 12 months earlier was described as unremarkable.

Which of the following diagnoses fits best with the features of this case?

A	Adenocarcinoma of the bronchus
B	Small cell carcinoma of the bronchus
C	Mesothelioma
D	Benign pleural plaques
E	Asbestosis

Explanation

C	Mesothelioma

The appearance of this lesion over the past year, coupled with the history of possible asbestos exposure in the family, is suggestive of mesothelioma. A spouse can contract the disease through secondary exposure such as handling the laundry of a spouse that has already been exposed. Patients may present with a history of diffuse, non-specific chest pain and profuse sweating. The diagnosis is a possibility in any patient with a suggestion of asbestos exposure and who presents with pleural thickening or pleural effusion. Diagnosis is with pleural fluid aspiration and CT scanning. Repeated aspiration should be avoided if the diagnosis is suspected, due to the possible risk of tumour tracking. In addition, pleural biopsy is often helpful in making the diagnosis; this should be CT or ultrasound guided, if possible, rather than using a blind technique.

A	Adenocarcinoma of the bronchus

The presentation with initial pleural disease is more consistent with mesothelioma than a bronchial carcinoma.

B	Small cell carcinoma of the bronchus

Small cell carcinoma primaries are located centrally in 90% or more of cases, and this doesn't therefore fit with the clinical picture here.

D	Benign pleural plaques

The rapid evolution of the CXR over the course of the past year to now show an infiltrative lesion doesn't fit with benign pleural plaque disease.

E	Asbestosis

Asbestosis fits with a picture of pulmonary fibrosis, unlike that seen here.

9280

Rate this question:

Next Question

Previous Question | Tag Question

Feedback | End Session

Difficulty: Easy

Peer Responses %

Session Progress

Responses Correct:	0
Responses Incorrect:	79
Responses Total:	79
Responses - % Correct:	0%

© Pastest 2017

A woman presents to clinic in her eighth week of pregnancy. She is concerned about her husband's family history of cystic fibrosis (CF), as her husband's brother has cystic fibrosis and her husband has been confirmed as a carrier. The patient does not wish to know about her risk of developing CF and is reluctant to be tested herself, but is concerned about the health of her child. There is a 1:20 prevalence of CF carriage in the area where she lived as a child and husband and wife not consanguineous.

What is the chance of her child having cystic fibrosis?

A	1/4
B	1/40
C	1/80
D	1/160
E	1/320

9835

Submit

Previous Question | Skip Question

Calculator

Normal Values

© Pastest 2017

A woman presents to clinic in her eighth week of pregnancy. She is concerned about her husband's family history of cystic fibrosis (CF), as her husband's brother has cystic fibrosis and her husband has been confirmed as a carrier. The patient does not wish to know about her risk of developing CF and is reluctant to be tested herself, but is concerned about the health of her child. There is a 1:20 prevalence of CF carriage in the area where she lived as a child and husband and wife not consanguineous.

What is the chance of her child having cystic fibrosis?

A	1/4
B	1/40
C	1/80
D	1/160
E	1/320

Explanation

C	1/80

CF is an autosomal recessive disease, so two abnormal alleles are required for the disease to be manifest. As a carrier (with one abnormal gene) the husband has a 1:2 chance of passing the abnormal gene to his offspring. If one assumes that the woman is of the same genetic stock as those in the area of her birth, she has a 1:20 chance of being a carrier, so the chance of the child receiving an abnormal allele from both parents is 1/2 (male risk) × 1/20 (female carrier risk) × 1/2 (female risk of passing a gene on) = 1/80.

A	1/4

1 in 4 is the risk of a child being affected by CF if both of the parents are confirmed to be carriers for the disease.

B	1/40

1 in 40 would be the risk of offspring suffering from a recessive condition if one partner was a homozygote for the abnormal gene, and the carrier frequency was 1 in 20.

D	1/160

This would be the correct answer if the carrier frequency was 1 in 40, not 1 in 20 as it is.

E	1/320

This would be the correct answer if the carrier frequency was 1 in 80.

9835

Rate this question:

Next Question

Previous Question | Tag Question

Feedback | End Session

Difficulty: Average

Peer Responses %

Session Progress

Responses Correct:	0
Responses Incorrect:	80
Responses Total:	80
Responses - % Correct:	0%

© Pastest 2017

A 28-year-old Somalian woman presents suffering from increased shortness of breath for the last 3 months. She has recently returned to the UK after a visit to her family. She has a dry non-productive cough and admits to night sweats over the last 2 weeks. She is a non-smoker. On examination she is thin and not cyanosed at rest. There is no finger clubbing. There are no signs on auscultation of the chest, but chest X-ray (CXR) shows bilateral infiltrates.

Oxygen saturations are as follows:

$S_p(O_2)$ at rest	98%
$S_p(O_2)$ on exertion	82%

What investigation is most likely to provide the diagnosis?

A	Pulmonary function tests
B	V/Q scan
C	Bronchiolar lavage and transbronchial biopsy
D	computed tomography (CT) thorax
E	Exercise electrocardiogram

9836

Submit

Previous Question | Skip Question

Calculator

Normal Values

© Pastest 2017

A 28-year-old Somalian woman presents suffering from increased shortness of breath for the last 3 months. She has recently returned to the UK after a visit to her family. She has a dry non-productive cough and admits to night sweats over the last 2 weeks. She is a non-smoker. On examination she is thin and not cyanosed at rest. There is no finger clubbing. There are no signs on auscultation of the chest, but chest X-ray (CXR) shows bilateral infiltrates.

Oxygen saturations are as follows:

$S_p(O_2)$ at rest	98%
$S_p(O_2)$ on exertion	82%

What investigation is most likely to provide the diagnosis?

A	Pulmonary function tests
B	V/Q scan
C	Bronchiolar lavage and transbronchial biopsy
D	computed tomography (CT) thorax
E	Exercise electrocardiogram

Explanation

The presence of exercise induced oxygen desaturation in a young person should always raise the possibility of *Pneumocystis jirovecii* pneumonia (PCP), particularly in an individual who has lived in an area where undiagnosed HIV is common. PCP is traditionally considered a protozoan, although recent data suggests that it may be taxonomically closer to a fungus. It is a ubiquitous pathogen and disease most likely occurs as a result of latent infection acquired via the respiratory route early in life. Physical examination may reveal fever and tachypnea, but examination of the chest is frequently normal. Radiographic features vary considerably with diffuse, bilateral interstitial or alveolar infiltrates characteristic but unilateral or focal infiltrates, lobar or segmental consolidation also occurring.

Laboratory findings in PCP are generally unhelpful. Diagnosis can be made by staining spontaneous or induced sputum samples. In patients with HIV bronchiolar lavage diagnostic yield approaches 95% and this can be raised nearer 100% with the use of transbronchial biopsy.

9836

Rate this question:

Next Question

Previous Question | Tag Question

Feedback | End Session

Difficulty: Average

Peer Responses %

Session Progress

Responses Correct:	0
Responses Incorrect:	81
Responses Total:	81
Responses - % Correct:	0%

© Pastest 2017

A lady with known rheumatoid arthritis presents with breathlessness. Currently she is on prednisolone 3 mg and methotrexate 10 mg once a week, ranitidine and folic acid. She presents with cough. Chest X-ray (CXR) is within normal limits. O_2 sats are 97% on air but fall to 90% on exercise.

What is the best investigation to elicit the likely diagnosis?

A	Bronchoscopy with bronchoalveolar lavage (BAL)
B	Lung function tests
C	Arterial blood gases (ABGs)
D	V/Q scan
E	Echocardiogram

9837

Submit

Previous Question | Skip Question

Calculator

Normal Values

© Pastest 2017

A lady with known rheumatoid arthritis presents with breathlessness. Currently she is on prednisolone 3 mg and methotrexate 10 mg once a week, ranitidine and folic acid. She presents with cough. Chest X-ray (CXR) is within normal limits. O_2 sats are 97% on air but fall to 90% on exercise.

What is the best investigation to elicit the likely diagnosis?

A	Bronchoscopy with bronchoalveolar lavage (BAL)
B	Lung function tests
C	Arterial blood gases (ABGs)
D	V/Q scan
E	Echocardiogram

Explanation

The presence of exercise induced oxygen desaturation in an immunocompromised or immunosuppressed patient person should always raise the possibility of *Pneumocystis jirovecii* pneumonia (PCP). In this case however the possibility of methotrexate-induced pneumonitis should also be considered. Both conditions can be associated with dyspnoea, exercise induced desaturation and fever. Radiographic features vary considerably with diffuse, bilateral interstitial or alveolar infiltrates can also occur in both conditions.

Laboratory findings in PCP are generally unhelpful. Diagnosis can be made by staining spontaneous or induced sputum samples. In patients with HIV bronchiolar lavage diagnostic yield approaches 95% and this can be raised nearer 100% with the use of transbronchial biopsy. In methotrexate-induced pneumonitis pulmonary function tests show a restrictive pattern with diminished diffusion capacity but PFTs are often unhelpful in differentiating between causes of lung disease.

In this case as PCP is a life-threatening condition it should be excluded before investigating for other causes of dyspnoea.

9837

Rate this question:

Next Question

Previous Question | Tag Question

Feedback | End Session

Difficulty: Average

Peer Responses %

Session Progress

Responses Correct:	0
Responses Incorrect:	82
Responses Total:	82
Responses - % Correct:	0%

© Pastest 2017

An 18-year-old male patient with cystic fibrosis is admitted to hospital with an infective exacerbation of his condition. His latest sputum grew *Burkholderia cepacia*. His sister also has cystic fibrosis and has problems with abdominal pains.

Which of the following would you expect when investigating him and his sister?

A	The most frequent cause of their infective exacerbations is *Burkholderia cepacia*
B	Their spirometry shows a restrictive pattern
C	Both patients have pancreatic insufficiency
D	Both of their vitamin B_{12} and thiamine levels would be low
E	The cause of the abdominal pains is most likely to be meconium ileus

18134

Submit

Previous Question Skip Question

Calculator

Normal Values

Blog About Pastest Contact Us Help

© Pastest 2017

An 18-year-old male patient with cystic fibrosis is admitted to hospital with an infective exacerbation of his condition. His latest sputum grew *Burkholderia cepacia*. His sister also has cystic fibrosis and has problems with abdominal pains.

Which of the following would you expect when investigating him and his sister?

A	The most frequent cause of their infective exacerbations is *Burkholderia cepacia*
B	Their spirometry shows a restrictive pattern
C	Both patients have pancreatic insufficiency
D	Both of their vitamin B_{12} and thiamine levels would be low
E	The cause of the abdominal pains is most likely to be meconium ileus

Explanation

Cystic fibrosis is an autosomal recessive condition due to the defective cystic fibrosis transmembrane conductance regulator. The most common gene mutation responsible for this is the delta508 mutation. This causes defective chloride and sodium exchange across the epithelium in the lungs, resulting in recurrent chest infections and then in bronchiectasis (obstructive pattern on spirometry). The abdominal pain is caused not by meconium ileus but by distal intestinal obstruction syndrome (meconium ileus equivalent) in adults. This is due to the defective chloride secretion and increased sodium absorption in the gut, causing constipation. The treatment is to increase osmosis with Gastrografin or *N*-acetylcysteine. Patients also frequently suffer from gallstones, which can cause abdominal pains. Due to the pancreatic insufficiency, patients are unable to absorb fat-soluble vitamins such as vitamins A, D, E and K. Patients are therefore frequently on pancreatic exocrine supplements and fat-soluble vitamin supplements. The most frequent causes include S aureus, pneumococci or *Haemophilus* spp., but they also have an increased frequency of both *Pseudomonas aeuroginosa* and *B. cepecia*, with the latter carrying a worse prognosis.

18134

Rate this question:

Next Question

Previous Question | Tag Question

Feedback | End Session

Difficulty: Average

Peer Responses %

Session Progress

Responses Correct:	0
Responses Incorrect:	83
Responses Total:	83
Responses - % Correct:	0%

© Pastest 2017

You review a 26-year-old woman who has been admitted to the neurological ward for treatment. She complained of ascending symmetrical weakness and loss of sensation affecting both lower limbs. This began after a diarrhoeal illness. A diagnosis of Guillain Barré Syndrome was made. She is complaining to the nurses of increasing shortness of breath. You are aware that a deterioration in respiratory function can predict mortality. She is 50kg in weight. FVC on admission was noted to be 1.5l. You arrange for it to be checked again.

What level of FVC would indicate the threshold for respiratory support?

A	1.5L
B	1.4L
C	1.0L
D	1.3L
E	0.6L

18531

Submit

Previous Question Skip Question

Calculator

Normal Values

Blog About Pastest Contact Us Help

© Pastest 2017

You review a 26-year-old woman who has been admitted to the neurological ward for treatment. She complained of ascending symmetrical weakness and loss of sensation affecting both lower limbs. This began after a diarrhoeal illness. A diagnosis of Guillain Barré Syndrome was made. She is complaining to the nurses of increasing shortness of breath. You are aware that a deterioration in respiratory function can predict mortality. She is 50kg in weight. FVC on admission was noted to be 1.5l. You arrange for it to be checked again.

What level of FVC would indicate the threshold for respiratory support?

A	1.5L
B	1.4L
C	1.0L
D	1.3L
E	0.6L

Explanation

Deterioration in FVC is closely predictive of deterioration with opportunistic respiratory tract infection, and associated increased morbidity and mortality. Patients with Guillain Barré syndrome should be monitored with regular spirometry. The threshold for increased respiratory intervention is said to be around 20ml/kg FVC, which would put this at around 1 litre in this patient. Minimal sedation and aggressive physiotherapy while on the intensive care unit can serve to reduce the possibility of infection. Overall poor prognosis in Guillain Barré is associated with rapid progression of symptoms, advanced age, prolonged ventilation (>1 month), and severe action potential reduction on neuromuscular testing.

18531

Rate this question:

Next Question

Previous Question | Tag Question

Feedback | End Session

Difficulty: Average

Peer Responses %

Session Progress

Responses Correct:	0
Responses Incorrect:	84
Responses Total:	84
Responses - % Correct:	0%

© Pastest 2017

You are called to a cardiac arrest on the coronary care unit. A 74-year-old man with a 40-pack year smoking history and COPD on high dose salmeterol/fluticasone combination inhaler has arrested two days after admission with an inferior myocardial infarction.

Arterial blood gasses on admission were:-

pH	7.39
pO_2	8.5 mmol/l
pCO_2	5.8 mmol/l
HCO_3^-	31 mmol/l

Arterial blood gasses on 35% O_2 post cardiac arrest were:-

pH	7.29
pO_2	7.5 mmol/l
pCO_2	6.9 mmol/l

He responds appropriately to commands and is co-operative post his cardiac arrest. A portable chest X-ray shows no sign of resuscitation injury.

Which of the following is the most appropriate course of action with respect to his ventilatory support?

A	Continue 35% oxygen therapy
B	Reduce his inspired oxygen to 28%
C	Increase his inspired oxygen to 60%
D	Consider him for non-invasive positive pressure ventilation (NIPPV)
E	Consider him for intubation and ventilation

18537

Submit

Previous Question Skip Question

Calculator

Normal Values

Blog About Pastest Contact Us Help

© Pastest 2017

You are called to a cardiac arrest on the coronary care unit. A 74-year-old man with a 40-pack year smoking history and COPD on high dose salmeterol/fluticasone combination inhaler has arrested two days after admission with an inferior myocardial infarction.

Arterial blood gasses on admission were:-

pH	7.39
pO_2	8.5 mmol/l
pCO_2	5.8 mmol/l
HCO_3^-	31 mmol/l

Arterial blood gasses on 35% O_2 post cardiac arrest were:-

pH	7.29
pO_2	7.5 mmol/l
pCO_2	6.9 mmol/l

He responds appropriately to commands and is co-operative post his cardiac arrest. A portable chest X-ray shows no sign of resuscitation injury.

Which of the following is the most appropriate course of action with respect to his ventilatory support?

A	Continue 35% oxygen therapy
B	Reduce his inspired oxygen to 28%
C	Increase his inspired oxygen to 60%
D	Consider him for non-invasive positive pressure ventilation (NIPPV)
E	Consider him for intubation and ventilation

Explanation

On admission his arterial blood gasses revealed a compensated respiratory acidosis with some degree of CO_2 retention. Post cardiac arrest he has decompensated with relative hypoxia and CO_2 retention. Continuing his 35% O_2 may further exacerbate CO_2 retention and lead to respiratory arrest, as would increasing the inspired oxygen. Reducing inspired oxygen may exacerbate hypoxia and precipitate another cardiac arrest. He is conscious and may be co-operative enough for NIPPV which would be the initial treatment of choice. As well as being non-invasive and associated with less morbidity than intubation in the treatment of COPD, it may improve any pulmonary oedema associated with his myocardial infarction.

18537

Rate this question:

Next Question

Previous Question | Tag Question

Feedback | End Session

Difficulty: Average

Peer Responses %

Session Progress

Responses Correct:	0
Responses Incorrect:	85
Responses Total:	85
Responses - % Correct:	0%

© Pastest 2017

A 69-year-old smoker presents for review. He has a 60-pack year history and has recently begun losing weight. In addition he has a chronic cough and is thirsty all the time. Past history of note includes two left carotid territory TIAs in the past year. Blood testing reveals mild hypercalcaemia, a left upper lobe lung mass is seen on chest x-ray and trans-bronchial biopsy confirms this to be a squamous cell carcinoma of the bronchus. Results of investigations are as follows:-

CT scan: No evidence of lymph node, pleural or rib involvement
Spirometry: FEV_1 pre surgery less than 40% predicted
Carotid ultrasound: Left carotid 90% stenosis
Corrected calcium: 2.7 mmol/l

Which of the following represents the most appropriate management in this case?

A	Refer for left pneumonectomy
B	Refer for left upper lobectomy
C	Refer for radiotherapy
D	Refer for chemotherapy
E	Refer for combined chemo- and radiotherapy

18548

Submit

Previous Question | Skip Question

Calculator

Normal Values

© Pastest 2017

A 69-year-old smoker presents for review. He has a 60-pack year history and has recently begun losing weight. In addition he has a chronic cough and is thirsty all the time. Past history of note includes two left carotid territory TIAs in the past year. Blood testing reveals mild hypercalcaemia, a left upper lobe lung mass is seen on chest x-ray and trans-bronchial biopsy confirms this to be a squamous cell carcinoma of the bronchus. Results of investigations are as follows:-

CT scan: No evidence of lymph node, pleural or rib involvement
Spirometry: FEV_1 pre surgery less than 40% predicted
Carotid ultrasound: Left carotid 90% stenosis
Corrected calcium: 2.7 mmol/l

Which of the following represents the most appropriate management in this case?

A	Refer for left pneumonectomy
B	Refer for left upper lobectomy
C	Refer for radiotherapy
D	Refer for chemotherapy
E	Refer for combined chemo- and radiotherapy

Explanation

This patient's spirometry suggests that he is unlikely to survive surgery to remove lung tissue. In addition his carotid ultrasound is suggestive of significant risk of perioperative stroke. He may however be a candidate for aggressive radiotherapy. In addition, early studies have shown survival advantages for combined chemo and radiotherapy in these cases. In particular, continuous hyperfractionated radiotherapy (CHART) has shown an improvement in 2-year survival compared with conventional radical radiotherapy (29% versus 20%) with the largest benefits being seen in squamous cell carcinomas.

18548

Rate this question:

Next Question

Previous Question | Tag Question

Feedback | End Session

Difficulty: Average

Peer Responses %

Session Progress

Responses Correct:	0
Responses Incorrect:	86
Responses Total:	86
Responses - % Correct:	0%

© Pastest 2017

A 19-year-old student is brought to the Emergency department by his housemates. He has suffered a chronic cough for the past week and using increasing amounts of his blue inhaler. Ordinarily he is maintained on fluticasone/salmeterol combination inhaler 250 µg/50mg BD and montelukast 10mg daily. His housemates don't think he has registered with the student health service and are worried that he may not have filled his prescription.

Clinical features on admission to Emergency:-

- Respiratory rate 30/min
- PEFR 240 L/min, predicted 590 L/min
- O_2 saturation 90%

You commence oxygen therapy, give a bolus of IV hydrocortisone and give him a nebuliser containing salbutamol 5mg and atrovent 500 µg. The nurses repeat the salbutamol nebuliser three times.

Clinical features later in the evening: (on oxygen)

Respiratory rate	15/min
PEFR	230 L/min
pH	7.35
pO_2	7.7 kPa
pCO^2	5.8 kPa

What is the most appropriate next step for this gentleman?

A	IV salbutamol therapy
B	IV aminophylline therapy
C	IV magnesium therapy
D	Review by ITU physician
E	Continuous nebulised salbutamol therapy

18552

Submit

Previous Question | Skip Question

Calculator

Normal Values

© Pastest 2017

A 19-year-old student is brought to the Emergency department by his housemates. He has suffered a chronic cough for the past week and using increasing amounts of his blue inhaler. Ordinarily he is maintained on fluticasone/salmeterol combination inhaler 250 µg/50mg BD and montelukast 10mg daily. His housemates don't think he has registered with the student health service and are worried that he may not have filled his prescription.

Clinical features on admission to Emergency:-

- Respiratory rate 30/min
- PEFR 240 L/min, predicted 590 L/min
- O_2 saturation 90%

You commence oxygen therapy, give a bolus of IV hydrocortisone and give him a nebuliser containing salbutamol 5mg and atrovent 500 µg. The nurses repeat the salbutamol nebuliser three times.

Clinical features later in the evening: (on oxygen)

Respiratory rate	15/min
PEFR	230 L/min
pH	7.35
pO_2	7.7 kPa
pCO^2	5.8 kPa

What is the most appropriate next step for this gentleman?

A	IV salbutamol therapy
B	IV aminophylline therapy
C	IV magnesium therapy
D	Review by ITU physician
E	Continuous nebulised salbutamol therapy

Explanation

The most appropriate next step in this case would be review by an ITU physician. Despite therapy his peak flow has deteriorated, he is making less respiratory effort, and there is evidence of hypoxia with hypercapnia on arterial blood gas testing. Whilst IV salbutamol, IV magnesium sulphate and IV aminophylline may all be viable options for him, liason with ITU at an early stage is recommended, rather than in the peri-arrest situation.

© Pastest 2017

A 17-year-old man is admitted to the Emergency department. His carer called the ambulance after she found him in a drowsy and confused state at home. He had been suffering from a heavy cold. He is known to suffer from Duchenne's muscular dystrophy. Over the past few weeks she noted that he seemed to be suffering intermittent morning headaches, slight mental confusion, particularly in the mornings, and didn't enjoy his normal trip to the swimming pool due to shortness of breath.

On examination in the Emergency department he was drowsy but able to obey simple commands.

Respiratory rate was noted to be 13/min.
Bilateral air entry was poor with evidence of consolidation

pCO_2 7.0 kPa
pO_2 7.0 kPa

Which of the following would represent the most appropriate management in this case?

A	Commence high flow oxygen therapy
B	Commence 35% oxygen therapy
C	Commence 28% oxygen therapy
D	Refer for invasive ventilation on the intensive care unit
E	Consider non-invasive ventilation

18554

Submit

Previous Question | Skip Question

Calculator

Normal Values

© Pastest 2017

A 17-year-old man is admitted to the Emergency department. His carer called the ambulance after she found him in a drowsy and confused state at home. He had been suffering from a heavy cold. He is known to suffer from Duchenne's muscular dystrophy. Over the past few weeks she noted that he seemed to be suffering intermittent morning headaches, slight mental confusion, particularly in the mornings, and didn't enjoy his normal trip to the swimming pool due to shortness of breath.

On examination in the Emergency department he was drowsy but able to obey simple commands.

Respiratory rate was noted to be 13/min.
Bilateral air entry was poor with evidence of consolidation

pCO_2 7.0 kPa
pO_2 7.0 kPa

Which of the following would represent the most appropriate management in this case?

A	Commence high flow oxygen therapy
B	Commence 35% oxygen therapy
C	Commence 28% oxygen therapy
D	Refer for invasive ventilation on the intensive care unit
E	Consider non-invasive ventilation

Explanation

This man has evidence of chronic CO_2 retention as evidenced by his morning headaches, intermittent confusion and drowsiness. A further indication of respiratory muscle, particularly diaphragmatic weakness may be indicated by breathlessness at his swimming class. It is likely that chronic hypoventilation has led to opportunistic respiratory tract infection associated with his cold. Limited oxygen therapy would be unhelpful, and high flow oxygen may well lead to worsening CO_2 retention. Invasive ventilation should be carefully considered as Duchenne's is a progressive condition and weaning this man from a ventilator may be impossible. Therefore the best alternative is non-invasive ventilation, using a suitable mask and pressure support ventilator. He is at least compliant with commands and may tolerate the mask in this case.

18554

Rate this question:

Next Question

Previous Question | Tag Question

Feedback | End Session

Difficulty: Average

Peer Responses %

Session Progress

Responses Correct:	0
Responses Incorrect:	88
Responses Total:	88
Responses - % Correct:	0%

© Pastest 2017

A 32-year-old woman presents to her doctor complaining of increasing shortness of breath. Over the past year or so she has also noticed that her hands go white and are very painful if she ventures out into cold weather. On examination there is evidence of subcutaneous calcification in the fingers and fine bibasal crepitations and occasional wheeze are heard on auscultation of the chest.

Results:

Anti-nuclear antibody	positive
Anti scl-70 antibody	positive
FVC	3.2 L
FEV_1	2.6 L

Which of the following represents the most appropriate treatment in this case?

A	Commence inhaled corticosteroids
B	Commence inhaled short acting beta-2 agonist therapy
C	Commence oral corticosteroid therapy
D	Commence combined inhaled corticosteroid and beta-2 agonist therapy
E	Commence long-acting inhaled anti-cholinergic therapy

18555

Submit

Previous Question | Skip Question

Calculator

Normal Values

© Pastest 2017

A 32-year-old woman presents to her doctor complaining of increasing shortness of breath. Over the past year or so she has also noticed that her hands go white and are very painful if she ventures out into cold weather. On examination there is evidence of subcutaneous calcification in the fingers and fine bibasal crepitations and occasional wheeze are heard on auscultation of the chest.

Results:

Anti-nuclear antibody	positive
Anti scl-70 antibody	positive
FVC	3.2 L
FEV_1	2.6 L

Which of the following represents the most appropriate treatment in this case?

A	Commence inhaled corticosteroids
B	Commence inhaled short acting beta-2 agonist therapy
C	Commence oral corticosteroid therapy
D	Commence combined inhaled corticosteroid and beta-2 agonist therapy
E	Commence long-acting inhaled anti-cholinergic therapy

Explanation

This woman has evidence of systemic sclerosis, with clinical features and the scl-70 positivity pointing towards associated lung fibrosis. Her lung function tests also suggest the possibility of a restrictive lung defect further supporting this diagnosis. Management involves the use of high dose oral corticosteroids and additional cyclophosphamide. Around 15% of patients have disease which is associated with more rapidly progressive lung fibrosis. Lung fibrosis in systemic sclerosis may also be associated with an increased risk of lung cancer. Pulmonary hypertension is seen in association with this condition.

Whilst some controversy exists around the use of corticosteroids in systemic sclerosis, given the impairment of lung function here, it is potentially of value to trial corticosteroids in an attempt to guard against any further deterioration in respiratory disease.

18555

Rate this question:

Next Question

Previous Question | Tag Question

Feedback | End Session

Difficulty: Average

Peer Responses %

Session Progress

Responses Correct:	0
Responses Incorrect:	89
Responses Total:	89
Responses - % Correct:	0%

© Pastest 2017

A 34-year-old woman is referred to the respiratory clinic. She has had a long history of asthma since childhood and is maintained on combination inhaler therapy with fluticasone 250 μg/ salmeterol 50mg BD. On the advice of her doctor she moved away from London to the countryside and was well. Around 2-years ago she began keeping a horse and since than has noticed a gradual deterioration in her asthma control, with increased coughing up of mucus plugs. She has been started on high dose oral corticosteroids by her GP although she feels her symptoms have not significantly improved.

On examination in the clinic there was clear evidence of bilateral wheeze. Her peak flow was measured at 350 L/min.

Other results:-

IgE 1100 ng/ml
Peripheral blood eosinophil count 0.6 $x10^9$/l (0.04-0.4)
Skin prick positive to aspergillus
IgG precipitins to aspergillus
CXR - evidence of pulmonary infiltration

Which of the following represents the optimal next step in this patient?

A	Increased dose of inhaled steroids
B	Addition of oral monteleukast
C	Stop steroids and start itraconazole
D	Continue oral corticosteroids alone
E	Addition of itraconazole

18556

Submit

Previous Question | Skip Question

Calculator

Normal Values

© Pastest 2017

A 34-year-old woman is referred to the respiratory clinic. She has had a long history of asthma since childhood and is maintained on combination inhaler therapy with fluticasone 250 µg/ salmeterol 50mg BD. On the advice of her doctor she moved away from London to the countryside and was well. Around 2-years ago she began keeping a horse and since than has noticed a gradual deterioration in her asthma control, with increased coughing up of mucus plugs. She has been started on high dose oral corticosteroids by her GP although she feels her symptoms have not significantly improved.

On examination in the clinic there was clear evidence of bilateral wheeze. Her peak flow was measured at 350 L/min.

Other results:-

IgE 1100 ng/ml
Peripheral blood eosinophil count 0.6 $x10^9$/l (0.04-0.4)
Skin prick positive to aspergillus
IgG precipitins to aspergillus
CXR - evidence of pulmonary infiltration

Which of the following represents the optimal next step in this patient?

A	Increased dose of inhaled steroids
B	Addition of oral monteleukast
C	Stop steroids and start itraconazole
D	Continue oral corticosteroids alone
E	Addition of itraconazole

Explanation

There is evidence that this patient is suffering from bronchopulmonary aspergillosis. The factors which promote evolution from atopic asthma to this disease are unknown, but it appears that the type of CD4 response to aspergillus antigen appears to be crucial. Management involves the use of oral corticosteroids and there is evidence that additional prolonged courses of itraconazole (up to 4 months) may diminish the steroid requirement. Aggressive therapy with oral corticosteroids is known to reduce the risk of bronchiectasis that results from mucus plug impaction and subsequent localised infection.

18556

Rate this question:

Next Question

Previous Question | Tag Question

Feedback | End Session

Difficulty: Difficult

Peer Responses %

Session Progress

Responses Correct:	0
Responses Incorrect:	90
Responses Total:	90
Responses - % Correct:	0%

© Pastest 2017

You review a 48-year-old man in the respiratory clinic. He is diagnosed with tuberculosis and you want to start quadruple antituberculous therapy. He is very concerned about potential side-effects of therapy. Previous history of note includes abnormal liver function tests and a history of alcohol abuse, most recently he has been diagnosed with Type 2 diabetes. Recent ALT was 65U/l, creatinine 142 mol.

Which of the following fits best with a characteristic of its use in antituberculosis treatment?

A	Rifampicin should not be given where there is chronic renal failure
B	Pyrazinamide should not be used in patients with known chronic liver disease
C	Rifampicin increases the efficacy of sulphonylureas
D	Isoniazid is most likely to accumulate in renal failure leading to optic neuropathy
E	Pyridoxine should not be given to patients with renal impairment

18558

Submit

Previous Question Skip Question

Calculator

Normal Values

© Pastest 2017

You review a 48-year-old man in the respiratory clinic. He is diagnosed with tuberculosis and you want to start quadruple antituberculous therapy. He is very concerned about potential side-effects of therapy. Previous history of note includes abnormal liver function tests and a history of alcohol abuse, most recently he has been diagnosed with Type 2 diabetes. Recent ALT was 65U/l, creatinine 142 mol.

Which of the following fits best with a characteristic of its use in antituberculosis treatment?

A	Rifampicin should not be given where there is chronic renal failure
B	Pyrazinamide should not be used in patients with known chronic liver disease
C	Rifampicin increases the efficacy of sulphonylureas
D	Isoniazid is most likely to accumulate in renal failure leading to optic neuropathy
E	Pyridoxine should not be given to patients with renal impairment

Explanation

Drug induced hepatitis associated with anti-tuberculous therapy can be fatal, for this reason pyrazinamide should not be used in patients with known chronic liver disease. Rifampicin should be avoided where there is decompensated liver disease and in those patients taking sulphonylureas it may reduce the effectiveness of these agents. Ethambutol can accumulate in patients with chronic renal failure leading to optic neuropathy and therefore should be given at a lower dose. Pyridoxine should be given in addition to isoniazid in those with renal impairment to prevent peripheral neuropathy. Baseline and regular monitoring of liver function should be undertaken in patients on anti-tuberculous therapy, where there is a history of chronic liver disease it is advised that this is weekly for the first two weeks and then two weekly thereafter.

18558

Rate this question:

Next Question

Previous Question | Tag Question

Feedback | End Session

Difficulty: Average

Peer Responses %

Session Progress

Responses Correct:	0
Responses Incorrect:	91
Responses Total:	91
Responses - % Correct:	0%

© Pastest 2017

You are asked to comment on some arterial blood gas results. You understand the sample was taken from a 64-year-old patient attending one of the outpatient clinics.

Bloods;

pH	7.38
pCO_2	6.5 kPa
pO_2	8.0 kPa
HCO_3^-	38 mmol/l

Which of the following is the most likely underlying diagnosis?

A	Furosemide therapy
B	Bartter's syndrome
C	Chronic COPD
D	Acute exacerbation of COPD
E	Conn's syndrome

18627

Submit

Previous Question | Skip Question

Calculator

Normal Values

© Pastest 2017

You are asked to comment on some arterial blood gas results. You understand the sample was taken from a 64-year-old patient attending one of the outpatient clinics.

Bloods;

pH	7.38
pCO_2	6.5 kPa
pO_2	8.0 kPa
HCO_3^-	38 mmol/l

Which of the following is the most likely underlying diagnosis?

A	Furosemide therapy
B	Bartter's syndrome
C	Chronic COPD
D	Acute exacerbation of COPD
E	Conn's syndrome

Explanation

This picture is consistent with chronic COPD, as exhibited by CO_2 retention in the presence of a pH within the normal range. What has occurred over time is renal compensation with conservation of bicarbonate, leading to the elevated HCO_3^- level of 38 mmol/l which is seen here. During an acute exacerbation a vicious circle occurs, with inadequate gas exchange leading to progressive hypoxia and CO_2 retention; worsening acidosis then occurs.

18627

Rate this question:

Next Question

Previous Question | Tag Question

Feedback | End Session

Difficulty: Average

Peer Responses %

Session Progress

Responses Correct:	0
Responses Incorrect:	92
Responses Total:	92
Responses - % Correct:	0%

© Pastest 2017

A 71-year-old man presents to his GP along with his wife. He has severe problems with sleeping at night, snores, stops breathing, is restless and often disturbs his wife from sleep. During the day his family complain that he often falls asleep watching the television, after his dinner, or even whilst talking to his wife. He is a smoker of 20 cigarettes per day, has a hypertension and has suffered a TIA 3 years earlier. Medication includes ramipril 10mg, simvastatin 40mg, and aspirin 75mg. On examination his BMI is 32, his BP is 150/90 mmHg, and he has signs of right heart failure.

Bloods;

Hb	14.0 g/dl
WCC	5.8 $x10^9$/l
PLT	220 $x10^9$/l
Na^+	138 mmol/l
K^+	4.5 mmol/l
Creatinine	140 µ mol/l

Which of the following is the most likely diagnosis?

A	Central sleep apnoea
B	Nocturnal epilepsy
C	Obstructive sleep apnoea
D	Multiple TIAs
E	Narcolepsy

18628

Submit

Previous Question | Skip Question

Calculator

Normal Values

© Pastest 2017

A 71-year-old man presents to his GP along with his wife. He has severe problems with sleeping at night, snores, stops breathing, is restless and often disturbs his wife from sleep. During the day his family complain that he often falls asleep watching the television, after his dinner, or even whilst talking to his wife. He is a smoker of 20 cigarettes per day, has a hypertension and has suffered a TIA 3 years earlier. Medication includes ramipril 10mg, simvastatin 40mg, and aspirin 75mg. On examination his BMI is 32, his BP is 150/90 mmHg, and he has signs of right heart failure.

Bloods;

Hb	14.0 g/dl
WCC	5.8 $x10^9$/l
PLT	220 $x10^9$/l
Na^+	138 mmol/l
K^+	4.5 mmol/l
Creatinine	140 µ mol/l

Which of the following is the most likely diagnosis?

A	Central sleep apnoea
B	Nocturnal epilepsy
C	Obstructive sleep apnoea
D	Multiple TIAs
E	Narcolepsy

Explanation

This patient is obese, with hypertension and right heart failure. He has significant symptoms of nocturnal airway obstruction and daytime sleepiness, and this constellation of symptoms and signs fits with a diagnosis of obstructive sleep apnoea. Management of the condition involves aggressive weight reduction and the use of nocturnal CPAP to relieve nocturnal airway obstruction. Clearly this gentleman should also receive very strong advice to stop smoking.

18628

Rate this question:

Next Question

Previous Question | Tag Question

Feedback | End Session

Difficulty: Average

Peer Responses %

Session Progress

Responses Correct:	0
Responses Incorrect:	93
Responses Total:	93
Responses - % Correct:	0%

© Pastest 2017

A 68-year-old woman presents to the clinic complaining of increasing shortness of breath over the past year. Her GP has prescribed steroid and salbutamol inhalers, but they have given her little benefit. She has a past history of hypertension and has recently been prescribed furosemide for swollen ankles. In the past week or so her breathing has begun to deteriorate more rapidly. Examination reveals an increased respiratory rate at rest and finger clubbing. Auscultation of the chest reveals end inspiratory crackles at both lung bases.

Investigations;

Hb	13.1 g/dl
WCC	6.9 $x10^9$/l
PLT	300 $x10^9$/l
Viscosity	2.1 mPa/s
Na^+	140 mmol/l
K^+	5.0 mmol/l
Creatinine	120 µmol/l
pH	7.4
pO_2	7.2 kPa
pCO_2	3.7 kPa
CT thorax	interstitial lung disease, evidence of bilateral consolidation

Which of the following is the most likely diagnosis?

A	Sarcoidosis
B	Idiopathic pulmonary fibrosis
C	Silicosis
D	Alveolar cell carcinoma
E	Mycoplasma pneumonia

18629

Submit

Previous Question | Skip Question

Calculator

Normal Values

© Pastest 2017

A 68-year-old woman presents to the clinic complaining of increasing shortness of breath over the past year. Her GP has prescribed steroid and salbutamol inhalers, but they have given her little benefit. She has a past history of hypertension and has recently been prescribed furosemide for swollen ankles. In the past week or so her breathing has begun to deteriorate more rapidly. Examination reveals an increased respiratory rate at rest and finger clubbing. Auscultation of the chest reveals end inspiratory crackles at both lung bases.

Investigations;

Hb	13.1 g/dl
WCC	6.9 $x10^9$/l
PLT	300 $x10^9$/l
Viscosity	2.1 mPa/s
Na^+	140 mmol/l
K^+	5.0 mmol/l
Creatinine	120 µ mol/l
pH	7.4
pO_2	7.2 kPa
pCO_2	3.7 kPa
CT thorax	interstitial lung disease, evidence of bilateral consolidation

Which of the following is the most likely diagnosis?

A	Sarcoidosis
B	Idiopathic pulmonary fibrosis
C	Silicosis
D	Alveolar cell carcinoma
E	Mycoplasma pneumonia

Explanation

The clinical picture here of gradual deterioration, coupled with crackles on auscultation consistent with fibrosis, finger clubbing and the CT findings fit with the diagnosis. Patients may suffer an acute deterioration which is accompanied by consolidation, as we see here. Pulmonary histology may reveal areas of normal lung, interstitial fibrosis, inflammation and honeycomb change. Patients are usually managed with high dose corticosteroid therapy and oxygen if there is significant hypoxia.

18629

Rate this question:

Next Question

Previous Question | Tag Question

Feedback | End Session

Difficulty: Average

Peer Responses %

Session Progress

Responses Correct:	0
Responses Incorrect:	94
Responses Total:	94
Responses - % Correct:	0%

© Pastest 2017

A 73-year-old man with severe COPD managed with high dose combination steroid and long acting beta-agonists (LABA) inhaler is admitted to the Emergency room. He has suffered increasing shortness of breath and a worsening cough over the past few days and is now completely unable to get his breath. On examination he is pyrexial 38.2°C, there are chest signs consistent with both right sided consolidation and pulmonary oedema. He looks tired and his respiratory rate has fallen to 13/min.

Investigations;

Hb	13.1 g/dl
WCC	10.1 x10^9/l
PLT	295 x10^9/l
Na^+	134 mmol/l
K^+	4.0 mmol/l
Creatinine	128 µ mol/l
CRP	52 mg/l

CXR – Right sided consolidation, with evidence of pulmonary oedema

pH 7.28, pO_2 9.3 kPa, pCO_2 6.7 kPa on 40% O_2

Which of the following is the most appropriate method to manage his O_2 replacement?

A	Continue 40% O_2 by mask
B	Decrease inspired O_2 to 28% by mask
C	Continuous positive airway pressure (CPAP) ventilation
D	NIPPV ventilation
E	Increase inspired O_2 to 60% by mask

18669

Submit

Previous Question | Skip Question

Calculator

Normal Values

© Pastest 2017

A 73-year-old man with severe COPD managed with high dose combination steroid and long acting beta-agonists (LABA) inhaler is admitted to the Emergency room. He has suffered increasing shortness of breath and a worsening cough over the past few days and is now completely unable to get his breath. On examination he is pyrexial 38.2°C, there are chest signs consistent with both right sided consolidation and pulmonary oedema. He looks tired and his respiratory rate has fallen to 13/min.

Investigations;

Hb	13.1 g/dl
WCC	10.1 $x10^9$/l
PLT	295 $x10^9$/l
Na^+	134 mmol/l
K^+	4.0 mmol/l
Creatinine	128 µ mol/l
CRP	52 mg/l

CXR – Right sided consolidation, with evidence of pulmonary oedema

pH 7.28, pO_2 9.3 kPa, pCO_2 6.7 kPa on 40% O_2

Which of the following is the most appropriate method to manage his O_2 replacement?

A	Continue 40% O_2 by mask
B	Decrease inspired O_2 to 28% by mask
C	Continuous positive airway pressure (CPAP) ventilation
D	NIPPV ventilation
E	Increase inspired O_2 to 60% by mask

Explanation

This patient has both evidence of LVF and right sided pneumonia, a long history of COPD and is beginning to tire. Increasing inspired O_2 is likely to precipitate CO_2 retention and deterioration in his condition. CPAP, whilst a possible treatment for his LVF, is inferior to NIPPV ventilation from the point of view of his infectious exacerbation of COPD. Therefore NIPPV ventilation is the treatment of choice. Decreasing his inspired O_2 may result in worsening hypoxia.

18669

Rate this question:

Next Question

Previous Question | Tag Question

Feedback | End Session

Difficulty: Average

Peer Responses %

Session Progress

Responses Correct:	0
Responses Incorrect:	95
Responses Total:	95
Responses - % Correct:	0%

© Pastest 2017

A 36-year-old woman who has visited her GP 4 times in the past year for sinusitis, and has been feeling that she has begun to develop a nose deformity visits her GP complaining of shortness of breath. Additionally she has suffered one episode of haemoptysis. On examination her facial appearance suggests a saddle nose deformity.

Investigations

Hb	10.9 g/dl
WCC	6.9 $x10^9$/l
PLT	195 $x10^9$/l
Na^+	139 mmol/l
K^+	5.6 mmol/l
Creatinine	130 mol/l
Urine blood+, protein+	
cANCA	+

CXR shown below

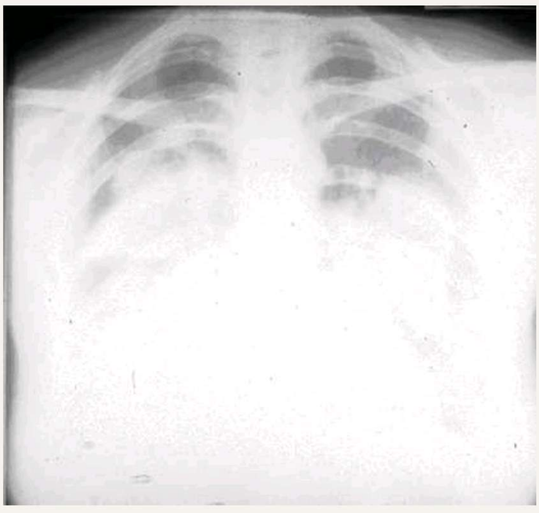

Given the likely diagnosis, which of the following is the most appropriate treatment for her?

A	Oral prednisolone 40mg daily
B	Oral cyclosporine
C	Pulsed IV methylprednisolone and cyclophosphamide
D	Oral azathioprine
E	Oral methotrexate

20543

Submit

Previous Question | Skip Question

Calculator

Normal Values

© Pastest 2017

A 36-year-old woman who has visited her GP 4 times in the past year for sinusitis, and has been feeling that she has begun to develop a nose deformity visits her GP complaining of shortness of breath. Additionally she has suffered one episode of haemoptysis. On examination her facial appearance suggests a saddle nose deformity.

Investigations

Hb	10.9 g/dl
WCC	6.9 $x10^9$/l
PLT	195 $x10^9$/l
Na^+	139 mmol/l
K^+	5.6 mmol/l
Creatinine	130 mol/l
Urine blood+, protein+	
cANCA	+

CXR shown below

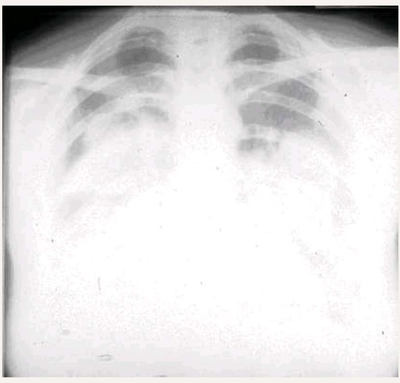

Given the likely diagnosis, which of the following is the most appropriate treatment for her?

A	Oral prednisolone 40mg daily
B	Oral cyclosporine
C	Pulsed IV methylprednisolone and cyclophosphamide
D	Oral azathioprine
E	Oral methotrexate

Explanation

This woman has a classical picture of Wegener's granulomatosis with sinusitis initially, now progressing to pulmonary infiltration with haemoptysis and renal involvement as evidenced by urinary blood and protein signifying glomerulonephritis. The anaemia seen here and positive c-ANCA serve to further support the diagnosis. Initial preferred therapy for Wegener's is with pulsed IV methylprednisolone and cyclophosphamide, although azathioprine or methotrexate may both be used for maintenance therapy. Prognosis generally depends on early diagnosis and intervention, so recognising the features seen here is crucial.

20543

Rate this question:

Next Question

Previous Question | Tag Question

Feedback | End Session

Difficulty: Average

Peer Responses %

Session Progress

Responses Correct:	0
Responses Incorrect:	96
Responses Total:	96
Responses - % Correct:	0%

© Pastest 2017

A 49-year-old nurse comes to the surgery. She is a smoker of 20 cigarettes per day and is complaining of increased shortness of breath, a chronic cough and wheezing. On examination she smells strongly of cigarettes. You can hear coarse wheezing and occasional crackles on auscultation.

Which of the following investigations would be most useful with respect to deciding on a long-term management plan?

A	Chest x-ray
B	Alpha-1-antitrypsin deficiency testing
C	CT thorax
D	Bronchoscopy
E	Spirometry with reversibility

20605

Submit

Previous Question Skip Question

Calculator

Normal Values

© Pastest 2017

A 49-year-old nurse comes to the surgery. She is a smoker of 20 cigarettes per day and is complaining of increased shortness of breath, a chronic cough and wheezing. On examination she smells strongly of cigarettes. You can hear coarse wheezing and occasional crackles on auscultation.

Which of the following investigations would be most useful with respect to deciding on a long-term management plan?

A	Chest x-ray
B	Alpha-1-antitrypsin deficiency testing
C	CT thorax
D	Bronchoscopy
E	Spirometry with reversibility

Explanation

This woman has evidence of chronic obstructive pulmonary disease, (COPD), but up to 30% of patients fit the definition of reversibility (>15% improvement in FEV1 post bronchodilator). In patients who are reversible, there is good evidence for treating with inhaled corticosteroids, as in asthma. Indeed, the TORCH study suggested a reduction in exacerbations in patients given high dose fluticasone and salmeterol combination inhaler.

20605

Rate this question:

Next Question

Previous Question | Tag Question

Feedback | End Session

Difficulty: Average

Peer Responses %

Session Progress

Responses Correct:	0
Responses Incorrect:	97
Responses Total:	97
Responses - % Correct:	0%

© Pastest 2017

A 71-year-old man with a 40 pack year smoking history presents for review after a 3rd hospital admission in the past year with a COPD exacerbation. He is managed at home with a salbutamol nebuliser, and he has a carer and a disabled badge to help him with getting around.

Investigations

Hb	14.5 g/dl
WCC	5.2 $x10^9$/l
PLT	201 $x10^9$/l
Na^+	139 mmol/l
K^+	4.9 mmol/l
Bicarbonate	29 mmol/l
Creatinine	104 µmol/l
FEV_1	40% predicted

Which of the following is the most appropriate therapy to reduce exacerbations?

A	Ipratropium
B	Tiotropium
C	Salmeterol
D	Beclomethasone
E	Salmeterol and fluticasone combination inhaler

20606

Submit

Previous Question | Skip Question

Calculator

Normal Values

© Pastest 2017

A 71-year-old man with a 40 pack year smoking history presents for review after a 3rd hospital admission in the past year with a COPD exacerbation. He is managed at home with a salbutamol nebuliser, and he has a carer and a disabled badge to help him with getting around.

Investigations

Hb	14.5 g/dl
WCC	5.2 $x10^9$/l
PLT	201 $x10^9$/l
Na^+	139 mmol/l
K^+	4.9 mmol/l
Bicarbonate	29 mmol/l
Creatinine	104 µ mol/l
FEV_1	40% predicted

Which of the following is the most appropriate therapy to reduce exacerbations?

A	Ipratropium
B	Tiotropium
C	Salmeterol
D	Beclomethasone
E	Salmeterol and fluticasone combination inhaler

Explanation

This patient has severe COPD. Whilst ipratropium is useful for relief of symptoms, particularly during an acute exacerbation, there is little evidence to support its regular use. The salmeterol and fluticasone combination outcome trial in COPD demonstrated reduced exacerbations at the expense of increased pneumonia events (TORCH), nearly reaching significance in mortality reduction. In contrast the tiotropium study showed reduced exacerbations, but with a trend to increased cardiovascular events, (although the observed increase in stroke was discounted in later studies).

20606

Rate this question:

Next Question

Previous Question | Tag Question

Feedback | End Session

Difficulty: Average

Peer Responses %

Session Progress

Responses Correct:	0
Responses Incorrect:	98
Responses Total:	98
Responses - % Correct:	0%

© Pastest 2017

A 42-year-old man, who is known to be HIV positive, presents with a cough productive of rusty coloured sputum. He has been feeling unwell for around a week or so. On examination he is pyrexial 38.2°C, with a BP of 135/70 mmHg. His pulse is 95/min and regular. Auscultation of the chest reveals an area of bronchial breathing over the right lower lung field.

Investigations

Hb	12.4 g/dl
WCC	13.1 $x10^9$/l (Neutrophilia)
PLT	195 $x10^9$/l
Na^+	139 mmol/l
K^+	4.9 mmol/l
Cr	100 µmol/l
CXR	Right lower lobe consolidation

Which of the following is the most likely diagnosis?

A	Pneumocystis pneumonia
B	Staphlococcus aureus pneumonia
C	Mycoplasma pneumonia
D	Streptococcus pneumoniae pneumonia
E	Klebsiella pneumonia

20635

Submit

Previous Question | Skip Question

Calculator

Normal Values

© Pastest 2017

A 42-year-old man, who is known to be HIV positive, presents with a cough productive of rusty coloured sputum. He has been feeling unwell for around a week or so. On examination he is pyrexial 38.2°C, with a BP of 135/70 mmHg. His pulse is 95/min and regular. Auscultation of the chest reveals an area of bronchial breathing over the right lower lung field.

Investigations

Hb	12.4 g/dl
WCC	13.1 x10^9/l (Neutrophilia)
PLT	195 x10^9/l
Na^+	139 mmol/l
K^+	4.9 mmol/l
Cr	100 µmol/l
CXR	Right lower lobe consolidation

Which of the following is the most likely diagnosis?

A	Pneumocystis pneumonia
B	Staphlococcus aureus pneumonia
C	Mycoplasma pneumonia
D	Streptococcus pneumoniae pneumonia
E	Klebsiella pneumonia

Explanation

This man has community acquired pneumonia which is most likely to be Strep pneumoniae. The estimated attack rate is higher in HIV infected patients (5.9/1000 vs 0.31/1000 in non-HIV infected patients. Resistance patterns are similar in HIV and non-HIV infected patients, invasive disease is rare and tends to occur in patients with a low CD4 count.

20635

Rate this question:

Next Question

Previous Question | Tag Question

Feedback | End Session

Difficulty: Easy

Peer Responses %

Session Progress

Responses Correct:	0
Responses Incorrect:	99
Responses Total:	99
Responses - % Correct:	0%

© Pastest 2017

A 17-year-old woman with a history of cystic fibrosis presents to the Emergency room with rapidly worsening shortness of breath, and a cough productive of much more sputum than usual with marked wheeze. She has started to lose weight and is off her food. On examination her BMI is 21, her BP is 105/72 mmHg, pulse 89/min with a temperature of 37.9°C. Auscultation of the chest reveals a mix of crackles and wheeze.

Investigations;

Hb	11.0 g/dl
WCC	12.2 x10^9/l
PLT	199 x10^9/l
Na^+	140 mmol/l
K^+	5.0 mmol/l
Creatinine	140 μ mol/l
Sputum sample	gram negative rods

Which of the following is the most likely identity of the bacteria found in the sputum sample?

A	Klebsiella
B	Mycoplasma
C	Pseudomonas
D	Bacteroides
E	Staphylococcus

20952

Submit

Previous Question | Skip Question

Calculator

Normal Values

© Pastest 2017

A 17-year-old woman with a history of cystic fibrosis presents to the Emergency room with rapidly worsening shortness of breath, and a cough productive of much more sputum than usual with marked wheeze. She has started to lose weight and is off her food. On examination her BMI is 21, her BP is 105/72 mmHg, pulse 89/min with a temperature of 37.9°C. Auscultation of the chest reveals a mix of crackles and wheeze.

Investigations;

Hb	11.0 g/dl
WCC	12.2 x10^9/l
PLT	199 x10^9/l
Na^+	140 mmol/l
K^+	5.0 mmol/l
Creatinine	140 µ mol/l
Sputum sample	gram negative rods

Which of the following is the most likely identity of the bacteria found in the sputum sample?

A	Klebsiella
B	Mycoplasma
C	Pseudomonas
D	Bacteroides
E	Staphylococcus

Explanation

Pseudomonas colonisation is associated with deterioration of respiratory symptoms, loss of appetite and weight loss in patients with CF. It is seen as gram negative rods on a sputum sample. Severity of pulmonary disease, including the degree of pseudomonas colonisation is closely related to outcome and prognosis. Inhaled tobramycin given intermittently over a prolonged period has been shown to delay the deterioration in lung function and improve prognosis for patients chronically infected with pseudomonas.

20952

Rate this question:

Next Question

Previous Question | Tag Question

Feedback | End Session

Difficulty: Average

Peer Responses %

Session Progress

Responses Correct:	0
Responses Incorrect:	100
Responses Total:	100
Responses - % Correct:	0%

© Pastest 2017

A 67-year-old man suffers a cardiac arrest on the ward shortly after coming back from the operating theatre. The arterial blood gas results taken 5 mins post the cardiac arrest call are shown below.

Investigations;

pH	6.87
pCO_2	8.2 kPa
pO_2	2.3 kPa
Bicarbonate	14 mmol/l
Anion gap	24
Lactate	14 mmol/l

Which of the following best describes his acid-base disturbance?

A	Metabolic acidosis
B	Mixed respiratory and metabolic acidosis
C	Metabolic alkalosis
D	Respiratory alkalosis
E	Metabolic acidosis with respiratory compensation

20981

Submit

Previous Question | Skip Question

Calculator

Normal Values

© Pastest 2017

A 67-year-old man suffers a cardiac arrest on the ward shortly after coming back from the operating theatre. The arterial blood gas results taken 5 mins post the cardiac arrest call are shown below.

Investigations;

pH	6.87
pCO_2	8.2 kPa
pO_2	2.3 kPa
Bicarbonate	14 mmol/l
Anion gap	24
Lactate	14 mmol/l

Which of the following best describes his acid-base disturbance?

A	Metabolic acidosis
B	Mixed respiratory and metabolic acidosis
C	Metabolic alkalosis
D	Respiratory alkalosis
E	Metabolic acidosis with respiratory compensation

Explanation

Clearly this patient has suffered a catastrophic event, which may have occurred much earlier than when he was actually found. Poor tissue perfusion has resulted in increased lactate, and lack of gas exchange has led to hypercapnia and low oxygenation. When we consider the features seen here, the pH is a result of mixed respiratory and metabolic acidosis, because of no meaningful gas exchange and lack of meaningful circulation, leading to a build up of lactate, high CO_2, low O_2.

20981

Rate this question:

Next Question

Previous Question | Tag Question

Feedback | End Session

Difficulty: Average

Peer Responses %

Session Progress

Responses Correct:	0
Responses Incorrect:	101
Responses Total:	101
Responses - % Correct:	0%

© Pastest 2017

A 54-year-old man comes to the Emergency department complaining of shortness of breath. He has been unwell for a few days and most recently has begun to spike fevers. He has a history of a previous MI some 4 years earlier and mild left ventricular failure as a consequence. Medication includes ramipril 10mg daily, aspirin 75mg and bendroflumethiazide 2.5mg. On examination his BP is 115/70 mmHg, pulse 95/min, and his temperature is 37.9°C. He has bilateral crackles on auscultation, perhaps more marked on the left than the right and a respiratory rate of 36/min.

Investigations;

pH	7.6
pCO_2	3.2 kPa
pO_2	7.2 kPa
Bicarbonate	33 mmol/l

Which of the following best describes his acid-base disturbance?

A	Compensated respiratory alkalosis
B	Compensated respiratory acidosis
C	Mixed respiratory and metabolic alkalosis
D	Respiratory alkalosis with metabolic acidosis
E	Metabolic and respiratory acidosis

20982

Submit

Previous Question | Skip Question

Calculator

Normal Values

© Pastest 2017

A 54-year-old man comes to the Emergency department complaining of shortness of breath. He has been unwell for a few days and most recently has begun to spike fevers. He has a history of a previous MI some 4 years earlier and mild left ventricular failure as a consequence. Medication includes ramipril 10mg daily, aspirin 75mg and bendroflumethiazide 2.5mg. On examination his BP is 115/70 mmHg, pulse 95/min, and his temperature is 37.9°C. He has bilateral crackles on auscultation, perhaps more marked on the left than the right and a respiratory rate of 36/min.

Investigations;

pH	7.6
pCO_2	3.2 kPa
pO_2	7.2 kPa
Bicarbonate	33 mmol/l

Which of the following best describes his acid-base disturbance?

A	Compensated respiratory alkalosis
B	Compensated respiratory acidosis
C	Mixed respiratory and metabolic alkalosis
D	Respiratory alkalosis with metabolic acidosis
E	Metabolic and respiratory acidosis

Explanation

This man may well be suffering from pneumonia. Hyperventilation has produced a mild respiratory alkalosis. The bicarbonate of 33mmol/l is most likely due to chronic thiazide diuretic use. Clearly this patient requires oxygen replacement, which is likely to bring his pO_2 back into the normal range. It's also important to adequately assess his fluid balance, as infection on top of diuretic and ACE inhibitor use may have precipitated a degree of renal deterioration.

20982

Rate this question:

Next Question

Previous Question | Tag Question

Feedback | End Session

Difficulty: Average

Peer Responses %

Session Progress

Responses Correct:	0
Responses Incorrect:	102
Responses Total:	102
Responses - % Correct:	0%

© Pastest 2017

A 42-year-old publican is admitted with increasing shortness of breath which is relieved by lying flat. He has been seen on one previous occasion with a haematemesis and admits to drinking 6-8 pints of strong lager per day. He also smokes 20 cigarettes per day. On examination he looks unwell; he has signs of chronic liver disease including clubbing, spider naevi, scratch marks, swollen ankles and ascites. He is tender in the right upper quadrant. Respiratory examination is suggestive of bilateral pleural effusions. His BP is 95/60 mmHg, pulse is 100/min.

Investigations;

Hb	10.0 g/dl
WCC	5.6 $x10^9$/l
PLT	78 $x10^9$/l
Na^+	138 mmol/l
K^+	3.8 mmol/l
Creatinine	90 µmol/l
ALT	140 U/l
Bilirubin	110 µmol/l
Albumin	22 g/l
pO_2	7.9 kPa
pCO_2	3.9 kPa

Which of the following is the most likely diagnosis?

A	Pulmonary embolus
B	Cardiac failure
C	Hepatopulmonary syndrome
D	COPD
E	Pulmonary fibrosis

20999

Submit

Previous Question | Skip Question

Calculator

Normal Values

© Pastest 2017

A 42-year-old publican is admitted with increasing shortness of breath which is relieved by lying flat. He has been seen on one previous occasion with a haematemesis and admits to drinking 6-8 pints of strong lager per day. He also smokes 20 cigarettes per day. On examination he looks unwell; he has signs of chronic liver disease including clubbing, spider naevi, scratch marks, swollen ankles and ascites. He is tender in the right upper quadrant. Respiratory examination is suggestive of bilateral pleural effusions. His BP is 95/60 mmHg, pulse is 100/min.

Investigations;

Hb	10.0 g/dl
WCC	5.6 $x10^9$/l
PLT	78 $x10^9$/l
Na^+	138 mmol/l
K^+	3.8 mmol/l
Creatinine	90 µmol/l
ALT	140 U/l
Bilirubin	110 µmol/l
Albumin	22 g/l
pO_2	7.9 kPa
pCO_2	3.9 kPa

Which of the following is the most likely diagnosis?

A	Pulmonary embolus
B	Cardiac failure
C	Hepatopulmonary syndrome
D	COPD
E	Pulmonary fibrosis

Explanation

Given the history of significant liver disease, a link between this and his chest pathology, hepatopulmonary syndrome is more likely than a pulmonary embolus. Equally, there are no signs suggestive of either COPD or pulmonary fibrosis. Hepatopulmonary syndrome is due to arteriovenous shunting and is potentially progressive and life threatening. It is associated with gross dilatation of pulmonary pre-capillary and capillary vessels, hypoxia lying flat may be exacerbated because of preferential perfusion of lung bases, which are better ventilated when the patient lies flat. Hypoxia may be further worsened by the presence of significant pleural effusions. Nitric oxide is thought to play a role in the condition, largely as a result of studies in rodent models, although this is yet to be confirmed in human studies. The syndrome may be corrected by liver transplantation, and is adequate reason for expedited referral. Platypnoea is related to this abnormal pulmonary vasodilation which leads to inappropriate shunting. Bubbles can be seen appearing late in the left atrium when agitated saline is injected and the atrium is observed on echocardiography.

20999

Rate this question:

Next Question

Previous Question | Tag Question

Feedback | End Session

Difficulty: Average

Peer Responses %

Session Progress

Responses Correct:	0
Responses Incorrect:	103
Responses Total:	103
Responses - % Correct:	0%

© Pastest 2017

A 70-year-old woman who underwent right hemicolectomy opted to receive a designated blood transfusion from her daughter who is the same blood group. Whilst on the ward undergoing the first unit of blood she began to complain of extreme shortness of breath. Her blood pressure was markedly reduced at 90/50 mmHg. On examination there were inspiratory crackles consistent with heart failure throughout both lung fields. Dipstick of her urine was negative for haematuria.

Which of the following is the most likely cause of this transfusion reaction?

A	ABO incompatibility
B	Rhesus incompatibility
C	Granulocyte antibodies in the donor blood
D	Granulocyte antibodies in the recipient blood
E	Cytokines in the donor blood

21000

Submit

Previous Question | Skip Question

Calculator

Normal Values

© Pastest 2017

A 70-year-old woman who underwent right hemicolectomy opted to receive a designated blood transfusion from her daughter who is the same blood group. Whilst on the ward undergoing the first unit of blood she began to complain of extreme shortness of breath. Her blood pressure was markedly reduced at 90/50 mmHg. On examination there were inspiratory crackles consistent with heart failure throughout both lung fields. Dipstick of her urine was negative for haematuria.

Which of the following is the most likely cause of this transfusion reaction?

A	ABO incompatibility
B	Rhesus incompatibility
C	Granulocyte antibodies in the donor blood
D	Granulocyte antibodies in the recipient blood
E	Cytokines in the donor blood

Explanation

Transfusion related lung injury or TRALI is thought to be related to anti-HLA or anti-granulocyte antibodies in the donor blood. Despite the fact that the donor and recipient are matched, the possibility of anti-granulocyte antibodies cannot be excluded. It is postulated that TRALI is seen more often in when multiparous women donate blood, because of generation of antibodies to HLA antigens through multiple exposures to fetal blood. Lung symptoms are often difficult to distinguish from ARDS, and management of TRALI is consistent with the management of ARDS itself.

21000

Rate this question:

Next Question

Previous Question | Tag Question

Feedback | End Session

Difficulty: Average

Peer Responses %

Session Progress

Responses Correct:	0
Responses Incorrect:	104
Responses Total:	104
Responses - % Correct:	0%

© Pastest 2017

A 17-year-old girl comes to the Emergency room complaining of extreme lethargy. 1-2 weeks earlier she had suffered from a nasty bout of gastroenteritis after a takeaway meal. She complains of abnormal sensation and numbness in her fingers, and weakness of her lower legs. She is generally hypotonic and has difficulty standing. On examination there is a postural drop in BP of 20 mmHg to 105/70 mmHg, and she has a resting tachycardia of 90 BPM. No deep tendon reflexes can be elicited in her lower limbs. Only medication of note includes the oral contraceptive pill.

Investigations;

Hb	12.1 g/dl
WCC	6.9 x10^9/l
PLT	230 x10^9/l
Na^+	141 mmol/l
K^+	4.8 mmol/l
Creatinine	140 μmol/l
Glucose	7.2 mmol/l
TSH	1.8 U/l

Given the likely diagnosis, which of the following is the most important way to monitor the progress of her condition?

A	Lumbar puncture
B	Anti-GQ1b antibodies
C	FVC
D	FEV_1
E	Creatine kinase levels

21025

Submit

Previous Question | Skip Question

Calculator

Normal Values

© Pastest 2017

A 17-year-old girl comes to the Emergency room complaining of extreme lethargy. 1-2 weeks earlier she had suffered from a nasty bout of gastroenteritis after a takeaway meal. She complains of abnormal sensation and numbness in her fingers, and weakness of her lower legs. She is generally hypotonic and has difficulty standing. On examination there is a postural drop in BP of 20 mmHg to 105/70 mmHg, and she has a resting tachycardia of 90 BPM. No deep tendon reflexes can be elicited in her lower limbs. Only medication of note includes the oral contraceptive pill.

Investigations;

Hb	12.1 g/dl
WCC	6.9 $x10^9$/l
PLT	230 $x10^9$/l
Na^+	141 mmol/l
K^+	4.8 mmol/l
Creatinine	140 µ mol/l
Glucose	7.2 mmol/l
TSH	1.8 U/l

Given the likely diagnosis, which of the following is the most important way to monitor the progress of her condition?

A	Lumbar puncture
B	Anti-GQ1b antibodies
C	FVC
D	FEV_1
E	Creatine kinase levels

Explanation

This woman has a history consistent with Guillain Barre syndrome (GBS) which is known to occur after an episode of bacterial gastroenteritis. Typical symptoms seen here include parasthesiae in the fingers, with progressive lower limb weakness. Autonomic signs such as tachycardia and postural hypotension also occur. Whilst lumbar puncture is an important part of GBS assessment, a normal CSF protein does not exclude the condition. Anti-GQ1b antibodies are found in the Miller-Fischer variant of GBS, which is associated with ophthalmoplegia. Raised CK levels may be suggestive of another condition such as myositis. FVC is the most helpful investigation in assessing prognosis, respiratory failure including supervening bacterial pneumonia is the most important cause of morbidity/ mortality associated with the condition.

21025

Rate this question:

Next Question

Previous Question | Tag Question

Feedback | End Session

Difficulty: Average

Peer Responses %

Session Progress

Responses Correct:	0
Responses Incorrect:	105
Responses Total:	105
Responses - % Correct:	0%

© Pastest 2017

A 63-year-old man presents to the clinic with severe shortness of breath. He admits to having smoked 30 cigarettes per day for the past 40 years. Over the past 3 years he has been admitted to hospital twice with respiratory tract infections. On examination his BP is 149/64 mmHg, his pulse is 83/min, atrial fibrillation, and there is coarse wheeze on auscultation of the chest. He has bilateral lower limb oedema consistent with right heart failure.

Investigations;

Hb	14.5 g/dl
WCC	6.1 $x10^9$/l
PLT	310 $x10^9$/l
Na^+	142 mmol/l
K^+	4.4 mmol/l
Creatinine	130 µ mol/l
pH	7.45
pO_2	8.1 kPa
pCO_2	6.4 kPa
HCO_3^-	32 mmol/l
FEV_1	30% of predicted

Which of the following is the most appropriate intervention with respect to improving outcomes?

A	Salbutamol PRN
B	Ipratropium PRN
C	Salmeterol BD
D	Fluticasone 50mcg BD
E	High dose fluticasone and salmeterol BD in combination

21027

Submit

Previous Question | Skip Question

Calculator

Normal Values

© Pastest 2017

A 63-year-old man presents to the clinic with severe shortness of breath. He admits to having smoked 30 cigarettes per day for the past 40 years. Over the past 3 years he has been admitted to hospital twice with respiratory tract infections. On examination his BP is 149/64 mmHg, his pulse is 83/min, atrial fibrillation, and there is coarse wheeze on auscultation of the chest. He has bilateral lower limb oedema consistent with right heart failure.

Investigations;

Hb	14.5 g/dl
WCC	6.1 x10^9/l
PLT	310 x10^9/l
Na^+	142 mmol/l
K^+	4.4 mmol/l
Creatinine	130 µ mol/l
pH	7.45
pO_2	8.1 kPa
pCO_2	6.4 kPa
HCO_3^-	32 mmol/l
FEV_1	30% of predicted

Which of the following is the most appropriate intervention with respect to improving outcomes?

A	Salbutamol PRN
B	Ipratropium PRN
C	Salmeterol BD
D	Fluticasone 50mcg BD
E	High dose fluticasone and salmeterol BD in combination

Explanation

This patient's history of smoking, his arterial blood gas result, right heart failure and severely reduced FEV1 all suggest a diagnosis of COPD. Whilst salbutamol and ipratropium have a role in symptom relief, neither has any impact at all with respect to objective outcome measures. Low dose inhaled steroids and salmeterol similarly did not impact on hard outcomes in COPD. In contrast the TORCH study examined the effect of high dose fluticasone in combination with salmeterol and demonstrated a borderline significant effect on mortality, a reduction in exacerbations, although an increase in pneumonia was seen.

21027

Rate this question:

Next Question

Previous Question | Tag Question

Feedback | End Session

Difficulty: Average

Peer Responses %

Session Progress

Responses Correct:	0
Responses Incorrect:	106
Responses Total:	106
Responses - % Correct:	0%

© Pastest 2017

A 62-year-old plumber comes to the clinic complaining of increasing shortness of breath and a persistent cough. He has also begun to get tired while walking the dog which is spoiling the enjoyment of his time off. He smokes 5 cigarettes per day. On examination he is finger clubbed and you can hear fine end inspiratory crackles.

Investigations;

Hb	12.8 g/dl
WCC	4.5 $x10^9$/l
PLT	210 $x10^9$/l
Na^+	141 mmol/l
K^+	4.9 mmol/l
Creatinine	140 µ mol/l
CXR	Bilateral pleural thickening, and reticulonodular pulmonary infiltration
FEV_1	2.7
FVC	3.1

Which of the following is the most likely diagnosis?

A	Asthma
B	Solderer's lung
C	Asbestosis
D	COPD
E	Idiopathic pulmonary fibrosis

21028

Submit

Previous Question | Skip Question

Calculator

Normal Values

© Pastest 2017

A 62-year-old plumber comes to the clinic complaining of increasing shortness of breath and a persistent cough. He has also begun to get tired while walking the dog which is spoiling the enjoyment of his time off. He smokes 5 cigarettes per day. On examination he is finger clubbed and you can hear fine end inspiratory crackles.

Investigations;

Hb	12.8 g/dl
WCC	4.5 $x10^9$/l
PLT	210 $x10^9$/l
Na^+	141 mmol/l
K^+	4.9 mmol/l
Creatinine	140 µ mol/l
CXR	Bilateral pleural thickening, and reticulonodular pulmonary infiltration
FEV_1	2.7
FVC	3.1

Which of the following is the most likely diagnosis?

A	Asthma
B	Solderer's lung
C	Asbestosis
D	COPD
E	Idiopathic pulmonary fibrosis

Explanation

The clue is very clear that in his work as a plumber this man is likely to have had significant exposure to asbestos. The chest x-ray findings of bilateral pleural thickening also point towards asbestos exposure. High resolution CT is important to confirm pulmonary fibrosis, and pulse oximetry normally reveals a degree of hypoxaemia. Despite extensive trials, neither corticosteroids or 2nd line immunomodulatory agents have any significant impact on the course of the disease.

21028

Rate this question:

Next Question

Previous Question | Tag Question

Feedback | End Session

Difficulty: Average

Peer Responses %

Session Progress

Responses Correct:	0
Responses Incorrect:	107
Responses Total:	107
Responses - % Correct:	0%

© Pastest 2017

A 77-year-old man who smokes 20 cigarettes per day presents to the clinic with a chronic cough and most recently increasing haemoptysis. He has lost 4kg in weight over the past 3 months. On examination he looks thin; his BMI is 20. His BP is 140/75 mmHg. Auscultation of the chest reveals changes consistent with COPD.

Investigations;

Hb	11.9 g/dl
WCC	8.9 $x10^9$/l
PLT	231 $x10^9$/l
Na^+	137 mmol/l
K^+	4.5 mmol/l
Creatinine	140 µmol/l
ESR	67 mm/hr
CXR	Left sided mass suspicious of bronchial carcinoma
Trans-bronchial biopsy	squamous cell carcinoma

Which of the following would be a contraindication to left pneumonectomy?

A	Hypercalcaemia
B	FEV_1 1.7 post bronchodilators
C	MI within 6 months
D	His age of 77 years
E	Tumour extending to the surface of the visceral pleura on CT

21213

Submit

Previous Question | Skip Question

Calculator

Normal Values

© Pastest 2017

A 77-year-old man who smokes 20 cigarettes per day presents to the clinic with a chronic cough and most recently increasing haemoptysis. He has lost 4kg in weight over the past 3 months. On examination he looks thin; his BMI is 20. His BP is 140/75 mmHg. Auscultation of the chest reveals changes consistent with COPD.

Investigations;

Hb	11.9 g/dl
WCC	8.9 $x10^9$/l
PLT	231 $x10^9$/l
Na^+	137 mmol/l
K^+	4.5 mmol/l
Creatinine	140 µ mol/l
ESR	67 mm/hr
CXR	Left sided mass suspicious of bronchial carcinoma
Trans-bronchial biopsy	squamous cell carcinoma

Which of the following would be a contraindication to left pneumonectomy?

A	Hypercalcaemia
B	FEV_1 1.7 post bronchodilators
C	MI within 6 months
D	His age of 77 years
E	Tumour extending to the surface of the visceral pleura on CT

Explanation

Patients who have an FEV_1 of less than 2.0 post bronchodilators are not recommended for pneumonectomy. Hypercalcaemia may be a paraneoplastic phenomenon related to PTHrp or might actually have no link at all to the underlying bronchial carcinoma. Surgery is not recommended if the patient has suffered an MI within 6 weeks; a history of MI within 6 months necessitates a cardiology opinion. Tumour abutting the visceral pleura is not necessarily a contra-indication to surgery, although more radical resection may be required.

21213

Rate this question:

Next Question

Previous Question | Tag Question

Feedback | End Session

Difficulty: Average

Peer Responses %

Session Progress

Responses Correct:	0
Responses Incorrect:	108
Responses Total:	108
Responses - % Correct:	0%

© Pastest 2017

A 54-year-old woman has a left adenocarcinoma of the bronchus confirmed on transbronchial biopsy. She tells you that she has lost weight over the past few months and has a nagging cough, particularly in the mornings, but actually has still been able to hold down her job, riding her bike the short distance to work, and caring for her teenage children.

Investigations;

Hb	13.5 g/dl
WCC	5.6 $x10^9$/l
PLT	190 $x10^9$/l
Na^+	139 mmol/l
K^+	4.5 mmol/l
Creatinine	120 µmol/l

Which of the following is likely to be most informative with respect to determining her suitability for surgery?

A	Pulmonary function testing
B	CT thorax
C	PET/CT combined scan
D	Serum calcium
E	CT Head

21214

Submit

Previous Question | Skip Question

Calculator

Normal Values

© Pastest 2017

A 54-year-old woman has a left adenocarcinoma of the bronchus confirmed on transbronchial biopsy. She tells you that she has lost weight over the past few months and has a nagging cough, particularly in the mornings, but actually has still been able to hold down her job, riding her bike the short distance to work, and caring for her teenage children.

Investigations;

Hb	13.5 g/dl
WCC	5.6 $x10^9$/l
PLT	190 $x10^9$/l
Na^+	139 mmol/l
K^+	4.5 mmol/l
Creatinine	120 µ mol/l

Which of the following is likely to be most informative with respect to determining her suitability for surgery?

A	Pulmonary function testing
B	CT thorax
C	PET/CT combined scan
D	Serum calcium
E	CT Head

Explanation

PET/CT combined scanning offers the best imaging modality to determine lymph node involvement in bronchial carcinoma. Of course, FEV_1 and FVC do have an impact on suitability for surgery, but given that we are told she cycles to work, and aren't given information on her smoking status, it is likely that her lung function is adequate to undergo pneumonectomy. A number of reasons for hypercalcaemia quite unconnected with bronchial carcinoma may be apparent; hence raised calcium per se would not represent a contra-indication to surgery.

21214

Rate this question:

Next Question

Previous Question | Tag Question

Feedback | End Session

Difficulty: Average

Peer Responses %

Session Progress

Responses Correct:	0
Responses Incorrect:	109
Responses Total:	109
Responses - % Correct:	0%

© Pastest 2017

A 62-year-old woman with a history of 30 pack years of smoking presents with a cough and haemoptysis. She has been feeling increasingly lethargic over the past few months. On examination there is no lymphadenopathy and she looks thin. Auscultation of the chest reveals wheeze and occasional coarse crackles consistent with a COPD picture.

Investigations;

Hb	11.5 g/dl
WCC	8.1 $x10^9$/l
PLT	224 $x10^9$/l
Na^+	134 mmol/l
K^+	5.0 mmol/l
Creatinine	100 µ mol/l
CXR	Right upper lobe tumour
FEV_1	2.0 l
Staging CT	3.5cm lesion with ipsilateral hilar lymphadenopathy, similar findings on PET

Which of the following represents the likely appropriate management?

A	Palliative chemotherapy
B	Palliative radiotherapy
C	Radical radiotherapy
D	Pneumonectomy
E	Radical chemoradiotherapy

21215

Submit

Previous Question | Skip Question

Calculator

Normal Values

© Pastest 2017

A 62-year-old woman with a history of 30 pack years of smoking presents with a cough and haemoptysis. She has been feeling increasingly lethargic over the past few months. On examination there is no lymphadenopathy and she looks thin. Auscultation of the chest reveals wheeze and occasional coarse crackles consistent with a COPD picture.

Investigations;

Hb	11.5 g/dl
WCC	8.1 $x10^9$/l
PLT	224 $x10^9$/l
Na^+	134 mmol/l
K^+	5.0 mmol/l
Creatinine	100 μ mol/l
CXR	Right upper lobe tumour
FEV_1	2.0 l
Staging CT	3.5cm lesion with ipsilateral hilar lymphadenopathy, similar findings on PET

Which of the following represents the likely appropriate management?

A	Palliative chemotherapy
B	Palliative radiotherapy
C	Radical radiotherapy
D	Pneumonectomy
E	Radical chemoradiotherapy

Explanation

This woman's lung function suggests that she would be a potential surgical candidate. Guidelines suggest that $FEV_1 > 2.0$ l is the cut off for pneumonectomy. The N1 staging seen here, with ipsilateral hilar lymphadenopathy is also not a contra-indication to surgery. N2 lymph nodes (ipsilateral mediastinal or sub-carinal involvement), particularly when they are bulky, do contra-indicate surgery. If she did have more advanced lymph node involvement and was not a surgical candidate then combined chemo- and radiotherapy would be the most appropriate option.

21215

Rate this question:

Next Question

Previous Question | Tag Question

Feedback | End Session

Difficulty: Average

Peer Responses %

Session Progress

Responses Correct:	0
Responses Incorrect:	110
Responses Total:	110
Responses - % Correct:	0%

© Pastest 2017

A 21-year-old comes to the Emergency room with symptoms of an upper respiratory tract infection and sharp stabbing chest pain over his left upper chest when he breathes in. He is usually well and is doing a degree in physical education. He is a non-smoker who only drinks small amounts of alcohol. On examination his BP is 135/70 mmHg, his temperature is 37.9°C, his pulse is 84/min and regular. Auscultation of the chest is clear, although there are some transmitted sounds from his upper respiratory tract infection. He has some limited anterior chest wall tenderness.

Investigations:

Hb	141 g/l (130-180)
WCC	8.2 × 10^9/l (4.0--1.0)
PLT	202 × 10^9/l (150–400)
Na^+	139 mmol/l (133–146)
K^+	4.5 mmol/l (3.5–5.3)
Creatinine	100 mol/l (55–120)
Chest X-Ray	No abnormalities seen
ECG	Sinus rhythm with a rate of 84; no acute changes
P_aO_2	13 kPa (10–14)
P_aCO_2	4.8 kPa (4.7–6.0)

Which of the following is the most likely diagnosis?

A	Viral pericarditis
B	Viral myocarditis
C	Viral costochondritis
D	Hyperventilation syndrome
E	Pleurisy

21231

Submit

Previous Question | Skip Question

Calculator

Normal Values

© Pastest 2017

A 21-year-old comes to the Emergency room with symptoms of an upper respiratory tract infection and sharp stabbing chest pain over his left upper chest when he breathes in. He is usually well and is doing a degree in physical education. He is a non-smoker who only drinks small amounts of alcohol. On examination his BP is 135/70 mmHg, his temperature is 37.9°C, his pulse is 84/min and regular. Auscultation of the chest is clear, although there are some transmitted sounds from his upper respiratory tract infection. He has some limited anterior chest wall tenderness.

Investigations:

Hb	141 g/l (130-180)
WCC	8.2 × 10^9/l (4.0--1.0)
PLT	202 × 10^9/l (150–400)
Na^+	139 mmol/l (133–146)
K^+	4.5 mmol/l (3.5–5.3)
Creatinine	100 mol/l (55–120)
Chest X-Ray	No abnormalities seen
ECG	Sinus rhythm with a rate of 84; no acute changes
P_aO_2	13 kPa (10–14)
P_aCO_2	4.8 kPa (4.7–6.0)

Which of the following is the most likely diagnosis?

A Viral pericarditis

B Viral myocarditis

C Viral costochondritis

D Hyperventilation syndrome

E Pleurisy

Explanation

C Viral costochondritis

In the context of a young, previously well individual with a recent upper respiratory tract infection, normal ECG, normal CXR and normal ABG the history points towards viral costochondritis. Adequate analgesia is the most important component of successful treatment, with simple analgesia such as paracetamol combined with an appropriate non-steroidal. Without analgesia, the risk of atelectasis and consequent bacterial superinfection is increased.

A Viral pericarditis

Pericarditis classically presents with sharp, pleuritic chest pain which is relieved by sitting up and leaning forwards. Additionally, there may be a pericardial friction rub on auscultation. Classical ECG findings are widespread saddle-shaped ST-elevation. Patients may also develop a pericardial effusion.

The common viral causes of pericarditis include enteroviruses (e.g. Coxsackieviruses, echo- viruses); herpesviruses (e.g. Epstein–Barr virus, cytomegalovirus, human herpesvirus 6); adenoviruses, parvovirus B19. Non-infectious causes of pericarditis include auto-immune, neoplastic, metabolic, traumatic and drug related. NSAIDs are used in the treatment of pericarditis.

Reference: Imazio M, Gaita F, LeWinter M. Evaluation and treatment of pericarditis: A systematic review. *JAMA*. 2015;314(14):1498–1506. doi:10.1001/jama.2015.12763

B Viral myocarditis

Signs and symptoms of myocarditis include chest pain, general malaise, history consistent with a recent viral illness, congestive heart failure, arrhythmias, fever and sudden death. ECG changes include diffuse T-wave inversion and saddle-shaped ST-elevation. There are many causes of myocarditis, but viral infection is the most common. The gold standard diagnostic test is myocardial biopsy.

D Hyperventilation syndrome

In hyperventilation syndrome, the patient breathes rapidly causing P_aCO_2 to fall. This results in a respiratory alkalosis. Patients often describe chest pain, and tingling around the mouth and fingers. These features may accompany a panic attack.

E Pleurisy

Pleurisy describes inflammation of the pleura which causes sharp, stabbing pain when breathing. On auscultation of the chest it may be possible to hear a pleural friction rub.

212.31

Rate this question:

Next Question

Previous Question | Tag Question

Feedback | End Session

Difficulty: Average

Peer Responses %

Session Progress

Responses Correct:	0
Responses Incorrect:	111
Responses Total:	111
Responses - % Correct:	0%

Blog About Pastest Contact Us Help

© Pastest 2017

A 62-year-old retired office worker presents to the clinic with progressively increased shortness of breath on exercise and a chronic non-productive cough. On examination he looks tired and a little thin, his BMI is 21. His BP is 142/88 mmHg, pulse 78/min and regular. There are bibasal end-expiratory crackles on auscultation. He is clubbed and there is bilateral peripheral ankle oedema.

Investigations;

Hb	14.8 g/dl
WCC	7.9 $x10^9$/l
PLT	201 $x10^9$/l
Na^+	141 mmol/l
K^+	4.0 mmol/l
Creatinine	141 mol/l
Autoimmune profile	no specific abnormalities
PaO_2	7.9 kPa
$PaCO_2$	3.9 kPa
CXR	Interstitial shadowing at both lung bases
CT thorax	Suggests lung fibrosis

Which of the following is the most appropriate initial treatment?

A	N-acetylcysteine
B	High dose prednisolone
C	Low dose prednisolone
D	Cyclophosphamide
E	Long-term oxygen replacement therapy

21246

Submit

Previous Question | Skip Question

Calculator

Normal Values

© Pastest 2017

A 62-year-old retired office worker presents to the clinic with progressively increased shortness of breath on exercise and a chronic non-productive cough. On examination he looks tired and a little thin, his BMI is 21. His BP is 142/88 mmHg, pulse 78/min and regular. There are bibasal end-expiratory crackles on auscultation. He is clubbed and there is bilateral peripheral ankle oedema.

Investigations;

Hb	14.8 g/dl
WCC	7.9 $x10^9$/l
PLT	201 $x10^9$/l
Na^+	141 mmol/l
K^+	4.0 mmol/l
Creatinine	141 mol/l
Autoimmune profile	no specific abnormalities
PaO_2	7.9 kPa
$PaCO_2$	3.9 kPa
CXR	Interstitial shadowing at both lung bases
CT thorax	Suggests lung fibrosis

Which of the following is the most appropriate initial treatment?

A	N-acetylcysteine
B	High dose prednisolone
C	Low dose prednisolone
D	Cyclophosphamide
E	Long-term oxygen replacement therapy

Explanation

This man has strong evidence to support a diagnosis of idiopathic pulmonary fibrosis. There is nothing to suggest in his occupational history or in the blood results seen to suggest a diagnosis of connective tissue disease or occupational lung disease. Unfortunately trials of corticosteroids, potential disease modifying agents such as cyclophosphamide or methotrexate and novel therapies such as N-acetylcysteine have been uniformly disappointing although these agents are often trialled as a small proportion of patients may respond. He is however significantly hypoxic, as such home oxygen therapy may offer both symptom relief and affect prognosis with respect to secondary pulmonary hypertension and right heart failure.

21246

Rate this question:

Next Question

Previous Question | Tag Question

Feedback | End Session

Difficulty: Average

Peer Responses %

Session Progress

Responses Correct:	0
Responses Incorrect:	112
Responses Total:	112
Responses - % Correct:	0%

© Pastest 2017

A 71-year-old woman with a previous history of pulmonary tuberculosis presents to the respiratory clinic complaining of lethargy, weight loss, night sweats and intermittent haemoptysis. She has a history of hypertension managed with ramipril and indapamide, but is otherwise well. On examination, her BP is 142/87 mmHg, she is apyrexial and her BMI is 21. FEV_1 is 1.8 l.

Investigations:

Hb	131 g/l (115–165)
WCC	10.1×10^9/l (4.0–11.0)
PLT	233×10^9/l (150–400)
Na+	139 mmol/l (133–146)
K+	4.9 mmol/l (3.5–5.3)
Creatinine	130 μmol/l (55–120)
Chest X-ray	Left upper lobe cavity with rim of air surrounding a solid lesion
Aspergillus precipitant test	+
FEV_1	1.8 l

Which of the following is the most appropriate treatment for her?

A	IV amphotericin
B	Surgical resection
C	Bronchial artery embolisation
D	Voriconazole
E	Itraconazole

21247

Submit

Previous Question | Skip Question

Calculator

Normal Values

© Pastest 2017

A 71-year-old woman with a previous history of pulmonary tuberculosis presents to the respiratory clinic complaining of lethargy, weight loss, night sweats and intermittent haemoptysis. She has a history of hypertension managed with ramipril and indapamide, but is otherwise well. On examination, her BP is 142/87 mmHg, she is apyrexial and her BMI is 21. FEV_1 is 1.8 l.

Investigations:

Hb	131 g/l (115–165)
WCC	10.1 × 10^9/l (4.0–11.0)
PLT	233 × 10^9/l (150–400)
Na+	139 mmol/l (133–146)
K+	4.9 mmol/l (3.5–5.3)
Creatinine	130 μmol/l (55–120)
Chest X-ray	Left upper lobe cavity with rim of air surrounding a solid lesion
Aspergillus precipitant test	+
FEV_1	1.8 l

Which of the following is the most appropriate treatment for her?

A	IV amphotericin
B	Surgical resection
C	Bronchial artery embolisation
D	Voriconazole
E	Itraconazole

Explanation

B Surgical resection

Pulmonary aspergilloma is defined as a conglomeration of intertwined *Aspergillus* hyphae, fibrin, mucus and cellular debris within a pulmonary cavity or an ectatic bronchus. Patients usually have an underlying chronic lung condition. Surgical resection is curative in patients with aspergilloma who have an adequate reserve of lung function to enable them to undergo surgery; pre-existing lung disease may preclude thoracotomy. A preoperative FEV1 of >1.5 l for lobectomy and >2.0 l for pneumonectomy generally indicate suitability for resection procedures on the lungs. Postoperative complications include haemorrhage, bronchopleural fistulae and *Aspergillus* infection of the pleural space.

References: Walsh et al. Treatment of aspergillosis: Clinical Practice Guidelines of the Infectious Diseases Society of America. *Clin Infect Dis* 2008; 46(3):327–360. doi: 10.1086/525258

Gould and Pearce. Assessment of suitability for lung resection. *Contin Educ Anaesth Crit Care Pain* 2006; 6(3):97–100. doi: 10.1093/bjaceaccp/mkl016

A IV amphotericin

Amphotericin is not first-line treatment for aspergilloma. Amphotericin is associated with febrile reactions, renal failure and electrolyte disturbances.

C Bronchial artery embolisation

Where there is life-threatening haemoptysis, arterial embolisation may be another potential option. The management of massive haemoptysis is discussed in the following reference: Scott Weingart. EMCrit Podcast 199 – Management of Massive Hemoptysis with Oren Friedman. EMCrit Blog. Published 14 May 2017. Accessed 24 May 2017. Available at https://emcrit.org/podcasts/massive-hemoptysis/.

D Voriconazole

Voriconazole is s a triazole antifungal medication used to treat invasive aspergillosis, which may occur in immunocompromised patients. Visual disturbance is a reported side effect of voriconazole, and thus patients taking voriconazole should be advised against driving at night or other potentially hazardous tasks.

E Itraconazole

Itraconazole is a triazole antifungal medication. In patients whose lung function is too poor to tolerate surgical resection, long-term itraconazole therapy may be effective in reducing symptoms of haemoptysis and actually leading to resolution of the aspergilloma lesion in up to 60% of patients.

© Pastest 2017

A 38-year-old woman underwent a heart and lung transplantation for pulmonary hypertension. Whilst she was initially well post surgery she presents to the clinic some 15 months later with progressive shortness of breath. On examination her BP is 125/82 mmHg and there is wheeze on auscultation of her chest.

Investigations:

Hb	121 g/l (115–165)
WCC	4.9 $\times 10^9$/l (4.0–11.0)
PLT	184 $\times 10^9$/l (150–400)
Na^+	140 mmol/l (133–146)
K^+	4.0 mmol/l (3.5–5.3)
Urea	6.9 (2.5–7.8)
Creatinine	120 mol/l (55–120)
Pulmonary function tests	Obstructive picture, irreversible with salbutamol, worsening over the past 3 months

Which of the following is the most likely diagnosis?

A	Post-transplant lymphoproliferative disorder
B	Acute rejection
C	Bronchiolitis obliterans syndrome
D	New-onset asthma
E	Recurrence of pulmonary hypertension

21436

Submit

Previous Question | Skip Question

Calculator

Normal Values

© Pastest 2017

A 38-year-old woman underwent a heart and lung transplantation for pulmonary hypertension. Whilst she was initially well post surgery she presents to the clinic some 15 months later with progressive shortness of breath. On examination her BP is 125/82 mmHg and there is wheeze on auscultation of her chest.

Investigations:

Hb	121 g/l (115–165)
WCC	4.9 $\times 10^9$/l (4.0–11.0)
PLT	184 $\times 10^9$/l (150–400)
Na^+	140 mmol/l (133–146)
K^+	4.0 mmol/l (3.5–5.3)
Urea	6.9 (2.5–7.8)
Creatinine	120 mol/l (55–120)
Pulmonary function tests	Obstructive picture, irreversible with salbutamol, worsening over the past 3 months

Which of the following is the most likely diagnosis?

A Post-transplant lymphoproliferative disorder

B Acute rejection

C Bronchiolitis obliterans syndrome

D New-onset asthma

E Recurrence of pulmonary hypertension

Explanation

C Bronchiolitis obliterans syndrome

Bronchiolitis obliterans syndrome occurs due to progressive obliterative bronchiolitis affecting terminal bronchioles. The condition is manifest in increasing shortness of breath and a progressively worsening fixed airways obstruction picture on pulmonary function testing. Risk factors for the development of the condition include early acute rejection and CMV infection. Bronchiolitis obliterans has been seen as early as 3 months post-transplant, and is responsible for over 50% of deaths after the first year.

PAH is defined by a mean pulmonary artery pressure greater than 25 mmHg at rest and a normal pulmonary capillary wedge pressure of 15 mmHg or less with a pulmonary vascular resistance greater than 3 Wood units. Prior to lung transplantation being available, median survival for patients with pulmonary hypertension was 2.8 years.

A Post-transplant lymphoproliferative disorder

In this condition there is controlled B-cell proliferation due to the need for immunosuppressive therapy after transplantation. The clinical presentation can vary from simple lymphoid hyperplasia to aggressive disease that closely resembles non-Hodgkin's lymphoma. Post-transplant lymphoproliferative disorder is still a rare disease, despite being more commonly observed after lung transplantation than with other organs.

B Acute rejection

Acute rejection may occur any time from the first week after the transplant to 3 months afterwards. All recipients have some amount of acute rejection.

D New-onset asthma

In asthma, you would see obstructive spirometry, but you would expect reversibility with salbutamol.

E Recurrence of pulmonary hypertension

Recurrence of the disease is rare after transplantation.

21436

Rate this question:

Next Question

Previous Question | Tag Question

Feedback | End Session

Difficulty: Average

Peer Responses %

Session Progress

Responses Correct:	0
Responses Incorrect:	114
Responses Total:	114
Responses - % Correct:	0%

© Pastest 2017

A 64-year-old female presents to the Emergency Department with severe shortness of breath, fever, and a cough productive of rusty-coloured sputum. She has no past medical history. On auscultation of her chest, crackles are heard at the right base. Her blood pressure is 110/70 mmHg, she is tachycardic with a pulse rate of 101 beats per minute, her respiratory rate is 28 breaths per minute and she is pyrexial at 38.2°C.

Investigations:

Hb	121 g/l (115–165)
WCC	12.9 × 10^9/l (4.0–11.0)
PLT	204 × 10^9/l (150–400)
Na^+	140 mmol/l (133–146)
K^+	4.5 mmol/l (3.5–5.3)
Urea	9.0 mmol/l (2.5–7.8)
Creatinine	110 micromol/l (50 –120)
P_aO_2	8.2 kPa (11–13)
P_aCO_2	6.1 kPa (4.7–6.0)
EGG	Sinus tachycardia – 101 beats/min

Which of the following features in the clinical picture would contribute to an increased CURB-65 score in his case?

A	pO_2 8.2 kPa
B	pCO_2 5.9 kPa
C	WCC 12.9 × 10^9/l
D	Urea 9.0 mmol/l
E	Respiratory rate 28/min

21468

Submit

Previous Question | Skip Question

Calculator

Normal Values

© Pastest 2017

A 64-year-old female presents to the Emergency Department with severe shortness of breath, fever, and a cough productive of rusty-coloured sputum. She has no past medical history. On auscultation of her chest, crackles are heard at the right base. Her blood pressure is 110/70 mmHg, she is tachycardic with a pulse rate of 101 beats per minute, her respiratory rate is 28 breaths per minute and she is pyrexial at 38.2°C.

Investigations:

Hb	121 g/l (115–165)
WCC	12.9 × 10^9/l (4.0–11.0)
PLT	204 × 10^9/l (150–400)
Na^+	140 mmol/l (133–146)
K^+	4.5 mmol/l (3.5–5.3)
Urea	9.0 mmol/l (2.5–7.8)
Creatinine	110 micromol/l (50 –120)
P_aO_2	8.2 kPa (11–13)
P_aCO_2	6.1 kPa (4.7–6.0)
EGG	Sinus tachycardia – 101 beats/min

Which of the following features in the clinical picture would contribute to an increased CURB-65 score in his case?

A	pO_2 8.2 kPa
B	pCO_2 5.9 kPa
C	WCC 12.9 × 10^9/l
D	Urea 9.0 mmol/l
E	Respiratory rate 28/min

Explanation

D	Urea 9.0 mmol/l

The CURB-65 score is a simple additive score ranging from 0–5, based on the presence of confusion, urea, respiratory rate, blood pressure and age, which can be used to stratify patients with community-acquired pneumonia into different management groups.

Each of the following features score 1 point:
Confusion (<8/10 score on abbreviated mental teste (AMT))
Urea >7 mmol/l
Respiratory rate >30 breaths/min
Blood pressure – systolic <90 mmHg and/or diastolic <60 mmHg
Age > 65.

Patients with scores of 0 and 1 are at low risk of mortality (<2%) and might be suitable for management as hospital outpatients or by their general practitioner. Patients with a score of 2 are at intermediate risk of mortality (9%) and should be considered for hospital-supervised treatment. Patients with a score of >2 are at high risk of mortality (>19%). They should be treated in hospital. Initial care in an intensive care or high-dependency unit may be appropriate in those with the highest scores

A	pO_2 8.2 kPa

Hypoxaemia does not feature in the CURB-65 score. However, patients with hypoxaemia do have a worse prognosis.

B	pCO_2 5.9 kPa

Hypercapnia does not feature in the CURB-65 score. However, the presence of co-existing lung disease is a bad prognostic factor.

C	WCC 12.9 × 10^9/l

White cell count does not feature in the CURB-65 score. However, a white cell count above 12 × 10^9/l is a feature of the systemic inflammatory response syndrome (SIRS).

E	Respiratory rate 28/min

While respiratory rate does feature in the CURB-65 score, it does not add to the score unless the respiratory rate is >30 breaths/min

21468

Rate this question:

Next Question

Previous Question | Tag Question

Feedback | End Session

Difficulty: Average

Peer Responses %

Session Progress

Responses Correct:	0
Responses Incorrect:	115
Responses Total:	115
Responses - % Correct:	0%

External Links

Defining community acquired pneumonia severity on presentation to hospital...
ncbi.nlm.nih.gov/pubmed/12728155

© Pastest 2017

A 61-year-old male presents with a history of dull, aching right-sided chest pain, a cough and unintentional weight loss. He has a 50-pack-year smoking history. He recently retired from working as a plumber where he feels he is likely to have been exposed to asbestos through his working life. He also has a history of rheumatoid arthritis which is currently managed with non-steroidals and methotrexate. However, he remembers having an intravenous treatment in the past. On examination, he has a BMI of 20 and has dullness to percussion on the right side of this chest.

Investigations:

Hb	115 g/l (130–180)
WCC	10.2×10^9/l (4.0–11.0)
PLT	243×10^9/l (150–400)
Na^+	140 mmol/l (133–146)
K^+	4.5 mmol/l (3.5–5.3)
Creatinine	130 μmol/l (50–120)
Glucose	7.2 mmol/l (<7.0)
Pleural fluid LDH	>300
Pleural fluid protein	>30
Lymphocytes	1250/ml
Pleural fluid glucose	3.4 mmol/l
Cytology	No malignant cells seen
CXR	Extensive right sided pleural effusion

What is the most likely diagnosis?

A	Mesothelioma
B	Bronchogenic carcinoma
C	Lymphoma
D	Inflammatory effusion
E	Tuberculous effusion

21473

Submit

Previous Question | Skip Question

Calculator

Normal Values

© Pastest 2017

A 61-year-old male presents with a history of dull, aching right-sided chest pain, a cough and unintentional weight loss. He has a 50-pack-year smoking history. He recently retired from working as a plumber where he feels he is likely to have been exposed to asbestos through his working life. He also has a history of rheumatoid arthritis which is currently managed with non-steroidals and methotrexate. However, he remembers having an intravenous treatment in the past. On examination, he has a BMI of 20 and has dullness to percussion on the right side of this chest.

Investigations:

Hb	115 g/l (130–180)
WCC	10.2 × 10^9/l (4.0–11.0)
PLT	243 × 10^9/l (150–400)
Na^+	140 mmol/l (133–146)
K^+	4.5 mmol/l (3.5–5.3)
Creatinine	130 μ mol/l (50–120)
Glucose	7.2 mmol/l (<7.0)
Pleural fluid LDH	>300
Pleural fluid protein	>30
Lymphocytes	1250/ml
Pleural fluid glucose	3.4 mmol/l
Cytology	No malignant cells seen
CXR	Extensive right sided pleural effusion

What is the most likely diagnosis?

A Mesothelioma

B Bronchogenic carcinoma

C Lymphoma

D Inflammatory effusion

E Tuberculous effusion

Explanation

E Tuberculous effusion

For a full explanation, please see 'Investigation of a unilateral pleural effusion in adults: British Thoracic Society pleural disease guideline 2010', the weblink for wich is given below.

The marked pleural effusion lymphocytosis, coupled with elevated fluid protein and reduced glucose, suggests this is a tuberculous effusion. The suspicion is that he may have received anti-TNF therapy for his rheumatoid arthritis, which has led to reactivation of old TB. Tuberculous pleuritis is a type IV hypersensitivity reaction to mycobacterial protein, and the mycobacterial load in the pleural fluid is usually low. Pleural fluid microscopy for acid-fast bacilli has a sensitivity of <5% and pleural fluid culture of 10–20%. Thoracoscopic pleural biopsy has been shown to have a sensitivity of >70% for culture of pleural tissue, and overall diagnostic sensitivity approaches 100% when evidence of caseating granulomas on pleural biopsy histology is combined with culture.

A Mesothelioma

Pleural effusions in mesothelioma tend to have a normal LDH and <1000 white cells/ml. Pleural fluid mesothelin has been shown to have additional value beyond pleural fluid cytology in the diagnosis of mesothelioma. When possible, pleural tissue should be obtained to confirm a diagnosis of malignant mesothelioma.

B Bronchogenic carcinoma

Pleural effusions in mesothelioma tend to have a normal LDH and <1000 white cells/ml. Pleural fluid mesothelin has been shown to have additional value beyond pleural fluid cytology in the diagnosis of mesothelioma. When possible, pleural tissue should be obtained to confirm a diagnosis of malignant mesothelioma.

C Lymphoma

There may be a raised LDH in pleural effusions associated with lymphoma. Cytology is positive in around 40% of cases.

D Inflammatory effusion

An effusion with such a high lymphocyte count is atypical for a purely inflammatory effusion.

© Pastest 2017

A 38-year-old man with known alpha-1-antitrypsin deficiency presents to the hospital with a spontaneous right-sided pneumothorax. A chest drain is inserted, and initially appears to work correctly but is then noted to be swinging and bubbling. However, after 3 days the fluid level stops swinging and the nurses notice he has begun to develop surgical emphysema. He complains of renewed severe, right-sided pain. On examination, he has diminished breath sounds on the right and a resonant percussion note. You notice that the drain has been clamped. On further questioning it transpires that nursing staff had seen that the drain had stopped swinging.

Which of the following is the most appropriate next step?

A	Formal PA chest film
B	AP erect chest film
C	Lateral chest X-ray
D	Unclamp the drain
E	Pull the chest drain back by 1 cm

21483

Submit

Previous Question | Skip Question

Calculator

Normal Values

© Pastest 2017

A 38-year-old man with known alpha-1-antitrypsin deficiency presents to the hospital with a spontaneous right-sided pneumothorax. A chest drain is inserted, and initially appears to work correctly but is then noted to be swinging and bubbling. However, after 3 days the fluid level stops swinging and the nurses notice he has begun to develop surgical emphysema. He complains of renewed severe, right-sided pain. On examination, he has diminished breath sounds on the right and a resonant percussion note. You notice that the drain has been clamped. On further questioning it transpires that nursing staff had seen that the drain had stopped swinging.

Which of the following is the most appropriate next step?

A	Formal PA chest film
B	AP erect chest film
C	Lateral chest X-ray
D	Unclamp the drain
E	Pull the chest drain back by 1 cm

Explanation

D	Unclamp the drain

There is evidence to suggest that this patient is unstable, with renewed pain and surgical emphysema. It is possible that he has an air leak into the tissues around the insertion site. Transferring him to the radiology department may put him at significant risk. The optimal course of action is to unclamp the drain immediately and arrange for an urgent portable chest X-ray. Further management will be guided by the clinical and radiological findings after unclamping the drain and obtaining imaging.

A	Formal PA chest film

The patient in the scenario is unstable, and transferring the patient to the radiology department may put them at risk. After the drain has been unclamped, a portable chest X-ray will provide the required information in a safer and more timely manner.

B	AP erect chest film

Whilst a portable chest X-ray is required, the immediate management is to unclamp the drain as this may allow the pneumothorax to drain and prevent the situation from deteriorating further.

C	Lateral chest X-ray

As before, this would necessitate an intra-hospital transfer with an unstable patient and will not add anything additional that a portable chest X-ray can provide after the drain has been unclamped.

E	Pull the chest drain back by 1 cm

The safest thing to do is to unclamp the drain and obtain an urgent X-ray to assess position and clinical status. Depending on findings, the drain may need to be pulled back after reviewing the imaging, but it is not the initial step.

21483

Rate this question:

Next Question

Previous Question | Tag Question

Feedback | End Session

Difficulty: Average

Peer Responses %

Session Progress

Responses Correct:	0
Responses Incorrect:	117
Responses Total:	117
Responses - % Correct:	0%

© Pastest 2017

A 74-year-old male smoker with a 30-pack-year smoking history has an FEV1 of 40% predicted. He has successfully reduced his smoking habit to only 3 cigarettes per day with help from smoking cessation services. However, he can only walk 100 m at a time before he becomes out of breath and feels that he needs to stop. His medication includes an inhaled long-acting beta-agonist and tiotropium. On examination, his BP is 155/85 mmHg and he has coarse crackles and wheeze throughout both lung fields.

Investigations:

Hb	121 g/l (130–180)
WCC	5.9×10^9/l (4.0–11.0)
PLT	210×10^9/l (150–400)
Na^+	139 mmol/l (133–146)
K^+	4.9 mmol/l (3.5–5.3)
Creatinine	139 mol/l (50–120)
Bicarbonate	30 mmol/l (22–29)
pH	7.4 (7.35–7.45)
P_aO_2	10.1 kPa (11–13)
P_aCO_2	6.4 kPa (4.7–6.0)

Which would best improve his exercise tolerance?

A	Inhaled beclometasone
B	Inhaled salbutamol
C	Portable oxygen
D	Pulmonary rehabilitation
E	Smoking cessation

21484

Submit

Previous Question | Skip Question

Calculator

Normal Values

© Pastest 2017

A 74-year-old male smoker with a 30-pack-year smoking history has an FEV1 of 40% predicted. He has successfully reduced his smoking habit to only 3 cigarettes per day with help from smoking cessation services. However, he can only walk 100 m at a time before he becomes out of breath and feels that he needs to stop. His medication includes an inhaled long-acting beta-agonist and tiotropium. On examination, his BP is 155/85 mmHg and he has coarse crackles and wheeze throughout both lung fields.

Investigations:

Hb	121 g/l (130–180)
WCC	5.9 × 10^9/l (4.0–11.0)
PLT	210 × 10^9/l (150–400)
Na^+	139 mmol/l (133–146)
K^+	4.9 mmol/l (3.5–5.3)
Creatinine	139 mol/l (50–120)
Bicarbonate	30 mmol/l (22–29)
pH	7.4 (7.35–7.45)
P_aO_2	10.1 kPa (11–13)
P_aCO_2	6.4 kPa (4.7–6.0)

Which would best improve his exercise tolerance?

A Inhaled beclometasone

B Inhaled salbutamol

C Portable oxygen

D Pulmonary rehabilitation

E Smoking cessation

Explanation

D Pulmonary rehabilitation

Given his limited smoking habit, it is likely that a pulmonary rehabilitation programme will have more impact.

A Inhaled beclometasone

Low-dose inhaled corticosteroids have no impact on disease progression in COPD, although it appears that high-dose inhaled corticosteroids combined with a long-acting beta-2 agonist does reduce exacerbations, at the expense of increased pneumonia.

B Inhaled salbutamol

Salbutamol is not likely to impact significantly as most patients have very poor reversibility.

C Portable oxygen

His P_aO_2 is too high for portable oxygen to be of benefit.

E Smoking cessation

Smoking cessation will have some impact on exercise tolerance, but given his limited habit now, it is likely that a pulmonary rehabilitation programme will have more impact.

21484

Rate this question:

Next Question

Previous Question | Tag Question

Feedback | End Session

Difficulty: Average

Peer Responses %

Session Progress

Responses Correct:	0
Responses Incorrect:	118
Responses Total:	118
Responses - % Correct:	0%

External Links

Pulmonary rehabilitation in chronic obstructive pulmonary disease
sciencedirect.com/science/article/pii/S1745045407000329

© Pastest 2017

A 22-year-old woman with cystic fibrosis attends the chest clinic with her partner. They want to start a family before her health deteriorates. She has had several admissions to hospital over the past few years, but currently she feels relatively well. She works at a local estate agent. During a recent admission to hospital with an exacerbation of her cystic fibrosis, a sputum culture revealed a heavy growth of *Pseudomonas*, sensitive to ceftazidime.

Investigations:

Hb	124 g/l (115–165)
WCC	11.2 × 10^9/l (4.0–11.0)
PLT	197 × 10^9/l (150–400)
Na^+	139 mmol/l (133–146)
K^+	4.5 mmol/l (3.5–5.3)
Creatinine	110 mol/l (55–120)
FEV_1	72% of that predicted

Which of the following is the correct advice when it comes to getting pregnant?

A	She should be advised to never get pregnant
B	After treating the acute infection she still has a very high risk of dying/premature delivery of her child
C	After treating the acute infection she has a good chance of a successful pregnancy
D	She is unlikely to conceive due to thickening of the cervical mucus
E	The fact her periods started late indicates subfertility

21536

Submit

Previous Question | Skip Question

Calculator

Normal Values

© Pastest 2017

A 22-year-old woman with cystic fibrosis attends the chest clinic with her partner. They want to start a family before her health deteriorates. She has had several admissions to hospital over the past few years, but currently she feels relatively well. She works at a local estate agent. During a recent admission to hospital with an exacerbation of her cystic fibrosis, a sputum culture revealed a heavy growth of *Pseudomonas*, sensitive to ceftazidime.

Investigations:

Hb	124 g/l (115–165)
WCC	11.2 × 10^9/l (4.0–11.0)
PLT	197 × 10^9/l (150–400)
Na^+	139 mmol/l (133–146)
K^+	4.5 mmol/l (3.5–5.3)
Creatinine	110 mol/l (55–120)
FEV_1	72% of that predicted

Which of the following is the correct advice when it comes to getting pregnant?

A She should be advised to never get pregnant

B After treating the acute infection she still has a very high risk of dying/premature delivery of her child

C After treating the acute infection she has a good chance of a successful pregnancy

D She is unlikely to conceive due to thickening of the cervical mucus

E The fact her periods started late indicates subfertility

Explanation

C After treating the acute infection she has a good chance of a successful pregnancy

Evidence is difficult to evaluate with respect to cystic fibrosis and successful pregnancy. Around 98% of men with CF will be infertile, but the effect of CF on fertility in women is not so clear-cut. The first successful pregnancy in a woman with cystic fibrosis occurred in 1960, and since then increasing number of children have been born to mothers with CF.

A She should be advised to never get pregnant

Pregnancy can be well tolerated in those with mild disease, but in patients whose lung function is poor there is increased likelihood of infant prematurity and death. There may also be loss of maternal lung function with accelerated decline following pregnancy.

B After treating the acute infection she still has a very high risk of dying/premature delivery of her child

Observational studies suggest that patients with an FEV1 <60% predicted have a much worse outcome both with respect to their own health status and the viability of the pregnancy, and that chronic *Pseudomonas* infection and multiple exacerbations do much worse.

D She is unlikely to conceive due to thickening of the cervical mucus

Despite the fact that cervical mucus is thicker, this does not appear to impact significantly on ability to become pregnant. CFTR is found in large quantities on the cervix, which means that cervical mucus remains thick throughout the menstrual cycle.

E The fact her periods started late indicates subfertility

Even though menstruation tends to begin later in CF, this does not appear to impact significantly on ability to get pregnant.

21536

Rate this question:

Next Question

Previous Question | Tag Question

Feedback | End Session

Difficulty: Average

Peer Responses %

Session Progress

Responses Correct:	0
Responses Incorrect:	119
Responses Total:	119
Responses - % Correct:	0%

External Links

Women with cystic fibrosis and their potential for reproduction
thorax.bmj.com/content/56/8/649

© Pastest 2017

A man with a history of COPD who is on home oxygen therapy is admitted to hospital with central chest pain. He suffers a cardiac arrest in the Emergency Department and is resuscitated for 23 min before return of spontaneous circulation. During resuscitation he was intubated, and he is now able to achieve adequate minute ventilation with minimal pressure support. His BP is 96/50 mmHg, HR 80, RR16, SpO_2 98% with an F_iO_2 of 0.6. Arterial blood gases are taken 3 min after ROSC.

Which of the following results are most likely to be shown on arterial blood gas analysis?

A	pH 7.45 P_aO_2 7.9 kPa P_aCO_2 3.1 HCO_3^- 31 mmol/l
B	pH 7.30 P_aO_2 7.9 kPa P_aCO_2 4.2 HCO_3^- 12 mmol/l
C	pH 7.15 P_aO_2 12.2 kPa P_aCO_2 4.3 HCO_3^- 17 mmol/l
D	pH 7.55 P_aO_2 12.2 kPa P_aCO_2 4.3 HCO_3^- 31 mmol/l
E	pH 7.10 P_aO_2 7.9 kPa P_aCO_2 4.3 HCO_3^- 12 mmol/l

21544

Submit

Previous Question | Skip Question

Calculator

Normal Values

© Pastest 2017

A man with a history of COPD who is on home oxygen therapy is admitted to hospital with central chest pain. He suffers a cardiac arrest in the Emergency Department and is resuscitated for 23 min before return of spontaneous circulation. During resuscitation he was intubated, and he is now able to achieve adequate minute ventilation with minimal pressure support. His BP is 96/50 mmHg, HR 80, RR16, SpO_2 98% with an F_iO_2 of 0.6. Arterial blood gases are taken 3 min after ROSC.

Which of the following results are most likely to be shown on arterial blood gas analysis?

A	pH 7.45 P_aO_2 7.9 kPa P_aCO_2 3.1 HCO_3^- 31 mmol/l
B	pH 7.30 P_aO_2 7.9 kPa P_aCO_2 4.2 HCO_3^- 12 mmol/l
C	pH 7.15 P_aO_2 12.2 kPa P_aCO_2 4.3 HCO_3^- 17 mmol/l
D	pH 7.55 P_aO_2 12.2 kPa P_aCO_2 4.3 HCO_3^- 31 mmol/l
E	pH 7.10 P_aO_2 7.9 kPa P_aCO_2 4.3 HCO_3^- 12 mmol/l

Explanation

C	pH 7.15 P_aO_2 12.2 kPa P_aCO_2 4.3 HCO_3^- 17 mmol/l

This man has COPD requiring home oxygen. As such, he is likely to have chronic CO_2 retention and will consequently have significant renal compensation and an elevated serum bicarbonate. Given that he has suffered a significant period of cardiac arrest, it is also likely that he will have significant tissue hypoxia, leading to a build-up of products of metabolism such as lactate. This leads to the decreased pH. In patients who have suffered a cardiac arrest there is usually a significant metabolic acidosis with a low bicarbonate level. However, due to pre-existing renal compensation, the bicarbonate in this patient will not be as low as if there was no previous renal compensation. In the absence of previous renal compensation, a bicarbonate of the levels seen in B) or E), would be expected. The pressure support on the ventilator allows him to achieve adequate gas exchange.

A	pH 7.45 P_aO_2 7.9 kPa P_aCO_2 3.1 HCO_3^- 31 mmol/l

In post-arrest patients we expect to see a metabolic acidosis.

B	pH 7.30 P_aO_2 7.9 kPa P_aCO_2 4.2 HCO_3^- 12 mmol/l

The degree of acidaemia in this patient is likely to be worse, but the bicarbonate is likely to be higher due to previous renal compensation.

D	pH 7.55 P_aO_2 12.2 kPa P_aCO_2 4.3 HCO_3^- 31 mmol/l

A metabolic alkalosis is not realistic in this scenario.

E	pH 7.10 P_aO_2 7.9 kPa P_aCO_2 4.3 HCO_3^- 12 mmol/l

The bicarbonate is likely to be higher due to previous renal compensation.

21544

Rate this question:

Next Question

Previous Question | Tag Question

Feedback | End Session

Difficulty: Average

Peer Responses %

Session Progress

Responses Correct:	0
Responses Incorrect:	120
Responses Total:	120
Responses - % Correct:	0%

Blog About Pastest Contact Us Help

© Pastest 2017

A 19-year-old man presents to the Emergency Department with a 3-day history of minor right-sided chest discomfort and lethargy. He smokes 20 cigarettes a day. A chest X-ray is obtained which shows a right-sided pneumothorax that is <1 cm from the chest wall. He is not distressed and he is not in significant pain. His oxygen saturation is 98% on air, his BP is 124/82 mmHg and his pulse is 81/min and regular.

How should he be managed?

A	Pleural aspiration
B	Small-bore chest drain insertion
C	Oxygen therapy
D	Outpatient clinic review
E	Large-bore chest drain insertion

21545

Submit

Previous Question | Skip Question

Calculator

Normal Values

© Pastest 2017

A 19-year-old man presents to the Emergency Department with a 3-day history of minor right-sided chest discomfort and lethargy. He smokes 20 cigarettes a day. A chest X-ray is obtained which shows a right-sided pneumothorax that is <1 cm from the chest wall. He is not distressed and he is not in significant pain. His oxygen saturation is 98% on air, his BP is 124/82 mmHg and his pulse is 81/min and regular.

How should he be managed?

A	Pleural aspiration
B	Small-bore chest drain insertion
C	Oxygen therapy
D	Outpatient clinic review
E	Large-bore chest drain insertion

Explanation

D	Outpatient clinic review

In a patient under the age of 50 without evidence of pre-existing lung disease, this is a primary pneumothorax. As the pneumothorax is <1 cm from the chest wall, it is reasonable to consider discharging the patient for review in the outpatient clinic.

A	Pleural aspiration

Primary pneumothoracies which are >2 cm from the chest wall, or are associated with breathlessness, should be aspirated. Secondary pneumothoarcies which are 1–2 cm from the chest wall should be aspirated.

B	Small-bore chest drain insertion

In primary or secondary pnemothoracies where aspiration was initially indicated but has failed, and in secondary pneumothoracies >2 cm from the chest wall, insertion of an 8–14 F chest drain is indicated.

C	Oxygen therapy

Admission for high-flow oxygen therapy is indicated in secondary pneumothoracies <1 cm from the chest wall, or where aspiration has reduced the pneumothorax to this size. Care needs to be taken where there is oxygen sensitivity.

E	Large-bore chest drain insertion

Large-bore chest drains are usually greater than 20 F. Such drains are indicated in haemothoracies and complex empyema.

21545

Rate this question:

Next Question

Previous Question | Tag Question

Feedback | End Session

Difficulty: Average

Peer Responses %

Session Progress

Responses Correct:	0
Responses Incorrect:	121
Responses Total:	121
Responses - % Correct:	0%

External Links

Management of spontaneous pneumothorax: British Thoracic Society pleural ...
thorax.bmj.com/content/thoraxjnl/65/Suppl_2/ii18.full.pdf

© Pastest 2017

A 52-year-old woman with a long history of asthma comes to clinic for review. She is currently taking 500 mcg fluticasone inhaled BD and salbutamol PRN. She complains of a further exacerbation and you prescribe her oral prednisolone. This is her eighth course of oral steroids over the past three years. Other history of note includes vertebral fractures diagnosed following an episode of acute pain some 3 months ago. On auscultation of her chest there is a wheeze throughout both lung fields.

Investigations:

Hb	12.3 g/dl
WCC	5.3 x10^9/l
PLT	201 x10^9/l
Na^+	139 mmol/l
K^+	4.5 mmol/l
Creatinine	120 mol/l
T score	- 2.0
PEFR	70% predicted

Which of the following is the most appropriate next long-term intervention for her asthma?

A	Regular low-dose prednisolone
B	Oral theophylline
C	Addition of a long-acting beta agonist
D	Montelukast
E	Inhaled atrovent

21569

Submit

Previous Question | Skip Question

Calculator

Normal Values

© Pastest 2017

A 52-year-old woman with a long history of asthma comes to clinic for review. She is currently taking 500 mcg fluticasone inhaled BD and salbutamol PRN. She complains of a further exacerbation and you prescribe her oral prednisolone. This is her eighth course of oral steroids over the past three years. Other history of note includes vertebral fractures diagnosed following an episode of acute pain some 3 months ago. On auscultation of her chest there is a wheeze throughout both lung fields.

Investigations:

Hb	12.3 g/dl
WCC	5.3 $x10^9$/l
PLT	201 $x10^9$/l
Na^+	139 mmol/l
K^+	4.5 mmol/l
Creatinine	120 mol/l
T score	– 2.0
PEFR	70% predicted

Which of the following is the most appropriate next long-term intervention for her asthma?

A	Regular low-dose prednisolone
B	Oral theophylline
C	Addition of a long-acting beta agonist
D	Montelukast
E	Inhaled atrovent

Explanation

C Addition of a long-acting beta agonist

This patient may well benefit from the addition of a LABA, which may improve her control and make it possible to reduce either her inhaled steroid dose or the frequency of exacerbations. Addition of a LABA is the next stage in the escalation of treatment as per the BTS/SIGN guideline.

A Regular low-dose prednisolone

This patient has already had eight courses of steroids over three years and has developed side effects from this treatment in the form of osteoporosis, as evidenced by the vertebral fractures. Her asthma remains poorly controlled and regular steroids are unlikely to change this.

B Oral theophylline

Theophyllines are only indicated following a trial and inadequate improvement with a LABA. The evidence for use of theophylline is improvement in symptoms, rather than a steroid-sparing effect.

D Montelukast

Montelukast is a leukotriene receptor antagonist. Like theophylline, it is a fourth-line agent that may be of benefit should the LABA not improve her symptoms.

E Inhaled atrovent

Atrovent is ipratropium bromide, a short-acting bronchodilator. It has a role in acute management of asthma but will not be of help in prevention of attacks.

21569

Rate this question:

Next Question

Previous Question | Tag Question

Feedback | End Session

Difficulty: Average

Peer Responses %

Session Progress

Responses Correct:	0
Responses Incorrect:	122
Responses Total:	122
Responses - % Correct:	0%

External Links

British guideline on the management of asthma
brit-thoracic.org.uk/document-library/clinical-information/asthma/btssign-asthma-g...

© Pastest 2017

A 70-year-old man with type 2 diabetes was admitted from a care home with a cough, fever and chest pain. He has been managed with IV co-amoxiclav for 4 days but is not improving. Other medication of note includes ramipril, atorvastatin, aspirin and mixed insulin BD.

On examination he is pyrexial at 38.5°C, with BP 100/60 mmHg and pulse 95/min. Auscultation of the chest reveals coarse crackles at the right base consistent with continuing pneumonia.

Investigations:

Hb	12.1 g/dl
WCC	13.4 $x10^9$/l
PLT	231 $x10^9$/l
Na^+	139 mmol/l
K^+	4.9 mmol/l
Creatinine	145 mol/l
Glucose	12.1 mmol/l
Sputum culture	MRSA sensitive to fusidic acid, gentamycin, vancomycin and rifampicin, resistant to co-amoxiclav

Which of the following is the most appropriate treatment?

A	Continue co-amoxiclav
B	Add oral fusidic acid
C	Switch to oral rifampicin
D	Switch to IV vancomycin
E	Add IV gentamycin

23313

Submit

Previous Question | Skip Question

Calculator

Normal Values

© Pastest 2017

A 70-year-old man with type 2 diabetes was admitted from a care home with a cough, fever and chest pain. He has been managed with IV co-amoxiclav for 4 days but is not improving. Other medication of note includes ramipril, atorvastatin, aspirin and mixed insulin BD.

On examination he is pyrexial at 38.5°C, with BP 100/60 mmHg and pulse 95/min. Auscultation of the chest reveals coarse crackles at the right base consistent with continuing pneumonia.

Investigations:

Hb	12.1 g/dl
WCC	13.4 x10^9/l
PLT	231 x10^9/l
Na^+	139 mmol/l
K^+	4.9 mmol/l
Creatinine	145 mol/l
Glucose	12.1 mmol/l
Sputum culture	MRSA sensitive to fusidic acid, gentamycin, vancomycin and rifampicin, resistant to co-amoxiclav

Which of the following is the most appropriate treatment?

A	Continue co-amoxiclav
B	Add oral fusidic acid
C	Switch to oral rifampicin
D	Switch to IV vancomycin
E	Add IV gentamycin

Explanation

D Switch to IV vancomycin

This man has nosocomial pneumonia, most likely acquired from his care home. The usual dose for vancomycin is 1 g BD 12-hourly, or 15 mg/kg. Vancomycin is effective as a single agent. It is only effective IV for this indication, due to poor absorption from the GI tract. It is implicated in nephrotoxicity and this patient already has a degree of renal impairment. Along with commencing vancomycin and careful monitoring during its use, other changes should be made to his medications and measures to prevent further decline in his renal function should be taken.

A Continue co-amoxiclav

The patient has failed to improve on this agent and the sputum culture has proven resistance to it. Persisting with this would be detrimental to the patient and increase the risk of antibiotic resistance.

B Add oral fusidic acid

Widespread use of topical fusidic acid has encouraged the development of *S. aureus* resistance and therefore the use of fusidic acid alone as an anti-staphylococcal agent is not recommended.

C Switch to oral rifampicin

Oral rifampicin is an option for MRSA, but it is associated with rapid development of resistance when used as a single agent.

E Add IV gentamycin

Although the sputum culture has shown that the MRSA in this case is sensitive to gentamicin, this patient already has a degree of renal failure and therefore gentamicin is contraindicated. There would also be no sense in continuing the co-amoxiclav.

© Pastest 2017

A 71-year-old patient undergoes radical surgery for an oesophageal adenocarcinoma with oesophagectomy, gastrectomy and splenectomy. Initially he makes a good recovery but you are asked to review him a few days later because he is increasingly short of breath. On examination BP is 142/72 mmHg and pulse 79/min and regular. There is reduced expansion of the left side of the chest and dullness to percussion over the left lung fields.

Investigations:

Hb	10.9 g/dl
WCC	7.9 x109/l
PLT	172 x109/l
Na^+	139 mmol/l
K^+	4.2 mmol/l
Creatinine	105 mol/l
CXR	Large left sided pleural effusion
Diagnostic tap	milky coloured effusion, protein content 48g/l

Which of the following investigations on the pleural fluid is most likely to contribute to confirming the underlying diagnosis?

A	Triglycerides
B	LDH
C	Culture and sensitivity
D	pH
E	Glucose

23330

Submit

Previous Question | Skip Question

Calculator

Normal Values

© Pastest 2017

A 71-year-old patient undergoes radical surgery for an oesophageal adenocarcinoma with oesophagectomy, gastrectomy and splenectomy. Initially he makes a good recovery but you are asked to review him a few days later because he is increasingly short of breath. On examination BP is 142/72 mmHg and pulse 79/min and regular. There is reduced expansion of the left side of the chest and dullness to percussion over the left lung fields.

Investigations:

Hb	10.9 g/dl
WCC	7.9 x109/l
PLT	172 x109/l
Na^+	139 mmol/l
K^+	4.2 mmol/l
Creatinine	105 mol/l
CXR	Large left sided pleural effusion
Diagnostic tap	milky coloured effusion, protein content 48g/l

Which of the following investigations on the pleural fluid is most likely to contribute to confirming the underlying diagnosis?

A	Triglycerides
B	LDH
C	Culture and sensitivity
D	pH
E	Glucose

Explanation

A	Triglycerides

A triglyceride level greater than 1.2 mmol/l indicates a 99% chance that the fluid in the pleural space is chyle. This is likely to be a complication of surgery, with intra-operative damage to the duct or one of its tributaries. This can cause up to 4 l of fluid per day to leak into the pleural space, leading to the classic symptoms of a large pleural effusion. Initial management is conservative as the thoracic duct leak reduces spontaneously over a few days. If the effusion persists, imaging is needed, with referral for surgical ligation as indicated.

B	LDH

LDH is used to distinguish an exudate from a transudate, and is therefore utilised to elucidate the cause of pleural effusion when heart failure versus inflammation or infection needs to be delineated. It is often done as part of the routine tests on pleural fluid, but will not be the most useful in confirming the underlying diagnosis.

C	Culture and sensitivity

This would identify the organism in an infective pleural effusion but would not aid the diagnosis here.

D	pH

Testing the acidity of pleural fluid is used as a guide to treatment in para-pneumonic and malignant pleural effusions: a pH of <7.2 in the former indicates the need to drain, and <7.3 in the latter is associated with worse outcome. Neither is relevant in this clinical scenario.

E	Glucose

Glucose levels are of value in para-pneumonic effusions and identify causes such as tuberculosis or malignancy.

23330

Rate this question:

Next Question

Previous Question | Tag Question

Feedback | End Session

Difficulty: Average

Peer Responses %

Session Progress

Responses Correct:	0
Responses Incorrect:	124
Responses Total:	124
Responses - % Correct:	0%

© Pastest 2017

A 68-year-old man who has a history of asthma is admitted to hospital with severe community acquired pneumonia. You understand that he has a part time job in a pet shop. He is severely hypoxic on admission and is transferred immediately to the ITU. He is treated with meropenem and Tazocin, but after 5 days is still pyrexial and requiring significant inotropic and ventilatory support.

Investigations;

Hb	11.9 g/dl
WCC	13.2 $x10^9$/l
PLT	221 $x10^9$/l
Na^+	135 mmol/l
K^+	4.5 mmol/l
Creatinine	145 mol/l
CRP	82 mg/l (<10)
CXR	Left lower lobe consolidation

Which of the following is the most likely diagnosis?

A	Aspergillus
B	Staphylococcus aureus
C	Streptococcus pneumoniae
D	Klebsiella pneumoniae
E	Chlamydia psittaci

23355

Submit

Previous Question | Skip Question

Calculator

Normal Values

© Pastest 2017

A 68-year-old man who has a history of asthma is admitted to hospital with severe community acquired pneumonia. You understand that he has a part time job in a pet shop. He is severely hypoxic on admission and is transferred immediately to the ITU. He is treated with meropenem and Tazocin, but after 5 days is still pyrexial and requiring significant inotropic and ventilatory support.

Investigations;

Hb	11.9 g/dl
WCC	13.2 x10^9/l
PLT	221 x10^9/l
Na^+	135 mmol/l
K^+	4.5 mmol/l
Creatinine	145 mol/l
CRP	82 mg/l (<10)
CXR	Left lower lobe consolidation

Which of the following is the most likely diagnosis?

A	Aspergillus
B	Staphylococcus aureus
C	Streptococcus pneumoniae
D	Klebsiella pneumoniae
E	Chlamydia psittaci

Explanation

The suspicion is that the poor response to broad spectrum antibiotics is either indicative of infection with an atypical pneumonia such as Chlamydia or the possibility of fungal infection. The chest x-ray appearance however is more typical of Chlamydia than Aspergillus. Tetracyclines are the therapy of choice for Chlamydia pneumonia, with macrolides the second option although there are a significant percentage of treatment failures on erythromycin. The other clue in the history to this man's underlying diagnosis is the fact that he works in a pet shop and may have had exposure to bird faeces.

23355

Rate this question:

Next Question

Previous Question | Tag Question

Feedback | End Session

Difficulty: Average

Peer Responses %

Session Progress

Responses Correct:	0
Responses Incorrect:	125
Responses Total:	125
Responses - % Correct:	0%

© Pastest 2017

A 27-year-old woman presents with right-sided pleuritic chest pain. She says the pain came on suddenly while lifting her son into his push-chair some 30 h earlier. Her only medication of note is the oral contraceptive pill, and she is usually fit and well. The symptoms have largely resolved and she has not taken paracetamol for some 6 h.

On examination, BP is 120/70 mmHg, pulse 80/min and regular, breath sounds seem normal and O_2 saturation on air is 97%.

Investigations:

Hb	12.9 g/dl
WCC	8.2 $x10^9$/l
PLT	192 $x10^9$/l
Na^+	138 mmol/l
K^+	4.3 mmol/l
Creatinine	110 mol/l
CXR	Small right pneumothorax – rim less than 1cm

Which of the following is the most appropriate next course of action?

A	Send home with a plan for early review
B	Admit for observation and oxygen therapy
C	Admit for air aspiration
D	Admit for formal chest drain insertion
E	Admit for thoracoscopy

27768

Submit

Previous Question | Skip Question

Calculator

Normal Values

© Pastest 2017

A 27-year-old woman presents with right-sided pleuritic chest pain. She says the pain came on suddenly while lifting her son into his push-chair some 30 h earlier. Her only medication of note is the oral contraceptive pill, and she is usually fit and well. The symptoms have largely resolved and she has not taken paracetamol for some 6 h.

On examination, BP is 120/70 mmHg, pulse 80/min and regular, breath sounds seem normal and O_2 saturation on air is 97%.

Investigations:

Hb	12.9 g/dl
WCC	8.2 x10^9/l
PLT	192 x10^9/l
Na^+	138 mmol/l
K^+	4.3 mmol/l
Creatinine	110 mol/l
CXR	Small right pneumothorax – rim less than 1cm

Which of the following is the most appropriate next course of action?

A Send home with a plan for early review

B Admit for observation and oxygen therapy

C Admit for air aspiration

D Admit for formal chest drain insertion

E Admit for thoracoscopy

Explanation

A Send home with a plan for early review

This woman has a pneumothorax which is more than 1 day old, and the chest X-ray indicates that the size is small. Given that her symptoms are improving, it would be most appropriate to discharge her with a plan to review in the respiratory clinic, or to return if her pain significantly worsens. Air aspiration might be considered for a larger pneumothorax, whereas formal chest drain insertion would be indicated if the pneumothorax was larger and there was a previous history of chest disease.

B Admit for observation and oxygen therapy

The patient's oxygen saturations are 97% on air, so there is no indication for supplemental oxygen. As this is a spontaneous pneumothorax in an otherwise well patient

C Admit for air aspiration

In the case of a primary spontaneous pneumothorax, air aspiration is only indicated if the pneumothorax is >2 cm and/or the patient is breathless. If this fails to resolve the symptoms or the pneumothorax does not decrease in size, then formal chest drain insertion would be needed.

D Admit for formal chest drain insertion

Formal chest drain insertion is only indicated in symptomatic/>2 cm primary spontaneous pneumothorax where aspiration has failed. It is first line if there is underlying lung disease and the patient is breathless or the pneumothorax is >2 cm in size.

E Admit for thoracoscopy

Thoracoscopy is usually performed to investigate pleural disease or in preparation for pleurodesis. This patient has had a spontaneous pneumothorax and there is no current suspicion of underlying lung disease. The annual incidence of primary spontaneous pneumothorax is around 5/100,000 in women and around 25/100,000 in men. The greatest risk factor is smoking.

© Pastest 2017

A 23-year-old African-Caribbean patient develops painful red nodules on both her shins over 2 days and has noticed painful knees, ankles and wrists. She also complains of mild sweats and weight loss over the past 2 months. Chest X-ray shows bilateral hilar lymphadenopathy (BHL) but clear lung fields.

Given the likely clinical diagnosis, what is the most likely outcome for her?

A	Complete remission after a course of steroids
B	Spontaneous resolution with no long-term sequelae
C	Spontaneous resolution followed by further relapses
D	Peripheral lung infiltrates and shortness of breath
E	Increasing weight loss and neurological impairment

31663

Submit

Previous Question Skip Question

Calculator

Normal Values

Blog About Pastest Contact Us Help

© Pastest 2017

A 23-year-old African-Caribbean patient develops painful red nodules on both her shins over 2 days and has noticed painful knees, ankles and wrists. She also complains of mild sweats and weight loss over the past 2 months. Chest X-ray shows bilateral hilar lymphadenopathy (BHL) but clear lung fields.

Given the likely clinical diagnosis, what is the most likely outcome for her?

A	Complete remission after a course of steroids
B	Spontaneous resolution with no long-term sequelae
C	Spontaneous resolution followed by further relapses
D	Peripheral lung infiltrates and shortness of breath
E	Increasing weight loss and neurological impairment

Explanation

B	Spontaneous resolution with no long-term sequelae

This patient has acute sarcoidosis with erythema nodosum, polyarthralgia and mild constitutional symptoms. Around 90% patients have BHL at presentation. In 10–20% of cases, symptoms progress to shortness of breath, dry cough and chest pain. The majority of patients (80%) either stabilise or regress, so in the first instance treatment is not indicated. Non-pulmonary manifestations include neuropathy, Bell's palsy, hepatosplenomegaly, uveitis, conjunctivitis, lupus pernio, subcutaneous nodules, cardiomyopathy, arrhythmias, hypercalcaemia and renal stones. Treatment of acute sarcoidosis is usually supportive, including non-steroidal anti-inflammatory drugs (NSAIDs) for polyarthralgia, because most recover spontaneously.

A	Complete remission after a course of steroids

Sarcoidosis usually resolves spontaneously and steroids at first presentation would not be indicated. Steroids should be commenced if: symptoms worsen or cause limitation to daily activities, pulmonary function deteriorates, CXR signs worsen (e.g. development of cavitation or fibrosis) or if other organ system involvement develops.

C	Spontaneous resolution followed by further relapses

Most patients recover spontaneously, and in 90% this is within 2 years. Less than 10% develop relapses after this point. Relapses and chronic disease are more likely if spontaneous remission does not occur within the first 2 years.

D	Peripheral lung infiltrates and shortness of breath

The extent of infiltrates on CXR is used in staging of the disease and is a guide to prognosis, with the likelihood of relapse increasing as the extent of infiltrate worsens. This option is incorrect because it is uncommon.

E	Increasing weight loss and neurological impairment

Neurological involvement does occur with sarcoidosis, but this is rare, occurring in 5-15% of patients. Neurological involvement tends to be present at presentation and often in disease with other significant extra-pulmonary features. This option is incorrect because it is an uncommon outcome.

31663

Rate this question:

Next Question

Previous Question | Tag Question

Feedback | End Session

Difficulty: Average

Peer Responses %

Session Progress

Responses Correct:	0
Responses Incorrect:	127
Responses Total:	127
Responses - % Correct:	0%

© Pastest 2017

A 73-year-old man is sent to the Emergency Department by ambulance after a GP home visit. The GP found him to be extremely short of breath with a cough productive of rusty-coloured sputum. He has herpetic lesions at the corner of his mouth. On examination he has right-sided crackles and bronchial breathing consistent with pneumonia.

You use the British Thoracic Society Community Acquired Pneumonia Severity Score (CURB-65) criteria to assess the severity of infection with respect to the need for HDU/ITU.

Which one of the following features would be consistent with severe pneumonia by CURB-65 criteria?

A	Urea 9.2 mmol/l
B	Systolic BP 105 mmHg
C	Diastolic BP 65 mmHg
D	Presence of X-ray changes
E	Raised ESR

32332

Submit

Previous Question Skip Question

Calculator

Normal Values

Blog About Pastest Contact Us Help

© Pastest 2017

A 73-year-old man is sent to the Emergency Department by ambulance after a GP home visit. The GP found him to be extremely short of breath with a cough productive of rusty-coloured sputum. He has herpetic lesions at the corner of his mouth. On examination he has right-sided crackles and bronchial breathing consistent with pneumonia.

You use the British Thoracic Society Community Acquired Pneumonia Severity Score (CURB-65) criteria to assess the severity of infection with respect to the need for HDU/ITU.

Which one of the following features would be consistent with severe pneumonia by CURB-65 criteria?

A	Urea 9.2 mmol/l
B	Systolic BP 105 mmHg
C	Diastolic BP 65 mmHg
D	Presence of X-ray changes
E	Raised ESR

Explanation

A	Urea 9.2 mmol/l

The British Thoracic Society Community Acquired Pneumonia Severity Score (CURB-65) uses five variables where a point is scored for each one. It is a mortality score.

The variables are:

- confusion (AMT of 8 or less);
- urea >7 mmol/l;
- respiratory rate 30/min or greater;
- systolic blood pressure 90 mmHg or less or diastolic BP 60 mmHg or less;
- age >65

A score of 3 is associated with a risk of mortality of 17% from community-acquired pneumonia; for 5 this rises to a risk of mortality of 57%. These data are extrapolated to give a guide as to whether and where the patient should be admitted: those with a score of 0 or 1 may safely be managed at home, 2 should receive hospital care, while HDU/ITU should be considered for a score of 3 or more. This is a guide and should not replace clinical judgement.

B	Systolic BP 105 mmHg

This blood pressure does not fit the criteria, although may be of concern depending on his other clinical observations.

C	Diastolic BP 65 mmHg

Again, though this does not fulfil the criteria of CURB-65, it may be of clinical importance. CURB-65 is a guide to likely mortality and is used for this reason as a pointer towards the requirement for ITU/HDU admission. It is not, however, a management guide.

D	Presence of X-ray changes

X-ray changes are not involved in these prognostic criteria, though may be of diagnostic and prognostic value.

E	Raised ESR

ESR is not routinely measured in community-acquired pneumonia.

32332

Rate this question:

Next Question

Previous Question | Tag Question

Feedback | End Session

Difficulty: Average

Peer Responses %

Session Progress

Responses Correct:	0
Responses Incorrect:	128
Responses Total:	128
Responses - % Correct:	0%

External Links

NICE guidance
nice.org.uk/guidance/cg191/chapter/1-recommendations#community-acquired-pneu...

© Pastest 2017

You admit a 73-year-old man to the Emergency Department. He has had influenza over the past few days and has a worsening cough productive of purulent, blood-stained sputum. Observations: BP 122/72 mmHg, pulse 90/min and regular, respiratory rate 28/min. There are signs of right lower lobe pneumonia. A routine blood screen including arterial blood gas is performed.

Which one of the following features on admission is likely to be associated with a poorer prognosis when symptoms, signs and investigations are reviewed?

A	Age
B	Respiratory rate 28/min
C	Serum urea 6 mmol/l
D	Albumin 37 g/l
E	ALT slightly outside the normal range

32371

Submit

Previous Question | Skip Question

Calculator

Normal Values

Blog About Pastest Contact Us Help

© Pastest 2017

You admit a 73-year-old man to the Emergency Department. He has had influenza over the past few days and has a worsening cough productive of purulent, blood-stained sputum. Observations: BP 122/72 mmHg, pulse 90/min and regular, respiratory rate 28/min. There are signs of right lower lobe pneumonia. A routine blood screen including arterial blood gas is performed.

Which one of the following features on admission is likely to be associated with a poorer prognosis when symptoms, signs and investigations are reviewed?

A	Age
B	Respiratory rate 28/min
C	Serum urea 6 mmol/l
D	Albumin 37 g/l
E	ALT slightly outside the normal range

Explanation

A	Age

Age >65 years is associated with a poorer prognosis in acute pneumonia. Other features not present here and which are associated with poorer prognosis include:

- confusion;
- urea >7 mmol/l;
- respiratory rate >30/min;
- blood pressure <90 systolic or <60 diastolic.

These features plus age make up the CURB-65 criteria. Where all five features are present, mortality from pneumonia is >50%, whereas 0-1 features carries a mortality rate of <3%.

B	Respiratory rate 28/min

The normal respiratory rate is 12-20 breaths per minute. It is likely to be elevated in the context of pneumonia, due both to the lung pathology and systemic effects of the infection.

C	Serum urea 6 mmol/l

Normal serum urea is 2.5-7 mmol/l. This is a normal result and not of clinical significance.

D	Albumin 37 g/l

Normal serum albumin levels are >35-50 g/l. This is therefore normal and not of prognostic significance.

E	ALT slightly outside the normal range

Deranged liver function tests tend to occur in atypical pneumonias such *Legionella* or *Mycoplasma*. Elevated ALT can indicated a poor prognosis, though a mild elevation is unlikely to be of clinical significance.

32371

Rate this question:

Next Question

Previous Question | Tag Question

Feedback | End Session

Difficulty: Average

Peer Responses %

Session Progress

Responses Correct:	0
Responses Incorrect:	129
Responses Total:	129
Responses - % Correct:	0%

External Links

BTS management of CAP
brit-thoracic.org.uk/document-library/clinical-information/pneumonia/adult-pneumo...

© Pastest 2017

A 71-year-old man returns from a veterans' convention in Spain. A few days later he becomes unwell with high fevers, rigors, a dry cough and severe headaches. On examination his BP is 105/60 mmHg, pulse is 92/min and regular and his temperature is 38.°9C. There is evidence of left basal consolidation and dullness suggestive of a pleural effusion, and his O_2 saturation is 93% on air.

Which one of the following features might point towards legionella infection if found in this patient?

A	Elevated transaminases
B	Cold agglutinins
C	Cavitation on chest X-ray
D	History of contact with birds
E	Warm agglutinins

32372

Submit

Previous Question | Skip Question

Calculator

Normal Values

Blog About Pastest Contact Us Help

© Pastest 2017

A 71-year-old man returns from a veterans' convention in Spain. A few days later he becomes unwell with high fevers, rigors, a dry cough and severe headaches. On examination his BP is 105/60 mmHg, pulse is 92/min and regular and his temperature is 38.º9C. There is evidence of left basal consolidation and dullness suggestive of a pleural effusion, and his O_2 saturation is 93% on air.

Which one of the following features might point towards legionella infection if found in this patient?

A	Elevated transaminases
B	Cold agglutinins
C	Cavitation on chest X-ray
D	History of contact with birds
E	Warm agglutinins

Explanation

The answer is - Elevated transaminases

Legionella has an incubation period of 2–10 days, and presents with fever, rigors, headache, myalgia, dry cough, progressively increasing respiratory distress and confusion. Diarrhoea and vomiting are common as are non-specific liver function test abnormalities. Relative bradycardia may be seen in some patients, in contrast to other acute pneumonias. Pleural effusion may be seen in up to 50% and chest x-ray appearance may take up to 4 months to return to normal. Diagnosis is made with serology, or with PCR on urinary legionella antigen. Treatment is with quinolones as first line therapy, with macrolides as a potential alternative. Complications include pericarditis, encephalitis and renal failure. Cold agglutinins are associated with mycoplasma pneumonia, infectious mononucleosis, and Listeria infection. Warm agglutinins are seen in patients with infectious mononucleosis.

32372

Rate this question:

Next Question

Previous Question | Tag Question

Feedback | End Session

Difficulty: Average

Peer Responses %

Session Progress

Responses Correct:	0
Responses Incorrect:	130
Responses Total:	130
Responses - % Correct:	0%

© Pastest 2017

You are asked to urgently review a 24-year-old woman who has been admitted to the emergency department. She has poorly controlled asthma for which she takes Seretide 250 two puffs bd and montelukast 10 mg daily. History of note includes two previous admissions to the intensive care unit. On examination she looks tired, her BP is 132/72 mmHg, pulse is 100/min and regular. There is poor air entry and bilateral severe wheeze on auscultation of the chest. Peak flow on admission was 150 l/min, and this has only improved to 210 after three salbutamol nebulisers, her predicted is 580. Her PaO_2 is 7.8 kPa on arterial blood gas measurement. There is patchy shadowing at the left base on chest X-ray.

Which one of the following features would indicate life threatening asthma?

A	PaO_2 of 7.8 kPa on air
B	$PaCO_2$ of 4.0 kPa on air
C	Distress and agitation
D	Changes suggesting infection on CXR
E	pH of 7.46

32373

Submit

Previous Question | Skip Question

Calculator

Normal Values

© Pastest 2017

You are asked to urgently review a 24-year-old woman who has been admitted to the emergency department. She has poorly controlled asthma for which she takes Seretide 250 two puffs bd and montelukast 10 mg daily. History of note includes two previous admissions to the intensive care unit. On examination she looks tired, her BP is 132/72 mmHg, pulse is 100/min and regular. There is poor air entry and bilateral severe wheeze on auscultation of the chest. Peak flow on admission was 150 l/min, and this has only improved to 210 after three salbutamol nebulisers, her predicted is 580. Her PaO_2 is 7.8 kPa on arterial blood gas measurement. There is patchy shadowing at the left base on chest X-ray.

Which one of the following features would indicate life threatening asthma?

A	PaO_2 of 7.8 kPa on air
B	$PaCO_2$ of 4.0 kPa on air
C	Distress and agitation
D	Changes suggesting infection on CXR
E	pH of 7.46

Explanation

Criteria for the diagnosis of life threatening asthma are clearly defined:

- PEF <33% best or predicted
- SpO_2 <92%
- PaO_2 <8 kPa
- normal $PaCO_2$ (4.6-6.0 kPa)
- silent chest
- cyanosis
- poor respiratory effort
- arrhythmia
- exhaustion, altered conscious level

http://www.sign.ac.uk/sign-153-british-guideline-on-the-management-of-asthma.html

32373

Rate this question:

Next Question

Previous Question | Tag Question

Feedback | End Session

Difficulty: Average

Peer Responses %

Session Progress

Responses Correct:	0
Responses Incorrect:	131
Responses Total:	131
Responses - % Correct:	0%

© Pastest 2017

A 64-year-old homeless man is admitted on the routine medical take. He has lost a significant amount of weight over the past few months and now presents with increasing shortness of breath. He is a former heavy smoker. On examination: decreased air entry over the right lower chest and dullness to percussion. Chest X-ray reveals a large, right-sided pleural effusion. Pleural aspiration is performed.

Which one of the following features, if present, would be the most specific indicator of probable underlying malignancy?

A	Turbid fluid
B	High pleural fluid neutrophil count
C	Uniform blood staining throughout pleural fluid samples
D	Abnormal liver function tests
E	Abnormal pleural fluid LDH levels

32374

Submit

Previous Question | Skip Question

Calculator

Normal Values

© Pastest 2017

A 64-year-old homeless man is admitted on the routine medical take. He has lost a significant amount of weight over the past few months and now presents with increasing shortness of breath. He is a former heavy smoker. On examination: decreased air entry over the right lower chest and dullness to percussion. Chest X-ray reveals a large, right-sided pleural effusion. Pleural aspiration is performed.

Which one of the following features, if present, would be the most specific indicator of probable underlying malignancy?

A	Turbid fluid
B	High pleural fluid neutrophil count
C	Uniform blood staining throughout pleural fluid samples
D	Abnormal liver function tests
E	Abnormal pleural fluid LDH levels

Explanation

C	Uniform blood staining throughout pleural fluid samples

Uniform blood staining and a protein level of >30 g/l are supportive of a diagnosis of malignancy.

pH can also be useful for interpreting pleural fluid results. Low pleural fluid pH is associated with a number of conditions, including pleural infection and empyema, inflammatory effusions such as those related to rheumatoid arthritis, tuberculosis, malignancy and oesophageal rupture.

A	Turbid fluid

Turbid fluid is suggestive of an infectious cause.

B	High pleural fluid neutrophil count

This is also indicative of an infective cause.

D	Abnormal liver function tests

Although deranged LFTs may suggest malignancy, there are other causes such as infection (particularly atypical organisms such as *Legionella*) and chronic disease such as liver cirrhosis.

E	Abnormal pleural fluid LDH levels

LDH is used to differentiate an exudate from a transudate. Raised LDH is suggestive of an exudate and therefore infectious or inflammatory cause. It needs to be measured simultaneously with serum LDH as it is the ratio of pleural fluid to serum LDH that is interpreted. A ratio >0.6 indicates an exudate.

32374

Rate this question:

Next Question

Previous Question | Tag Question

Feedback | End Session

Difficulty: Average

Peer Responses %

Session Progress

Responses Correct:	0
Responses Incorrect:	132
Responses Total:	132
Responses - % Correct:	0%

© Pastest 2017

A 54-year-old man presents with acute upper respiratory tract obstruction. On examination, BP is 100/70 mmHg with pulse 100/min and regular. He is sweating and erythematous, with acute respiratory stridor. He has a past medical history of hypertension and asthma. He takes amlodipine 5 mg daily, ramipril 5 mg daily and occasional salbutamol inhalers.

Which one of the following interventions is most likely to impact over the longer term?

A	Stop amlodipine
B	Stop ramipril
C	Give oral cetirizine
D	D Give him an EpiPen for use in case of a further attack
E	Screen the whole family for C1 esterase deficiency

32375

Submit

Previous Question Skip Question

Calculator

Normal Values

Blog About Pastest Contact Us Help

© Pastest 2017

A 54-year-old man presents with acute upper respiratory tract obstruction. On examination, BP is 100/70 mmHg with pulse 100/min and regular. He is sweating and erythematous, with acute respiratory stridor. He has a past medical history of hypertension and asthma. He takes amlodipine 5 mg daily, ramipril 5 mg daily and occasional salbutamol inhalers.

Which one of the following interventions is most likely to impact over the longer term?

A	Stop amlodipine
B	Stop ramipril
C	Give oral cetirizine
D	D Give him an EpiPen for use in case of a further attack
E	Screen the whole family for C1 esterase deficiency

Explanation

B	Stop ramipril

This man has angioedema, which may have been precipitated by his ACE inhibitor. Given the severity of this condition the precipitating drug should be stopped, and therefore ramipril should be discontinued, making Option B the correct answer. Angiotensin II receptor blockers are another possible cause. Angioedema can occur with other classes of anti-hypertensives such as calcium channel blockers, but is reported much less frequently. Rates of angioedema with thiazide diuretics and alpha blockers are intermediate. Acute management involves the use of IM adrenaline (epinephrine) and IV hydrocortisone. The ACE inhibitor should be substituted by another antihypertensive.

A	Stop amlodipine

Amlodipine is a calcium channel antagonist, and although angioedema has been reported in association with these drugs, it is much less common than with ACE inhibitors.

C	Give oral cetirizine

Cetirizine is an antihistamine used in allergic reactions. Although it can be used for angioedema, the severity of this presentation would make it of secondary use. A priority would be steroid treatment.

D	D Give him an EpiPen for use in case of a further attack

This patient has angioedema from a specific precipitant which can easily be removed without any need for further exposure. Stopping ramipril should prevent any further episodes. If an episode were to recur within three months of stopping the ACE inhibitor, then the patient should be referred to an immunologist. An EpiPen is not indicated for angioedema.

E	Screen the whole family for C1 esterase deficiency

C1 esterase deficiency is a cause of hereditary angioedema. Symptoms tend to start around puberty, though this is variable, and other family members will be affected. It can present with varying symptoms depending on the degree of C1 esterase deficiency and the genetic mutation that causes it. This is an unlikely cause in this scenario, where there is a clear precipitant of the angioedema.

32375

Rate this question:

Next Question

Previous Question | Tag Question

Feedback | End Session

Difficulty: Average

Peer Responses %

Session Progress

Responses Correct:	0
Responses Incorrect:	133
Responses Total:	133
Responses - % Correct:	0%

External Links

Predictors of angioedema
ncbi.nlm.nih.gov/pubmed/16957427

NICE guidance to management of angioedema
cks.nice.org.uk/angio-oedema-and-anaphylaxis#!scenario

© Pastest 2017

A 60-year old man presents with dull, right-sided chest ache, progressive shortness of breath and weight loss. He smokes 30 cigarettes per day and is a retired plumber with known asbestos exposure. On examination, BP is 125/72 mmHg with pulse 80/min and regular. There is reduced chest expansion on the right, with dullness to percussion and reduced air entry in the same area. Chest X-ray confirms the presence of a right-sided pleural effusion.

Which of the following is the optimal way to confirm the diagnosis?

A	Blind pleural biopsy
B	CT thorax
C	Pleural fluid aspiration
D	Thoracoscopy and biopsy
E	Ultrasound guided biopsy

32377

Submit

Previous Question | Skip Question

Calculator

Normal Values

© Pastest 2017

A 60-year old man presents with dull, right-sided chest ache, progressive shortness of breath and weight loss. He smokes 30 cigarettes per day and is a retired plumber with known asbestos exposure. On examination, BP is 125/72 mmHg with pulse 80/min and regular. There is reduced chest expansion on the right, with dullness to percussion and reduced air entry in the same area. Chest X-ray confirms the presence of a right-sided pleural effusion.

Which of the following is the optimal way to confirm the diagnosis?

A	Blind pleural biopsy
B	CT thorax
C	Pleural fluid aspiration
D	Thoracoscopy and biopsy
E	Ultrasound guided biopsy

Explanation

D	Thoracoscopy and biopsy

This patient most likely has mesothelioma, which can be difficult to diagnose. Biopsy is essential, but this needs to be done under imaging guidance to reduce the risk of tract spread, which is seeding of the tumour cells along the route of the biopsy needle. Thoracoscopy with biopsy under direct vision is the investigation of choice to confirm the diagnosis, and therefore this option is correct.

Mesothelial cells line the body cavities of the pleura, peritoneum, testis and pericardium. Malignancies involving these cells can be diffuse or localised. Most but not all pleural mesothelioma is associated with asbestos exposure. The most potent one is crocidolite (blue) followed by amosite (brown). There are three main histological types: mixed, sarcomatous and epithelial. The tumour arises from the visceral or parietal pleura and expands to encase the lung and spread to the oesophagus, superior vena cava and other nearby structures. The latent period from exposure is usually over 30 years. The higher the exposure dose the higher the risk. Some patients present up to 60 years after asbestos exposure. Where exposure is very high, presentation may occur as little as 10 years. Median survival after diagnosis is 11 months.

A	Blind pleural biopsy

Although pleural biopsy is necessary for the diagnosis of mesothelioma, this method is relatively inaccurate at identifying the correct location for biopsy, and there is high risk of tract spread. CT-guided biopsy is better than blind biopsy with an Abraham's needle, since it increases the chance of biopsy of an affected area; however, it still carries the same risk of tract spread.

B	CT thorax

CT is often used in the early stages of diagnosis of mesothelioma. On CT, mesothelioma appears as a nodular mass that spreads along pleural fissures. CT is a less sensitive test and would require subsequent biopsy to confirm the diagnosis.

C	Pleural fluid aspiration

More than 90% of patients present with pleural effusion and although pleural fluid aspiration may be necessary, it is not frequently diagnostic. Pleural fluid tends to have low leukocyte levels, low LDH and elevated protein.

E	Ultrasound guided biopsy

USS guidance is now recommended for all intrathoracic biopsies and fluid sampling. The superiority of thoracoscopy and biopsy under direct vision makes this option incorrect.

32377

Rate this question:

Next Question

Previous Question | Tag Question

Feedback | End Session

Difficulty: Average

Peer Responses %

Session Progress

Responses Correct:	0
Responses Incorrect:	134
Responses Total:	134
Responses - % Correct:	0%

© Pastest 2017

A 68-year-old alcoholic patient with known chronic obstructive pulmonary disease (COPD) was admitted to A&E with a 5-day history of green sputum and fevers. Past history of an inferior myocardial infarction is noted and regular medication includes high dose seretide inhaler, atorvastatin, ramipril and aspirin. On examination his BP is 95/65 mmHg, pulse is 100/min and regular. His respiratory rate is 25/min. There are signs of left lower lobe consolidation. He answers questions appropriately and his AMTS is 9/10.

Investigations:

Haemoglobin	13.8 g/dl (13.5-17.7)
White cell count	12.9 x 10^9/l (4-11)
Platelets	266 x 10^9/l (150-400)
Sodium	137 mmol/l (135-146)
Potassium	3.9 mmol/l (3.5-5)
Creatinine	90 micromol/l (79-118)
Urea	8.2 mmol/l (2.5-7.5)
CXR	Extensive left lower lobe consolidation
pH	7.38 (7.35-7.45)
pO_2	8.9 kPa (9.3-13.3)
pCO_2	4.6 kPa (4.7-6.0)

What is his CURB-65 score?

A	1
B	2
C	3
D	4
E	5

32378

Submit

Previous Question | Skip Question

Calculator

Normal Values

© Pastest 2017

A 68-year-old alcoholic patient with known chronic obstructive pulmonary disease (COPD) was admitted to A&E with a 5-day history of green sputum and fevers. Past history of an inferior myocardial infarction is noted and regular medication includes high dose seretide inhaler, atorvastatin, ramipril and aspirin. On examination his BP is 95/65 mmHg, pulse is 100/min and regular. His respiratory rate is 25/min. There are signs of left lower lobe consolidation. He answers questions appropriately and his AMTS is 9/10.

Investigations:

Haemoglobin	13.8 g/dl (13.5-17.7)
White cell count	12.9 x 10^9/l (4-11)
Platelets	266 x 10^9/l (150-400)
Sodium	137 mmol/l (135-146)
Potassium	3.9 mmol/l (3.5-5)
Creatinine	90 micromol/l (79-118)
Urea	8.2 mmol/l (2.5-7.5)
CXR	Extensive left lower lobe consolidation
pH	7.38 (7.35-7.45)
pO_2	8.9 kPa (9.3-13.3)
pCO_2	4.6 kPa (4.7-6.0)

What is his CURB-65 score?

A	1
B	2
C	3
D	4
E	5

Explanation

The CURB-65 score is made up by:

- age>65
- confusion
- urea >7 mmol/l
- respiratory rate > 30/min
- blood pressure less than 90 systolic or 60 diastolic.

In this case he scores increased risk for age and urea, so the correct answer is option B, CURB score of 2. Prognosis is closely related to CURB score, with a score of 0 or 1 being the best, carrying a mortality of <5%.

https://www.brit-thoracic.org.uk/document-library/clinical-information/pneumonia/adult-pneumonia/a-quick-reference-guide-bts-guidelines-for-the-management-of-community-acquired-pneumonia-in-adults/

32378

Rate this question:

Next Question

Previous Question | Tag Question

Feedback | End Session

Difficulty: Average

Peer Responses %

Session Progress

Responses Correct:	0
Responses Incorrect:	135
Responses Total:	135
Responses - % Correct:	0%

© Pastest 2017

As the medical SHO, you are admitting a 22-year-old asthma patient with an exacerbation of his asthma with a cough and severe wheeze that has been worsening over the past 2 days. He is normally on regular short-acting ß-agonist only, and his predicted peak flow is 600 litre/min. You are concerned that he may need review by the intensive care team. On examination in the Emergency department his BP is 110/72 mmHg, pulse is 110/min and regular. He has severe bilateral wheeze and his respiratory rate is 28/ min.

Investigations;

PaO_2	9.4 kPa (9.3-13.3)
$PaCO_2$	4.4 kPa (4.7-6.0)
pH	7.37 (7.35-7.45)
PEFR	180 l/min (600 predicted)

Which of the findings is most concerning?

A	Respiratory rate 28/min
B	Widespread wheeze
C	Heart rate 110/min
D	$PaCO_2$ 4.4 kPa
E	Peak flow of 180 L/min

32379

Submit

Previous Question | Skip Question

Calculator

Normal Values

© Pastest 2017

As the medical SHO, you are admitting a 22-year-old asthma patient with an exacerbation of his asthma with a cough and severe wheeze that has been worsening over the past 2 days. He is normally on regular short-acting ß-agonist only, and his predicted peak flow is 600 litre/min. You are concerned that he may need review by the intensive care team. On examination in the Emergency department his BP is 110/72 mmHg, pulse is 110/min and regular. He has severe bilateral wheeze and his respiratory rate is 28/ min.

Investigations;

PaO_2	9.4 kPa (9.3-13.3)
$PaCO_2$	4.4 kPa (4.7-6.0)
pH	7.37 (7.35-7.45)
PEFR	180 l/min (600 predicted)

Which of the findings is most concerning?

A	Respiratory rate 28/min
B	Widespread wheeze
C	Heart rate 110/min
D	$PaCO_2$ 4.4 kPa
E	Peak flow of 180 L/min

Explanation

Criteria for life threatening asthma are well described in the BTS asthma guidelines. Out of the clinical scenario listed above, it is only his PEFR of 180L/min which fits with those criteria, being less than 200 (the 33% predicted level). Given his peak flow however it's obviously important that he is managed aggressively according to the guidelines, including the addition of IV magnesium if early response to nebulisers isn't seen.

Criteria for life threatening asthma:

- PEF <33% best or predicted
- SpO_2 <92%
- PaO_2 <8 kPa
- normal $PaCO_2$ (4.6-6.0 kPa)
- silent chest
- cyanosis
- poor respiratory effort
- arrhythmia
- exhaustion, altered conscious level

32379

Rate this question:

Next Question

Previous Question | Tag Question

Feedback | End Session

Difficulty: Easy

Peer Responses %

Session Progress

Responses Correct:	0
Responses Incorrect:	136
Responses Total:	136
Responses - % Correct:	0%

© Pastest 2017

A 30-year-old patient with grade 3 MRC dyspnoea had a transthoracic echocardiogram showing severe pulmonary hypertension, with normal left ventricle size and function and normal function of all his heart valves. His chest X-ray ordered by the GP showed clear lung fields and his lung function tests were within normal limits. On examination, his BP is 145/79 mmHg, his pulse is 80/min and regular, and his BMI is 32. His chest is clear on auscultation. There is bilateral pitting oedema of both legs and marked varicosities on the left leg. He tells you the legs have been swollen and painful intermittently over the past year.

Which of the following tests would you do initially with respect to determining the underlying cause of his pulmonary hypertension?

A	High-resolution CT chest
B	Ultrasound abdomen and venous ultrasound lower limbs
C	Left heart catheterisation
D	Right heart catheterisation
E	Sleep study

32380

Submit

Previous Question | Skip Question

Calculator

Normal Values

Blog About Pastest Contact Us Help

© Pastest 2017

A 30-year-old patient with grade 3 MRC dyspnoea had a transthoracic echocardiogram showing severe pulmonary hypertension, with normal left ventricle size and function and normal function of all his heart valves. His chest X-ray ordered by the GP showed clear lung fields and his lung function tests were within normal limits. On examination, his BP is 145/79 mmHg, his pulse is 80/min and regular, and his BMI is 32. His chest is clear on auscultation. There is bilateral pitting oedema of both legs and marked varicosities on the left leg. He tells you the legs have been swollen and painful intermittently over the past year.

Which of the following tests would you do initially with respect to determining the underlying cause of his pulmonary hypertension?

A	High-resolution CT chest
B	Ultrasound abdomen and venous ultrasound lower limbs
C	Left heart catheterisation
D	Right heart catheterisation
E	Sleep study

Explanation

B	Ultrasound abdomen and venous ultrasound lower limbs

It is important to determine whether pulmonary hypertension is primary or secondary, because any underlying cause of secondary pulmonary hypertension may be treatable. Primary pulmonary hypertension is associated with connective tissue disease, vasculitis, HIV infection and use of appetite suppressants (e.g. fenfluramine), but there are no clues in this question pointing towards any of these associated features.

Given that the question alerts us that the patient has bilateral leg oedema as well as left leg varicosities, this gives us a clue that this is likely secondary pulmonary hypertension, possibly due to chronic venous thromboembolism. Therefore, ultrasound scanning of the lower limb to confirm left leg deep vein thrombosis, and of the abdomen to look for any potential sources of inferior vena cava obstruction (*bilateral* leg oedema), would be prudent, as these are widely available, non-invasive investigations.

A	High-resolution CT chest

The commonest cause of secondary pulmonary hypertension is COPD, but this patient has normal pulmonary function, so this is less likely. This response is a reasonable suggestion, but it is not necessarily the first-line investigation to be carried out, given that the patient has normal pulmonary function tests, making a structural abnormality of the lung parenchyma less likely.

C	Left heart catheterisation

Left heart catheterisation is unlikely to give us any further diagnostic evidence. Causes of secondary pulmonary hypertension include structural problems with the heart, such as mitral valve disease and left-to-right shunt, but again, this is less likely as the transthoracic echocardiogram does not demonstrate any of this. We already know from the patient's transthoracic echocardiogram that his left heart has normal size and function, so there is nothing more to be gained from this invasive investigation.

D	Right heart catheterisation

The invasive investigation of right heart catheterisation is going to add little more diagnostic utility. We already know that the patient has pulmonary hypertension from his transthoracic echocardiogram, and a right heart catherisation is only going to give more detail regarding pressures. It will not give us more information regarding the aetiology of the patient's pulmonary hypertension, which at this stage, we want to ascertain so that any underlying cause can be treated.

E	Sleep study

This is a reasonable option, because we know that the patient is obese (BMI 32) and obstructive sleep apnoea is a common cause of secondary pulmonary hypertension. However, given his history of leg oedema and left leg varicosity and the relative availability of lower limb ultrasound scanning, it would be more prudent to rule out chronic venous thromboembolism first before moving on to sleep studies.

32380

Rate this question:

Next Question

Previous Question | Tag Question

Feedback | End Session

Difficulty: Average

Peer Responses %

Session Progress

Responses Correct:	0
Responses Incorrect:	137
Responses Total:	137
Responses - % Correct:	0%

© Pastest 2017

A 60-year-old South Asian patient presents with shortness of breath and weight loss with night sweats. On examination, his respiratory rate is 24 breaths/min, he has lymphadenopathy and his left lower zone is stony dull to percussion. His chest X-ray demonstrates evidence of a moderate pleural effusion. You suspect tuberculosis as he confirms that his wife was recently diagnosed with the disease.

Investigations:

Hb	125 g/l
WCC	11.0 × 10^9/l
PLT	342 × 10^9/l
Na+	137 mmol/l
K+	3.8 mmol/l
Creatinine	54 mol/l
MCV	89.3 fl
Urea	4.0 mmol/l
CRP	85 mg/l
ESR	43 mm/h

Which of the following investigations is most useful in confirming the cause of the pleural effusion?

A	Pleural biopsy
B	High-resolution CT
C	Pleural fluid pH
D	Quantiferon gamma
E	Pleural fluid LDH

32399

Submit

Previous Question | Skip Question

Calculator

Normal Values

© Pastest 2017

A 60-year-old South Asian patient presents with shortness of breath and weight loss with night sweats. On examination, his respiratory rate is 24 breaths/min, he has lymphadenopathy and his left lower zone is stony dull to percussion. His chest X-ray demonstrates evidence of a moderate pleural effusion. You suspect tuberculosis as he confirms that his wife was recently diagnosed with the disease.

Investigations:

Hb	125 g/l
WCC	11.0 × 10^9/l
PLT	342 × 10^9/l
Na+	137 mmol/l
K+	3.8 mmol/l
Creatinine	54 mol/l
MCV	89.3 fl
Urea	4.0 mmol/l
CRP	85 mg/l
ESR	43 mm/h

Which of the following investigations is most useful in confirming the cause of the pleural effusion?

A	Pleural biopsy
B	High-resolution CT
C	Pleural fluid pH
D	Quantiferon gamma
E	Pleural fluid LDH

Explanation

A	Pleural biopsy

Pleural biopsy has a high yield in confirming active tuberculosis. The key to diagnosing tuberculosis is obtaining a tissue sample, particularly so that PCR for tuberculous DNA can be carried out to provide rapid diagnosis, to allow early differentiation from non-tuberculosis mycobacterial infection, and to detect multidrug-resistant disease.

B	High-resolution CT

Imaging such as CT will only determine the location and extent of the effusion, but it won't give any diagnostic information regarding whether it is caused by tuberculosis. CT will also help determine whether there is any mass underlying the effusion.

C	Pleural fluid pH

A pleural fluid pH <7.2 will confirm empyema, but not the infecting organism causing the empyema.

D	Quantiferon gamma

Quantiferon is an interferon-gamma release assay, specifically acting as a surrogate marker of *Mycobacterium tuberculosis*, and thus it cannot differentiate between latent and active infection. Therefore, a positive quantiferon gamma is of no diagnostic utility in this case, as it could simply indicate previous infection or infection with non-tuberculous mycobacteria.

E	Pleural fluid LDH

LDH is non-specifically raised in a number of conditions other than tuberculosis, such as a rheumatoid arthritis-related effusion or bacterial infection.

Pleural biopsy has a good detection rate for pleural TB. CT will not help determine the cause of the effusion, merely delineate its size and detect whether there is evidence of an underlying mass. Fluid pH is less than 7.2 in empyema and hence it is useful in pointing towards an infective cause but not necessarily TB. A Heaf test, if grade 4, will tell you that the patient has active TB, but again won't necessarily indicate that the effusion itself is related to TB infection. LDH is non-specifically raised in many causes of effusion, including infection, rheumatoid and TB.

32399

Rate this question:

Next Question

Previous Question | Tag Question

Feedback | End Session

Difficulty: Average

Peer Responses %

Session Progress

Responses Correct:	0
Responses Incorrect:	138
Responses Total:	138
Responses - % Correct:	0%

© Pastest 2017

An 80-year-old gentleman presents to the Emergency Department with gradually worsening shortness of breath of 4 days' duration. He has a fever and cough productive of greenish sputum. He is a known patient with chronic obstructive pulmonary disease (COPD) and is on home nebulisers (ipratropium bromide). His past medical history includes: a myocardial infarction 7 years ago, intensive care admission for his COPD 2 years ago and type 2 diabetes mellitus (diet-controlled). On examination, he is alert but febrile, with a blood pressure of 159/92 mmHg and a pulse of 92/min and regular. He has basal crackles more marked on the right, and scattered rhonchi in both lung fields. His abdominal examination is unremarkable. He is currently delivered 40% O_2 by mask.

Investigations:

Hb	11.3 g/dl
WCC	15.2 × 10^9/l
PLT	233 × 10^9/l
Na+	136 mmol/l
K+	3.7 mmol/l
Creatinine	111 mol/l
pH	7.31
paO_2	7.9 kPa
$paCO_2$	6.3 kPa
Bicarbonate	30 mmol/l
Urea	7.0 mmol/l
MCV	83 fl
CXR	Opacity obscuring the right heart border, evidence of fluid at both bases

Which one of the following would be the optimal way to manage his ventilatory support?

A	High flow oxygen (15 l)
B	Bi-level positive airway pressure (BiPAP)
C	24% oxygen
D	Continuous positive airway pressure (CPAP)
E	Intubate and ventilate the patient

32400

Submit

Previous Question | Skip Question

Calculator

Normal Values

© Pastest 2017

An 80-year-old gentleman presents to the Emergency Department with gradually worsening shortness of breath of 4 days' duration. He has a fever and cough productive of greenish sputum. He is a known patient with chronic obstructive pulmonary disease (COPD) and is on home nebulisers (ipratropium bromide). His past medical history includes: a myocardial infarction 7 years ago, intensive care admission for his COPD 2 years ago and type 2 diabetes mellitus (diet-controlled). On examination, he is alert but febrile, with a blood pressure of 159/92 mmHg and a pulse of 92/min and regular. He has basal crackles more marked on the right, and scattered rhonchi in both lung fields. His abdominal examination is unremarkable. He is currently delivered 40% O_2 by mask.

Investigations:

Hb	11.3 g/dl
WCC	15.2 × 10^9/l
PLT	233 × 10^9/l
Na+	136 mmol/l
K+	3.7 mmol/l
Creatinine	111 mol/l
pH	7.31
paO_2	7.9 kPa
$paCO_2$	6.3 kPa
Bicarbonate	30 mmol/l
Urea	7.0 mmol/l
MCV	83 fl
CXR	Opacity obscuring the right heart border, evidence of fluid at both bases

Which one of the following would be the optimal way to manage his ventilatory support?

A	High flow oxygen (15 l)
B	Bi-level positive airway pressure (BiPAP)
C	24% oxygen
D	Continuous positive airway pressure (CPAP)
E	Intubate and ventilate the patient

Explanation

B Bi-level positive airway pressure (BiPAP)

We can see from the patient's arterial blood gases that he is in type 2 respiratory failure with CO_2 retention, probably secondary to a right lower lobe pneumonia. BIPAP will help with gas transfer, reducing CO_2 levels. BIPAP is highly effective in this situation and can have a significant impact on mortality and morbidity.

A High flow oxygen (15 l)

We can see from the patient's arterial blood gases that he is in a respiratory acidosis (with CO_2 retention), so increasing his F_iO_2 further is going to exacerbate his CO_2 retention and worsen his clinical situation.

C 24% oxygen

We can see from the patient's arterial blood gases that he is hypoxic on 40% O_2. Whilst the rationale for reducing his oxygen to try to reduce his CO_2 levels might be reasonable with a lesser degree of hypoxia, simply reducing his oxygen in this situation is unlikely to improve his clinical situation.

D Continuous positive airway pressure (CPAP)

We can see from the patient's arterial blood gases that he is in type 2 respiratory failure with CO_2 retention. CPAP provides a pneumatic splint to the airway and is effective in improving oxygenation in patients requiring high concentration of oxygen by the recruitment of collapsed airways. In this patient's case, this is not such a good option; it would be more prudent to use BIPAP in order to maximise gas exchange and help him to 'blow off' his increased levels of CO_2.

E Intubate and ventilate the patient

Intubation and ventilation would not be the first line of treatment in this patient. Following a trial of BIPAP, if the patient failed to respond and following a careful assessment of his pre-morbid state and co-morbidities, a decision to intubate could then be considered.

32400

Rate this question:

Next Question

Previous Question | Tag Question

Feedback | End Session

Difficulty: Average

Peer Responses %

Session Progress

Responses Correct:	0
Responses Incorrect:	139
Responses Total:	139
Responses - % Correct:	0%

Blog About Pastest Contact Us Help

© Pastest 2017

A 40-year-old lady is admitted to the Emergency Department following shortness of breath of 3 days' duration. She is a patient known to have pulmonary sarcoidosis and had a percutaneous right upper lung biopsy a week ago. Now she presents with shortness of breath of 3 days duration and right-sided chest pain. She tells you that the chest pain worsens on inspiration and she has a cough that is not productive. Her past medical history includes: pulmonary fibrosis, asthma and irritable bowel syndrome. She takes dexamethasone 4 mg od and is not allergic to any medication. On examination, she is slightly dyspnoeic at rest with a blood pressure of 135/79 mmHg, pulse of 90/min and respiratory rate of 20/min. Her oxygen saturation is 94% on air. Her trachea is central but her chest expansion is minimally reduced on the right side. Breath sounds are reduced of the right side. Her apex beat is in the 5th intercostals space in the mid-clavicular line. Her cardiovascular and abdominal examination is normal. The following results are obtained:

Chest X-ray	On the right side there is a visible rim of air of 4 cm between the lung margin and the chest wall
ECG	normal sinus rhythm
pH	7.40
pa(O_2)	9.1 kPa
pa(CO_2)	3.8 kPa
Bicarbonate	28 mmol/l
Sodium	136 mmol/l
Potassium	3.7 mmol/l
Urea	7.0 mmol/l
Creatinine	111 mol/l
Haemoglobin	11.3 g/dl
Platelets	233 x 10^9/l
MCV	83 fl
WBC	10.2 x 10^9/l

How would you treat her pneumothorax?

A	Proceed to intercostal chest tube drainage
B	Discharge with review after 48hrs in the clinic
C	60% oxygen
D	Start her on oxygen and just observe her
E	Arrange for a bronchoscopy

32401

Submit

Previous Question | Skip Question

Calculator

Normal Values

© Pastest 2017

A 40-year-old lady is admitted to the Emergency Department following shortness of breath of 3 days' duration. She is a patient known to have pulmonary sarcoidosis and had a percutaneous right upper lung biopsy a week ago. Now she presents with shortness of breath of 3 days duration and right-sided chest pain. She tells you that the chest pain worsens on inspiration and she has a cough that is not productive. Her past medical history includes: pulmonary fibrosis, asthma and irritable bowel syndrome. She takes dexamethasone 4 mg od and is not allergic to any medication. On examination, she is slightly dyspnoeic at rest with a blood pressure of 135/79 mmHg, pulse of 90/min and respiratory rate of 20/min. Her oxygen saturation is 94% on air. Her trachea is central but her chest expansion is minimally reduced on the right side. Breath sounds are reduced of the right side. Her apex beat is in the 5th intercostals space in the mid-clavicular line. Her cardiovascular and abdominal examination is normal. The following results are obtained:

Chest X-ray	On the right side there is a visible rim of air of 4 cm between the lung margin and the chest wall
ECG	normal sinus rhythm
pH	7.40
pa(O_2)	9.1 kPa
pa(CO_2)	3.8 kPa
Bicarbonate	28 mmol/l
Sodium	136 mmol/l
Potassium	3.7 mmol/l
Urea	7.0 mmol/l
Creatinine	111 mol/l
Haemoglobin	11.3 g/dl
Platelets	233 x 10^9/l
MCV	83 fl
WBC	10.2 x 10^9/l

How would you treat her pneumothorax?

A	Proceed to intercostal chest tube drainage
B	Discharge with review after 48hrs in the clinic
C	60% oxygen
D	Start her on oxygen and just observe her
E	Arrange for a bronchoscopy

Explanation

This is a secondary pneumothorax, which could have resulted from the percutaneous lung biopsy or occurred secondary to her pulmonary sarcoidosis. From the blood gases, this lady is also hypoxic and the pneumothorax is large on CXR (a large pneumothorax approximates to a 50% loss of lung volume). Since this is a large secondary pneumothorax it is appropriate to proceed to intercostal drain insertion. Oxygen replacement therapy is also advisable, as is suitable analgesia.

http://thorax.bmj.com/content/65/Suppl_2.toc#BTSPleuralDiseaseGu

32401

Rate this question:

Next Question

Previous Question | Tag Question

Feedback | End Session

Difficulty: Average

Peer Responses %

Session Progress

Responses Correct:	0
Responses Incorrect:	140
Responses Total:	140
Responses - % Correct:	0%

© Pastest 2017

Your subsc
MRCP P
USMLE
My Acco
MyPaste
Shop
Blog
Contact
Mobile A
Help
Logged in
Log out

A 65-year-old man presents to the Emergency Department with acute breathlessness, cough and frothy, blood-stained sputum. He had been trying to save his cat from his house, which was on fire when he was overcome with smoke. The firefighters rescued him. On examination he is dyspnoeic, with a blood pressure of 111/62 mmHg, pulse rate of 104/min and respiratory rate of 28/min. On auscultation, he has crackles in both lung fields. The abdominal examination is unremarkable. His oxygen saturation is 88% on air. You immediately start the patient on high-flow oxygen (15 l).

The following results are obtained on oxygen:

pH	7.31
pa(O_2)	8.0 kPa
pa(CO_2)	4.2 kPa
Bicarbonate	21 mmol/l
CXR	Interstital shadowing in both lung fields

Which of the following options is the next management of choice?

A	Give sublingual glyceryl trinitrate (GTN) spray (2 puffs)
B	Intubate and ventilate the patient
C	Continuous pulmonary airway pressure (CPAP)
D	Bi-level pulmonary airway pressure (BiPAP)
E	Ventilation/perfusion scan

32402

Submit

Previous Question | Skip Question

Calculator

Normal Values

© Pastest 2017

A 65-year-old man presents to the Emergency Department with acute breathlessness, cough and frothy, blood-stained sputum. He had been trying to save his cat from his house, which was on fire when he was overcome with smoke. The firefighters rescued him. On examination he is dyspnoeic, with a blood pressure of 111/62 mmHg, pulse rate of 104/min and respiratory rate of 28/min. On auscultation, he has crackles in both lung fields. The abdominal examination is unremarkable. His oxygen saturation is 88% on air. You immediately start the patient on high-flow oxygen (15 l).

The following results are obtained on oxygen:

pH	7.31
pa(O_2)	8.0 kPa
pa(CO_2)	4.2 kPa
Bicarbonate	21 mmol/l
CXR	Interstitial shadowing in both lung fields

Which of the following options is the next management of choice?

A	Give sublingual glyceryl trinitrate (GTN) spray (2 puffs)
B	Intubate and ventilate the patient
C	Continuous pulmonary airway pressure (CPAP)
D	Bi-level pulmonary airway pressure (BiPAP)
E	Ventilation/perfusion scan

Explanation

B Intubate and ventilate the patient

This patient has had an acute insult to his lungs following smoke and carbon monoxide exposure, with his chest X-ray appearances consistent with acute respiratory distress syndrome (ARDS). Given that he is failing to maintain a pO_2 ⩾8.3 kPa, despite maximal oxygen delivery, the next step would be intubation and ventilation. Invasive circulatory monitoring is also essential with respect to managing pulmonary capillary wedge pressure and cardiac output. There is conflicting evidence for the use of steroids; as such, they are not universally recommended in ARDS.

A Give sublingual glyceryl trinitrate (GTN) spray (2 puffs)

The clinical scenario above is describing a patient who has had an acute insult to his lungs following exposure to smoke and carbon monoxide. He has no features whatsoever of angina or acute coronary syndrome, so sublingual GTN would be inappropriate.

C Continuous pulmonary airway pressure (CPAP)

This patient has had an acute insult to his lungs following smoke and carbon monoxide exposure, with his chest X-ray appearances consistent with acute respiratory distress syndrome (ARDS). CPAP would be a reasonable option in pulmonary oedema, but given that this patient most likely has ARDS and is failing to maintain his pO_2 ⩾8.3 kPa on maximal oxygen delivery, invasive ventilation is the more appropriate option for ventilatory support.

D Bi-level pulmonary airway pressure (BiPAP)

Whilst the patient has a reduced pH, this is clearly a metabolic acidosis as his bicarbonate is also reduced. His CO_2 levels are normal, so he is not in type 2 respiratory failure and there is no indication for BIPAP.

E Ventilation/perfusion scan

This patient has had an acute insult to his lungs following smoke and carbon monoxide exposure, with his chest X-ray appearances consistent with acute respiratory distress syndrome (ARDS). As such, he is not maintaining optimal oxygen saturation despite maximal oxygen delivery, so a decision must be made immediately regarding additional ventilator support. Carrying out a scan at this point will delay treatment and will not benefit the patient. This investigation would be more appropriate in a stable patient in whom pulmonary embolism is suspected, but who would not be appropriate for a CTPA (e.g. a pregnant woman, or a patient in acute kidney injury who is at high risk of contrast-induced nephropathy).

32402

Rate this question:

Next Question

Previous Question | Tag Question

Feedback | End Session

Difficulty: Average

Peer Responses %

Session Progress

Responses Correct:	0
Responses Incorrect:	141
Responses Total:	141
Responses - % Correct:	0%

Blog About Pastest Contact Us Help

© Pastest 2017

A 35-year-old African female presents with a 6-months history of night sweats, shortness of breath on exertion and dry cough. She also gives a history of weight loss and arthralgia over the same period of time. She had been intermittently unwell for 1 year before the development of these symptoms. She recalls a painful rash on her shins 3 months ago, which resolved spontaneously. She gives no history of eye problems, polyuria or polydipsia. She denies chest pain or tightness. She denies any past medical problems and is not on any medications. On examination she appears well at rest. There is no joint swelling or redness. Cardiovascular, respiratory and abdominal examinations are normal.

Which investigation is most likely to help confirm the diagnosis?

A	Serum angiotensin-converting enzyme (ACE) concentration
B	Pulmonary function tests
C	Quantiferon gamma
D	Bronchoalveolar lavage
E	Transbronchial lung biopsy

32403

Submit

Previous Question Skip Question

Calculator

Normal Values

Blog About Pastest Contact Us Help

© Pastest 2017

A 35-year-old African female presents with a 6-months history of night sweats, shortness of breath on exertion and dry cough. She also gives a history of weight loss and arthralgia over the same period of time. She had been intermittently unwell for 1 year before the development of these symptoms. She recalls a painful rash on her shins 3 months ago, which resolved spontaneously. She gives no history of eye problems, polyuria or polydipsia. She denies chest pain or tightness. She denies any past medical problems and is not on any medications. On examination she appears well at rest. There is no joint swelling or redness. Cardiovascular, respiratory and abdominal examinations are normal.

Which investigation is most likely to help confirm the diagnosis?

A	Serum angiotensin-converting enzyme (ACE) concentration
B	Pulmonary function tests
C	Quantiferon gamma
D	Bronchoalveolar lavage
E	Transbronchial lung biopsy

Explanation

E	Transbronchial lung biopsy

In this patient of African ethnicity with a description of probable erythema nodosum and a dry cough, the most likely diagnosis is sarcoidosis. Sarcoidosis is a multi-system granulomatous disorder of unknown aetiology and is characterised pathologically by the presence of non-caseating granulomas in involved organs. As with the diagnosis of tuberculosis, a tissue diagnosis is the only completely specific way that a confirmed diagnosis can be made, as all the other diagnostic tests are non-specific to sarcoidosis.

A	Serum angiotensin-converting enzyme (ACE) concentration

In this patient of African ethinicity with a description of probable erythema nodosum and a dry cough, the most likely diagnosis is sarcoidosis. Serum angiotensin-converting enzyme (ACE) activity is elevated in 60% of patients, presumably reflecting macrophage activity. It can also be elevated in patients with histoplasmosis, acute miliary tuberculosis (TB), Gaucher's hepatitis or lymphoma, and is non-specific. Liver disease slows the metabolic excretion of serum ACE and results in increased ACE activity.

B	Pulmonary function tests

In this patient of African ethnicity with a description of probable erythema nodosum and a dry cough, the most likely diagnosis is sarcoidosis. However, pulmonary function tests are non-specific in making this diagnosis. Pulmonary function tests show restriction, decreased compliance and impaired diffusing capacity. However, serial pulmonary function tests are important for assessing disease progression and guiding treatment.

C	Quantiferon gamma

This is an African patient with a dry cough and what sounds like erythema nodosum. Whilst tuberculosis would be in the differential diagnosis, given that she is having night sweats and is systemically unwell, a quantiferon gamma would not confirm or refute a diagnosis of active tuberculosis, as it cannot differentiate between active or latent disease.

D	Bronchoalveolar lavage

In this patient of African ethnicity with a description of probable erythema nodosum and a dry cough, the most likely diagnosis is sarcoidosis. Bronchoalveolar lavage (BAL) can be used as an adjunctive measure to support the diagnosis of sarcoidosis. Bronchoalveolar lavage shows lymphocytosis in most patients with active sarcoidosis, but is rarely indicated because patients with hypersensitivity pneumonitis show similar lymphocytosis.

32403

Rate this question:

Next Question

Previous Question | Tag Question

Feedback | End Session

Difficulty: Average

Peer Responses %

Session Progress

Responses Correct:	0
Responses Incorrect:	142
Responses Total:	142
Responses - % Correct:	0%

© Pastest 2017

A 58-year-old man was referred to the neurology clinic by his general practitioner with a 4-month history of progressive weakness. He described difficulty walking, with heavy, stiff legs. He had particular trouble in going upstairs and rising from a chair. He also occasionally had episodes of double vision. Apart from controlled hypertension, he had no significant past medical history. He smoked 20 cigarettes per day and drank 16 units of alcohol per week. On systems enquiry, he also admitted to weight loss of one stone, a persistent cough and a dry mouth. He reluctantly admitted that he had been having some sexual difficulties with his wife recently.

On examination, he looked reasonably well. There was no finger clubbing or lymphadenopathy. Cardiorespiratory examination revealed coarse crackles consistent with COPD, and abdominal examination was unremarkable. On neurological examination, his tone and sensation were normal, with no muscle wasting. He had predominantly proximal muscle weakness and his tendon reflexes were universally absent. Apart from mild bilateral ptosis, his cranial nerves were intact. Interestingly, his power and reflexes seemed to improve after a brief period of repetitive exercise of the affected muscle.

Investigations:

Hb	14.0 g/dl
WCC	5.0×10^9/l
Platelets	300×10^9/l
Urea	5.2 mmol/l
MCV	82 fl
Na^+	130 mmol/l
K^+	3.6 mmol/l
Bilirubin	10 mol/l
ALT	32 IU/l mol/l
Creatinine	120 mol/l
ALP	80 IU/l
GGT	42 IU/l

Which of the following investigations would be the most useful in making a diagnosis?

A	Tensilon (edrophonium) test
B	Serum acetylcholine receptor antibodies
C	Muscle biopsy
D	Anti-calcium channel antibodies
E	Serum creatine kinase

32404

Submit

Previous Question | Skip Question

Calculator

Normal Values

© Pastest 2017

A 58-year-old man was referred to the neurology clinic by his general practitioner with a 4-month history of progressive weakness. He described difficulty walking, with heavy, stiff legs. He had particular trouble in going upstairs and rising from a chair. He also occasionally had episodes of double vision. Apart from controlled hypertension, he had no significant past medical history. He smoked 20 cigarettes per day and drank 16 units of alcohol per week. On systems enquiry, he also admitted to weight loss of one stone, a persistent cough and a dry mouth. He reluctantly admitted that he had been having some sexual difficulties with his wife recently.

On examination, he looked reasonably well. There was no finger clubbing or lymphadenopathy. Cardiorespiratory examination revealed coarse crackles consistent with COPD, and abdominal examination was unremarkable. On neurological examination, his tone and sensation were normal, with no muscle wasting. He had predominantly proximal muscle weakness and his tendon reflexes were universally absent. Apart from mild bilateral ptosis, his cranial nerves were intact. Interestingly, his power and reflexes seemed to improve after a brief period of repetitive exercise of the affected muscle.

Investigations:

Hb	14.0 g/dl
WCC	5.0 × 10^9/l
Platelets	300 × 10^9/l
Urea	5.2 mmol/l
MCV	82 fl
Na^+	130 mmol/l
K^+	3.6 mmol/l
Bilirubin	10 mol/l
ALT	32 IU/l mol/l
Creatinine	120 mol/l
ALP	80 IU/l
GGT	42 IU/l

Which of the following investigations would be the most useful in making a diagnosis?

A Tensilon (edrophonium) test

B Serum acetylcholine receptor antibodies

C Muscle biopsy

D Anti-calcium channel antibodies

E Serum creatine kinase

Explanation

D Anti-calcium channel antibodies

This man has Lambert–Eaton myasthenic syndrome (LEMS), which is associated with an underlying small cell carcinoma of the bronchus. This is a rare paraneoplastic phenomenon which can precede radiological evidence of the tumour by up to 5 years. LEMS is a presynaptic disorder of the neuromuscular junction which is caused by antibodies to the voltage-gated calcium channels of the nerve terminal, leading to failure of acetylcholine release. The clinical features are proximal muscle weakness and depressed tendon reflexes, which can return after a few minutes of muscular contraction. Autonomic symptoms are common. The diagnosis is made electrophysiologically, and auto-antibodies are found in 90% of cases. Treatment is with 3,4-diaminopyridine, prednisolone and occasionally plasma exchange.

A Tensilon (edrophonium) test

In this patient with a significant smoking history, evidence of COPD and proximal muscle weakness, the most likely diagnosis is Lambert-Eaton myasthenic syndrome (LEMS), which is associated with an underlying small cell carcinoma of the bronchus. A tensilon test would be diagnostic for myasthenia gravis, an autoimmune muscle condition which is associated with fatigueability, i.e. power and function deteriorate with repeated testing.

B Serum acetylcholine receptor antibodies

In this patient with a significant smoking history, evidence of COPD and proximal muscle weakness, the most likely diagnosis is Lambert-Eaton myasthenic syndrome (LEMS), which is associated with an underlying small cell carcinoma of the bronchus. ACh receptor antibodies would be part of the diagnostic testing for myasthenia gravis, an autoimmune muscle condition which is associated with fatigueability, i.e. power and function deteriorate with repeated testing.

C Muscle biopsy

In this patient with a significant smoking history, evidence of COPD and proximal muscle weakness, the most likely diagnosis is Lambert-Eaton myasthenic syndrome (LEMS), which is associated with an underlying small cell carcinoma of the bronchus. A muscle biopsy would be useful in diagnosing an inflammatory or necrotising myopathy, but these diagnoses are less likely, given that testing improves with repetition in this patient, and one would expect power to decline with repeated testing in a myopathy.

E Serum creatine kinase

In this patient with a significant smoking history, evidence of COPD and proximal muscle weakness, the most likely diagnosis is Lambert-Eaton myasthenic syndrome (LEMS), which is associated with an underlying small cell carcinoma of the bronchus. Raised creatine kinase is a non-specific marker of muscle damage. It can be elevated in, for example, inflammatory or necrotising myopathy, statin-induced myopathy, myocardial infarction, rhabdomyolysis or metabolic myopathy.

32404

Rate this question:

Next Question

Previous Question | Tag Question

Feedback | End Session

Difficulty: Average

Peer Responses %

Session Progress

Responses Correct:	0
Responses Incorrect:	143
Responses Total:	143
Responses - % Correct:	0%

© Pastest 2017

A previously well 23-year-old student presents to the emergency department with an acute onset of pleuritic chest pain and dyspnoea. She had returned from a gap year to Australia three days ago and had been well until the morning of admission. She had no significant past medical history or family history and was on no medication. She was a non-smoker.
On examination she was acutely distressed with a respiratory rate of 32/min, pulse 128/min, blood pressure 98/60 mmHg. She was peripherally cool. Her chest was clear to auscultation and her heart sounds were normal. The jugular venous pressure was elevated. There was no obvious leg swelling.

Investigation results are below:

Hb	15.2 g/dl
WCC	14×10^9/l
Platelets	310×10^9/l
Na+	136 mmol/l
K+	4.2 mmol/l
Urea	3.2 mmol/l
Creatinine	90 µmol/l
Chest radiograph	Normal
ECG	Sinus tachycardia, T wave inversion in leads V1–V3

Arterial blood gases (on 15 l/min oxygen) were:	
pH	7.48
pa(O_2)	8.2 kPa
pa(CO_2)	3.6 kPa

IV heparin is commenced.

Which of the following is the most appropriate initial management?

A	Intravenous dobutamine
B	Thrombolysis with streptokinase
C	Intravenous normal saline
D	Intravenous doxapram
E	Intravenous dopamine

32405

Submit

Previous Question | Skip Question

Calculator

Normal Values

© Pastest 2017

A previously well 23-year-old student presents to the emergency department with an acute onset of pleuritic chest pain and dyspnoea. She had returned from a gap year to Australia three days ago and had been well until the morning of admission. She had no significant past medical history or family history and was on no medication. She was a non-smoker.
On examination she was acutely distressed with a respiratory rate of 32/min, pulse 128/min, blood pressure 98/60 mmHg. She was peripherally cool. Her chest was clear to auscultation and her heart sounds were normal. The jugular venous pressure was elevated. There was no obvious leg swelling.

Investigation results are below:

Hb	15.2 g/dl
WCC	14 × 10^9/l
Platelets	310 × 10^9/l
Na+	136 mmol/l
K+	4.2 mmol/l
Urea	3.2 mmol/l
Creatinine	90 μmol/l
Chest radiograph	Normal
ECG	Sinus tachycardia, T wave inversion in leads V1–V3

Arterial blood gases (on 15 l/min oxygen) were:	
pH	7.48
pa(O_2)	8.2 kPa
pa(CO_2)	3.6 kPa

IV heparin is commenced.

Which of the following is the most appropriate initial management?

A	Intravenous dobutamine
B	Thrombolysis with streptokinase
C	Intravenous normal saline
D	Intravenous doxapram
E	Intravenous dopamine

Explanation

Intravenous normal saline

The diagnosis is acute, major pulmonary embolism. Fluids should be given in the first instance to increase right ventricular filling pressure and maintain cardiac output. Heparinisation should prevent further emboli occurring. If hypotension is severe and does not respond to plasma expanders, inotropic support may be necessary. Thrombolysis should be considered if the patient is not improving after 15–30 min with the above measures. British thoracic society guidelines do not deliver any strong guidance with respect to the thrombolysis except that it should be considered where there is circulatory collapse. Pulmonary embolectomy should only be undertaken when thrombolysis is contraindicated.
Diagnosis of pulmonary embolism is made by spiral computed tomography (CT) or ventilation-perfusion (V/Q) scan. Echocardiography can be useful in the acute setting.

© Pastest 2017

A 32-year-old African-Caribbean nurse is referred to the chest clinic with several months of progressive dyspnoea and a dry cough. She is now short of breath on minimal exertion. She was previously fit and well, has no relevant family history and is on no medications. She is a non-smoker. On closer questioning, she also described fatigue and weight loss and a painful eye with blurred vision for the last few weeks.
On examination, she was comfortable at rest with mild pyrexia of 37.4°C. Her heart sounds were normal and she had fine crackles at both mid-zones in her chest. Her abdomen was non-tender with no palpable masses. She had no focal neurological signs. She had an inflamed, watery right eye with reduced visual acuity. On inspection of her skin, she had several raised erythematous lesions on her shins that were tender to palpation.

Investigations:

Hb	9.8 g/dl
WCC	7.6×10^9/l
Platelets	360×10^9/l
GGT	32 IU/l
MCV	92 fl
ESR	80 mm/hr
Na^+	138 mmol/l
K+	4.2 mmol/l
Ca^{2+}	2.78 mmol/l
Albumin	36 g/l
Bilirubin	14 mol/l
Urea	4.2 mmol/l
Creatinine	82 mol/l
ALT	38 IU/l
ALP	60 IU/l
CXR	Mottling at both mid-zones with some line shadows. Enlarged hila bilaterally.

Pulmonary function tests

Forced expiratory volume (FEV_1)	78% of predicted
Forced vital capacity (FVC)	70% of predicted
Transfer co-efficient (Kco)	78% of predicted

Which of the following is the most appropriate initial therapy for this patient?

A	Anti-tuberculous chemotherapy
B	Ciclosporin
C	Cyclophosphamide
D	Methotrexate
E	Prednisolone

32406

Submit

Previous Question | Skip Question

Calculator

Normal Values

© Pastest 2017

A 32-year-old African-Caribbean nurse is referred to the chest clinic with several months of progressive dyspnoea and a dry cough. She is now short of breath on minimal exertion. She was previously fit and well, has no relevant family history and is on no medications. She is a non-smoker. On closer questioning, she also described fatigue and weight loss and a painful eye with blurred vision for the last few weeks.
On examination, she was comfortable at rest with mild pyrexia of 37.4°C. Her heart sounds were normal and she had fine crackles at both mid-zones in her chest. Her abdomen was non-tender with no palpable masses. She had no focal neurological signs. She had an inflamed, watery right eye with reduced visual acuity. On inspection of her skin, she had several raised erythematous lesions on her shins that were tender to palpation.

Investigations:

Hb	9.8 g/dl
WCC	7.6 × 10^9/l
Platelets	360 × 10^9/l
GGT	32 IU/l
MCV	92 fl
ESR	80 mm/hr
Na^+	138 mmol/l
K+	4.2 mmol/l
Ca^{2+}	2.78 mmol/l
Albumin	36 g/l
Bilirubin	14 mol/l
Urea	4.2 mmol/l
Creatinine	82 mol/l
ALT	38 IU/l
ALP	60 IU/l
CXR	Mottling at both mid-zones with some line shadows. Enlarged hila bilaterally.

Pulmonary function tests

Forced expiratory volume (FEV_1)	78% of predicted
Forced vital capacity (FVC)	70% of predicted
Transfer co-efficient (Kco)	78% of predicted

Which of the following is the most appropriate initial therapy for this patient?

A Anti-tuberculous chemotherapy

B Ciclosporin

C Cyclophosphamide

D Methotrexate

E Prednisolone

Explanation

E Prednisolone

This lady has pulmonary sarcoidosis with anterior uveitis and erythema nodosum and hypercalcaemia. In her case, the first-line treatment would be steroids, given her hypercalcaemia. Steroids are not indicated without hypercalcaemia, when management would simply be supportive.

A Anti-tuberculous chemotherapy

This lady has pulmonary sarcoidosis with anterior uveitis and erythema nodosum, with evidence of bilateral hilar lymphadenopathy on her chest radiograph. Therefore, this option is incorrect as this is the treatment for TB.

B Ciclosporin

This lady has pulmonary sarcoidosis with anterior uveitis and erythema nodosum and hypercalcaemia. In her case, the first-line treatment would be steroids, given her hypercalcaemia. Ciclosporin could be considered further down the line as a steroid-sparing agent, if she was unable to wean off prednisolone.

C Cyclophosphamide

This lady has pulmonary sarcoidosis with anterior uveitis and erythema nodosum and hypercalcaemia. In her case, the first-line treatment would be steroids, given her hypercalcaemia. Cyclophosphamide could be considered further down the line if she is particular resistant to high-dose steroids.

D Methotrexate

This lady has pulmonary sarcoidosis with anterior uveitis and erythema nodosum and hypercalcaemia. In her case, the first-line treatment would be steroids, given her hypercalcaemia. Methotrexate could be considered at a later stage as a steroid-sparing agent if she fails to wean off prednisolone.

© Pastest 2017

A 34-year-old woman presents with a gradual onset of exertional dyspnoea over the previous 18 months. She had consulted her general practitioner several months ago who had diagnosed her with asthma and prescribed a salbutamol inhaler that was not really helping symptoms. She was now dyspnoeic on minimal exertion. She had no cough, sputum or haemoptysis. She described recent fatigue and several episodes of presyncope. She was a non-smoker and had no significant past medical or family history.
On examination she was obese with a body mass index of 34. She had a loud pulmonary component to the second heart sound, an early diastolic murmur over the pulmonary area and a palpable right ventricular heave. Her jugular venous pressure was raised and she had pitting ankle oedema. Her chest was clear to auscultation. Abdominal and neurological examinations were entirely normal.

Investigations:

Hb	16 g/dl
WCC	6.0×10^9/l
Platelets	250×10^9/l
Na+	136×10^9/l
K+	4.0×10^9/l
Urea	5.2 mmol/l
Creatinine	96 μ mol/l
Plasma D-dimers	130 (ULN = 285)
ECG	Sinus rhythm, right axis deviation, right ventricular hypertrophy
CXR	Enlarged hila bilaterally, oligaemic peripheral lung fields

Which investigation would be most helpful in establishing the diagnosis?

A	Respiratory function tests
B	Exercise ECG
C	Ventilation–perfusion (V/Q) lung scan
D	24-h ECG monitoring
E	Dobutamine stress echocardiogram

32407

Submit

Previous Question | Skip Question

Calculator

Normal Values

© Pastest 2017

A 34-year-old woman presents with a gradual onset of exertional dyspnoea over the previous 18 months. She had consulted her general practitioner several months ago who had diagnosed her with asthma and prescribed a salbutamol inhaler that was not really helping symptoms. She was now dyspnoeic on minimal exertion. She had no cough, sputum or haemoptysis. She described recent fatigue and several episodes of presyncope. She was a non-smoker and had no significant past medical or family history.
On examination she was obese with a body mass index of 34. She had a loud pulmonary component to the second heart sound, an early diastolic murmur over the pulmonary area and a palpable right ventricular heave. Her jugular venous pressure was raised and she had pitting ankle oedema. Her chest was clear to auscultation. Abdominal and neurological examinations were entirely normal.

Investigations:

Hb	16 g/dl
WCC	6.0×10^9/l
Platelets	250×10^9/l
Na+	136×10^9/l
K+	4.0×10^9/l
Urea	5.2 mmol/l
Creatinine	96 μmol/l
Plasma D-dimers	130 (ULN = 285)
ECG	Sinus rhythm, right axis deviation, right ventricular hypertrophy
CXR	Enlarged hila bilaterally, oligaemic peripheral lung fields

Which investigation would be most helpful in establishing the diagnosis?

A	Respiratory function tests
B	Exercise ECG
C	Ventilation–perfusion (V/Q) lung scan
D	24-h ECG monitoring
E	Dobutamine stress echocardiogram

Explanation

C Ventilation–perfusion (V/Q) lung scan

The diagnosis is either primary pulmonary hypertension (PPH) or multiple recurrent pulmonary emboli. PPH is a rare disorder of unknown aetiology which typically affects young females. There is an average delay of 2 years between symptom onset and diagnosis, by which time cor pulmonale has usually developed.
Echocardiography shows right ventricular enlargement, and cardiac catherisation will demonstrate a raised pulmonary artery pressure. A V/Q scan may show patchy filling defects different from those seen in pulmonary embolism, and remains part of the diagnostic work-up. Multiple pulmonary emboli are a possibility given her obesity. It's possible for an accumulation of small pulmonary emboli to eventually lead to secondary pulmonary hypertension and right heart failure. Diagnosis is with V/Q scan or spiral CT, which demonstrates multiple perfusion defects. If V/Q is negative then primary pulmonary hypertension becomes a more likely possibility.

A Respiratory function tests

The diagnosis is either primary pulmonary hypertension (PPH) or multiple recurrent pulmonary emboli, given the patient's age, evidence of pulmonary hypertension, raised haemoglobin and obesity. Pulmonary function testing will give us no more additional information that will help us to reach a diagnosis. DLCO may be reduced given the reduced capacity for oxygen transfer due to pulmonary hypertension, but PFTs will not help us make either of these diagnoses.

B Exercise ECG

The diagnosis is either primary pulmonary hypertension (PPH) or multiple recurrent pulmonary emboli, given the patient's age, evidence of pulmonary hypertension, raised haemoglobin and obesity. An exercise ECG would help to pick up an exercise-induced arrhythmia, but would not be of any diagnostic utility in this patient's case.

D 24-h ECG monitoring

The diagnosis is either primary pulmonary hypertension (PPH) or multiple recurrent pulmonary emboli, given the patient's age, evidence of pulmonary hypertension, raised haemoglobin and obesity. Ambulatory ECG monitoring might help to uncover an arrhythmia causing intermittent dyspnoea and symptoms of palpitations, but it will not add any additional diagnostic insight in this patient's case.

E Dobutamine stress echocardiogram

The diagnosis is either primary pulmonary hypertension (PPH) or multiple recurrent pulmonary emboli, given the patient's age, evidence of pulmonary hypertension, raised haemoglobin and obesity. A dobutamine stress echo will help ascertain how cardiac function performs under physiological stress, but it will not help to diagnose either of the above two differentials.

32407

Rate this question:

Next Question

Previous Question | Tag Question

Feedback | End Session

Difficulty: Average

Peer Responses %

Session Progress

Responses Correct:	0
Responses Incorrect:	146
Responses Total:	146
Responses - % Correct:	0%

© Pastest 2017

This 72-year-old female presents with several months' history of dyspnoea, cough and weight loss. There is a history of COPD for which she takes seretide BD, and coarse crackles and wheeze consistent with the diagnosis are evident on auscultation.

Her Postero-anterior (PA) and lateral chest radiographs are shown below:

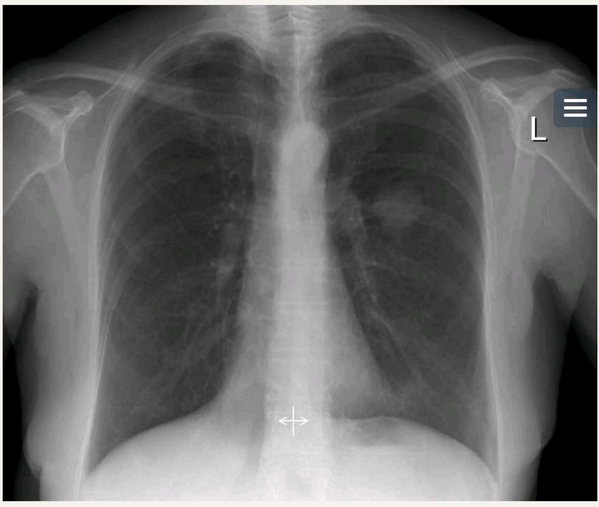

Which of the following investigations is most appropriate to confirm the diagnosis?

A	Fibre-optic bronchoscopy ± transbronchial biopsy
B	CT guided fine-needle aspiration biopsy
C	Respiratory function tests
D	Sputum for cytology
E	Mediastinoscopy

32408

Submit

Previous Question | Skip Question

Calculator

Normal Values

© Pastest 2017

This 72-year-old female presents with several months' history of dyspnoea, cough and weight loss. There is a history of COPD for which she takes seretide BD, and coarse crackles and wheeze consistent with the diagnosis are evident on auscultation.

Her Postero-anterior (PA) and lateral chest radiographs are shown below:

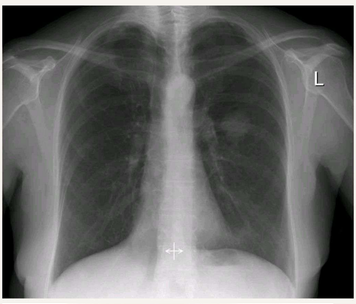

Which of the following investigations is most appropriate to confirm the diagnosis?

A	Fibre-optic bronchoscopy ± transbronchial biopsy
B	CT guided fine-needle aspiration biopsy
C	Respiratory function tests
D	Sputum for cytology
E	Mediastinoscopy

Explanation

A Fibre-optic bronchoscopy ± transbronchial biopsy

The combination of the history with a solitary lung nodule on chest X-ray is highly suggestive of bronchial carcinoma. Bronchoscopy enables the tumour to be directly visualised and samples taken for cytology and histology. The extent of carinal involvement can also be seen – if the tumour involves the first 2 cm of either main bronchus, it is deemed inoperable.

B CT guided fine-needle aspiration biopsy

The combination of the history with a solitary lung nodule on chest X-ray is highly suggestive of bronchial carcinoma. CT-guided FNA carries more risk than bronchoscopy, and the lesion should be easily accessible via the bronchoscopy route. CT scanning of the thorax is however still useful in assessing involvement of the mediastinum and lymph nodes. If surgery is being considered, it should be extended to the abdomen and brain to exclude distant metastases.

C Respiratory function tests

The combination of the history with a solitary lung nodule on chest X-ray is highly suggestive of bronchial carcinoma. Respiratory function tests are not useful in diagnosis, but are essential if pneumonectomy is being considered, as a forced expiratory volume (FEV_1) of <2.0 l means that there will in all likelihood be insufficient respiratory reserve post surgery.

D Sputum for cytology

The combination of the history with a solitary lung nodule on chest X-ray is highly suggestive of bronchial carcinoma. This option is incorrect, because sputum cytology is a low-yield diagnostic tool. It is unlikely to be able to provide enough malignancy cells from a sputum sample in order to make a histological diagnosis. In addition, the patient may not even be producing sputum. If an infective diagnosis is being considered, sputum induction could be carried out in order to obtain a sample.

E Mediastinoscopy

The combination of the history with a solitary lung nodule on chest X-ray is highly suggestive of bronchial carcinoma. Mediastinoscopy is an invasive procedure that involves making an incision in the anterior chest wall in order to introduce the endoscope. It is used to obtain mediastinal lymph node biopsies, for example, for staging lymph nodes involved in lung cancer or for the diagnosis of sarcoidosis or lymphoma. However, on reviewing the above chest radiographs, the mass should be easily accessible using the less invasive technique of bronchoscopy, so this should preclude mediastinoscopy.

32408

Rate this question:

Next Question

Previous Question | Tag Question

Feedback | End Session

Difficulty: Average

Peer Responses %

Session Progress

Responses Correct:	0
Responses Incorrect:	147
Responses Total:	147
Responses - % Correct:	0%

Blog About Pastest Contact Us Help

© Pastest 2017

A 45-year-old computer software firm owner presents with increasing breathlessness over the past few months. He has previously been fit and well and has installed a home gym, swimming pool and hot tub/steam room to use for personal training around 18 months ago. He is a non-smoker and has a previous history of asthma as a child. Examination reveals crackles and high-pitched wheeze throughout the lung fields.

Which of the following is the most appropriate intervention in this case?

A	Inhaled corticosteroids
B	Oral corticosteroids
C	Oral antifungals
D	Repainting and ventilation in the steam room
E	Oral antibiotics

32409

Submit

Previous Question | Skip Question

Calculator

Normal Values

© Pastest 2017

A 45-year-old computer software firm owner presents with increasing breathlessness over the past few months. He has previously been fit and well and has installed a home gym, swimming pool and hot tub/steam room to use for personal training around 18 months ago. He is a non-smoker and has a previous history of asthma as a child. Examination reveals crackles and high-pitched wheeze throughout the lung fields.

Which of the following is the most appropriate intervention in this case?

A	Inhaled corticosteroids
B	Oral corticosteroids
C	Oral antifungals
D	Repainting and ventilation in the steam room
E	Oral antibiotics

Explanation

Treatment of hypersensitivity pneumonitis, (the diagnosis in this case), centres on allergen avoidance. Cladosporum is found in association with ceiling mould and is a source of 'hot-tub lung'; as such it is the most likely cause of his symptoms. Other moulds known to lead to hypersensitivity include micropolyspora, aspergillus and thermoactinomycetes, which are associated with mouldy hay, mushroom compost and contaminated water in humidifiers. Trichosporum is associated with house dust. In this case the likely source is the steam room, hence repainting and adequate ventilation should prevent further exposure. Oral corticosteroids may be given for an initial period to kick-start the recovery in symptoms. However if strict allergen avoidance is not practised, his symptoms will not completely resolve.

32409

Rate this question:

Next Question

Previous Question | Tag Question

Feedback | End Session

Difficulty: Average

Peer Responses %

Session Progress

Responses Correct:	0
Responses Incorrect:	148
Responses Total:	148
Responses - % Correct:	0%

© Pastest 2017

A 35-year-old woman presents to her general practitioner complaining of breathlessness. The only history of note is that her mother died of a respiratory illness of unknown aetiology during her early 40s. She is a non-smoker who works as a secretary in a solicitor's office. On examination her blood pressure is 122/72 mmHg, pulse is 85/min and regular. There are scattered crackles more marked at the lung bases on auscultation of the chest. Routine bloods are normal, although her chest X-ray reveals a surprising finding, with fine micronodular calcification seen, predominantly in the lung bases and around the hilae. Pulmonary function testing reveals a restrictive defect.

Which of the following diagnoses fits best with this clinical picture?

A	Sarcoidosis
B	Obliterative bronchiolitis
C	Alveolar cell carcinoma
D	Alveolar microlithiasis
E	Constrictive bronchiolitis

32410

Submit

Previous Question | Skip Question

Calculator

Normal Values

Blog About Pastest Contact Us Help

© Pastest 2017

A 35-year-old woman presents to her general practitioner complaining of breathlessness. The only history of note is that her mother died of a respiratory illness of unknown aetiology during her early 40s. She is a non-smoker who works as a secretary in a solicitor's office. On examination her blood pressure is 122/72 mmHg, pulse is 85/min and regular. There are scattered crackles more marked at the lung bases on auscultation of the chest. Routine bloods are normal, although her chest X-ray reveals a surprising finding, with fine micronodular calcification seen, predominantly in the lung bases and around the hilae. Pulmonary function testing reveals a restrictive defect.

Which of the following diagnoses fits best with this clinical picture?

A	Sarcoidosis
B	Obliterative bronchiolitis
C	Alveolar cell carcinoma
D	Alveolar microlithiasis
E	Constrictive bronchiolitis

Explanation

This rare condition, sometimes familial with autosomal recessive inheritance, is associated with the deposition of diffuse calcified microliths in the alveolar space. In familial cases there is often a 2:1 female preponderance. Chest X-ray or computed tomography (CT) scan may confirm micronodular calcification, and there is a progressive restrictive lung defect. Unfortunately progressive calcium deposition leads to respiratory failure. No medical intervention has proved successful, although lung transplantation has been used in some cases. So much calcium is deposited, that lungs examined at post mortem have been reported to be so stiff as to require a saw to enable sectioning for examination.

© Pastest 2017

A 67-year-old man with a 60 pack year smoking history is admitted with an acute respiratory tract infection. On further questioning he admitted to progressive dyspnoea, wheeze and productive cough for some years. Examination reveals changes consistent with obstructive lung disease; in addition he has swollen ankles. Chest X-ray reveals hyperinflated lung fields and large bullae, particularly prominent at the apices. His infection settles over the course of 3 days with IV antibiotics and nebulisers, he is discharged, and he attends for review some six weeks later. Spirometry before the clinic appointment reveals that FEV_1 is 40% predicted with little reversibility.

According to current available evidence, which of the following is the most appropriate prescription (apart from smoking cessation) for maintenance therapy?

A	Inhaled corticosteroids in combination with long acting beta agonist
B	Inhaled salbutamol
C	Inhaled long acting beta agonist
D	Inhaled ipratropium
E	Oral corticosteroids

32411

Submit

Previous Question | Skip Question

Calculator

Normal Values

© Pastest 2017

A 67-year-old man with a 60 pack year smoking history is admitted with an acute respiratory tract infection. On further questioning he admitted to progressive dyspnoea, wheeze and productive cough for some years. Examination reveals changes consistent with obstructive lung disease; in addition he has swollen ankles. Chest X-ray reveals hyperinflated lung fields and large bullae, particularly prominent at the apices. His infection settles over the course of 3 days with IV antibiotics and nebulisers, he is discharged, and he attends for review some six weeks later. Spirometry before the clinic appointment reveals that FEV_1 is 40% predicted with little reversibility.

According to current available evidence, which of the following is the most appropriate prescription (apart from smoking cessation) for maintenance therapy?

A	Inhaled corticosteroids in combination with long acting beta agonist
B	Inhaled salbutamol
C	Inhaled long acting beta agonist
D	Inhaled ipratropium
E	Oral corticosteroids

Explanation

These should be prescribed to all chronic obstructive pulmonary disease (COPD) patients with FEV_1 (forced expiratory volume in 1 s) less than or equal to 50% of predicted. Trials have shown a decrease in exacerbation frequency with inhaled corticosteroids, but no arrest in the decline in lung function. More recently, trials of high-dose inhaled corticosteroids in combination with long-acting beta agonists have shown some arrest in decline in lung function at the expense of increased episodes of pneumonia. Inhaled short-acting anticholinergics have shown no effects on decline in lung function. Whilst trials of the long-acting cholinergic agent tiotropium have demonstrated a benefit, an increased risk of cerebral vascular events has been identified.

32411

Rate this question:

Next Question

Previous Question | Tag Question

Feedback | End Session

Difficulty: Average

Peer Responses %

Session Progress

Responses Correct:	0
Responses Incorrect:	150
Responses Total:	150
Responses - % Correct:	0%

© Pastest 2017

You are asked to review a 64-year-old man with a history of chronic obstructive pulmonary disease (COPD), prior to planned surgery for a large inguinal hernia. You take a history and examine him.

Which of the following features is likely to impact most on increased peri-operative risk?

A	Lower abdominal surgery
B	CO_2 level of 6.2 kPa on air-breathing arterial blood gas sample
C	FEV_1 (forced expiratory volume in 1 s) of 1.4 l
D	Past history of hypertension
E	Ability to walk 1.2 miles

32412

Submit

Previous Question | Skip Question

Calculator

Normal Values

© Pastest 2017

You are asked to review a 64-year-old man with a history of chronic obstructive pulmonary disease (COPD), prior to planned surgery for a large inguinal hernia. You take a history and examine him.

Which of the following features is likely to impact most on increased peri-operative risk?

A	Lower abdominal surgery
B	CO_2 level of 6.2 kPa on air-breathing arterial blood gas sample
C	FEV_1 (forced expiratory volume in 1 s) of 1.4 l
D	Past history of hypertension
E	Ability to walk 1.2 miles

Explanation

A raised CO_2 on air would have most impact on increased peri-operative risk in this case. Other factors to consider include length of anaesthetic, current smoking status, FEV_1 (forced expiratory volume in 1 s) less than 0.8 l, obesity, poor performance or cardiac status. Whilst epidural anaesthesia may offer a reduction in peri-operative risk in this case, atelectasis due to continued abdominal pain is still associated with increased incidence of post-operative lower respiratory tract infection. Post-operative pain relief and aggressive physiotherapy support are therefore essential components of treatment.

32412

Rate this question:

Next Question

Previous Question | Tag Question

Feedback | End Session

Difficulty: Average

Peer Responses %

Session Progress

Responses Correct:	0
Responses Incorrect:	151
Responses Total:	151
Responses - % Correct:	0%

© Pastest 2017

A 54-year-old smoker presents with a syncopal episode in church. On further questioning he admits to increasing breathlessness with a cough productive of bloody sputum over the past few months and severe unremitting headaches which are worse if he sits forward. There has been gradual weight loss of 5kg over the past 6 months. Examination reveals facial and upper body oedema, with a plethoric appearance and distended superficial veins on the chest wall. His blood pressure is significantly elevated at 177/80 mmHg.

Which of the following is the most likely diagnosis in this case?

A	Inferior vena cava obstruction
B	Superior vena cava obstruction
C	Pulmonary artery obstruction
D	Tricuspid regurgitation
E	Right heart failure

32424

Submit

Previous Question | Skip Question

Calculator

Normal Values

© Pastest 2017

A 54-year-old smoker presents with a syncopal episode in church. On further questioning he admits to increasing breathlessness with a cough productive of bloody sputum over the past few months and severe unremitting headaches which are worse if he sits forward. There has been gradual weight loss of 5kg over the past 6 months. Examination reveals facial and upper body oedema, with a plethoric appearance and distended superficial veins on the chest wall. His blood pressure is significantly elevated at 177/80 mmHg.

Which of the following is the most likely diagnosis in this case?

A	Inferior vena cava obstruction
B	Superior vena cava obstruction
C	Pulmonary artery obstruction
D	Tricuspid regurgitation
E	Right heart failure

Explanation

Superior vena cava obstruction (SVCO) presents with this clinical picture and may occur via external compression or invasion of the superior vena cava by tumour, external compression from lymph nodes or another mediastinal structure, or due to thrombosis in the vein. Up to 4% of patients with lung cancer patients will develop superior vena cava obstruction (SVCO) at some point during their disease. Up to 10% of small-cell lung cancers will present with SVCO. SVCO is much more likely to be associated with right-sided lesions (four times more commonly than with left lung lesions). Chest X-ray is abnormal in around 85% of patients with SVCO, mediastinal widening is common. Other causes include lymphoma, thymoma, mediastinal germ cell tumours, and metastatic carcinomas from other sites (eg breast in women).

32424

Rate this question:

Next Question

Previous Question | Tag Question

Feedback | End Session

Difficulty: Average

Peer Responses %

Session Progress

Responses Correct:	0
Responses Incorrect:	152
Responses Total:	152
Responses - % Correct:	0%

© Pastest 2017

A 24-year-old man with a known history of cystic fibrosis presents as a self-admission to the ward. He has increased volume of purulent sputum, more shortness of breath and left-sided chest ache. On reviewing his history you note that he is under consideration for the transplant list, and has been colonised with pseudomonas for some years. On examination he is pyrexial with a temperature of 38.2° C, and appears very unwell with FEV_1 (forced expiratory volume in 1 s) having fallen to below 75% of the previous recorded value. He is hypotensive and tachycardic with a respiratory rate of 32/min.

Which of the following micro-organisms would fit best with this pattern of deterioration?

A	Haemophilus influenzae
B	Staphylococcus aureus
C	Pseudomonas aeruginosa
D	Burkholderia cepacia
E	Stenotrophomonas multiphilia

32425

Submit

Previous Question | Skip Question

Calculator

Normal Values

© Pastest 2017

A 24-year-old man with a known history of cystic fibrosis presents as a self-admission to the ward. He has increased volume of purulent sputum, more shortness of breath and left-sided chest ache. On reviewing his history you note that he is under consideration for the transplant list, and has been colonised with pseudomonas for some years. On examination he is pyrexial with a temperature of 38.2° C, and appears very unwell with FEV_1 (forced expiratory volume in 1 s) having fallen to below 75% of the previous recorded value. He is hypotensive and tachycardic with a respiratory rate of 32/min.

Which of the following micro-organisms would fit best with this pattern of deterioration?

A	Haemophilus influenzae
B	Staphylococcus aureus
C	Pseudomonas aeruginosa
D	Burkholderia cepacia
E	Stenotrophomonas multiphilia

Explanation

Cepacia syndrome is associated with a severe worsening of respiratory symptoms in a small number of patients with cystic fibrosis,. Thankfully the majority of patients colonised with Cepacia do not however suffer a deterioration in their underlying condition. Cepacia is known to demonstrate resistance to multiple antibiotics including colomycin and aminioglycosides, hence intravenous regimes involving two or more antibiotics such as ceftazidime and an aminoglycoside should be employed. Other possible combinations include ceftazidime and chloramphenicol or chloramphenicol and minocycline. Approximately 2.5-3% of cystic fibrosis individuals are thought to be colonised with cepacia, and measures are usually taken to limit colonisation where possible.

32425

Rate this question:

Next Question

Previous Question | Tag Question

Feedback | End Session

Difficulty: Average

Peer Responses %

Session Progress

Responses Correct:	0
Responses Incorrect:	153
Responses Total:	153
Responses - % Correct:	0%

© Pastest 2017

A 34-year-old woman presents with increasing breathlessness, complaining that she is unable to chase after her 4-year-old child anymore. She also complains of chest pain and light-headedness and has recently noticed swelling of the ankles. There is no past medical history of note, particularly with respect to chronic chest disease or venous thromboses. On examination her body mass index (BMI) is 24, the jugular venous pressure (JVP) is elevated, there is evidence of tricuspid regurgitation and right heart failure. Chest X-ray shows enlargement of the pulmonary vessels. An echocardiogram is arranged which shows markedly elevated right-sided pressures. There is hypoxia and hypocapnia on arterial blood gas estimation, with desaturation on exercise. Ventilation–perfusion scan is unremarkable.

Which of the following diagnoses fits best with this clinical picture?

A	Multiple thromboembolic disease
B	Previous right ventricular myocardial infarction
C	Primary pulmonary hypertension
D	Secondary pulmonary hypertension
E	Lung fibrosis

32426

Submit

Previous Question | Skip Question

Calculator

Normal Values

© Pastest 2017

A 34-year-old woman presents with increasing breathlessness, complaining that she is unable to chase after her 4-year-old child anymore. She also complains of chest pain and light-headedness and has recently noticed swelling of the ankles. There is no past medical history of note, particularly with respect to chronic chest disease or venous thromboses. On examination her body mass index (BMI) is 24, the jugular venous pressure (JVP) is elevated, there is evidence of tricuspid regurgitation and right heart failure. Chest X-ray shows enlargement of the pulmonary vessels. An echocardiogram is arranged which shows markedly elevated right-sided pressures. There is hypoxia and hypocapnia on arterial blood gas estimation, with desaturation on exercise. Ventilation–perfusion scan is unremarkable.

Which of the following diagnoses fits best with this clinical picture?

A	Multiple thromboembolic disease
B	Previous right ventricular myocardial infarction
C	Primary pulmonary hypertension
D	Secondary pulmonary hypertension
E	Lung fibrosis

Explanation

Mean age at presentation for Primary Pulmonary Hypertension is 36 years; patients characteristically complain of exertional dyspnoea, syncope and symptoms of right heart failure. Diagnosis is confirmed with echocardiogram, right heart catheterisation and computed tomography (CT) pulmonary angiogram or ventilation–perfusion scan to rule out significant thromboembolic disease. Autoantibodies such as anti-SCL-70 and anti-centromere may point to associated connective tissue disease.

32426

Rate this question:

Next Question

Previous Question | Tag Question

Feedback | End Session

Difficulty: Average

Peer Responses %

Session Progress

Responses Correct:	0
Responses Incorrect:	154
Responses Total:	154
Responses - % Correct:	0%

© Pastest 2017

A 52-year-old immigrant from the Balkans presents for review. Over the past few months he has suffered a number of fevers and night sweats and has lost a significant amount of weight. A chest X-ray reveals a small to moderately sized right sided pleural effusion. Tuberculin skin testing is positive. Tapping of the fluid reveals a lymphocytosis, although staining for acid and alkali fast bacilli (AAFB) is negative, and protein count is 41 g/l.

What diagnosis fits best with this clinical picture?

A	Lymphomatous pleural effusion
B	Tuberculous pleural effusion
C	Para-pneumonic effusion
D	Carcinomatous pleural effusion
E	Transudate effusion secondary to heart failure

32427

Submit

Previous Question | Skip Question

Calculator

Normal Values

© Pastest 2017

A 52-year-old immigrant from the Balkans presents for review. Over the past few months he has suffered a number of fevers and night sweats and has lost a significant amount of weight. A chest X-ray reveals a small to moderately sized right sided pleural effusion. Tuberculin skin testing is positive. Tapping of the fluid reveals a lymphocytosis, although staining for acid and alkali fast bacilli (AAFB) is negative, and protein count is 41 g/l.

What diagnosis fits best with this clinical picture?

A	Lymphomatous pleural effusion
B	Tuberculous pleural effusion
C	Para-pneumonic effusion
D	Carcinomatous pleural effusion
E	Transudate effusion secondary to heart failure

Explanation

TB effusions present with this pattern of symptoms, accompanied by a small to moderate effusion rich in lymphocytes. Acid and alkali fast bacilli (AAFB) staining is only positive in 5–10%, although cultures are positive in 25% of cases over 2–6 weeks. Induced sputum or polymerase chain reaction (PCR) for TB done at a specialist centre may improve the diagnostic yield, as may pleural biopsy. Fluid volumes may increase during anti-tuberculous therapy; corticosteroids are associated with reduced fluid volume but have no effect on outcome, and pleural thickening and calcification unfortunately occurs commonly. A lymphomatous effusion would be less likely to fit with this patient demographic, and tuberculin skin testing and the point that he has come from the Balkan's are pointers to underlying TB.

32427

Rate this question:

Next Question

Previous Question | Tag Question

Feedback | End Session

Difficulty: Average

Peer Responses %

Session Progress

Responses Correct:	0
Responses Incorrect:	155
Responses Total:	155
Responses - % Correct:	0%

© Pastest 2017

A 67-year-old man presents with increasing shortness of breath, cough at night and pleuritic chest pain. He has a past history of myocardial infarction and left ventricular failure and a 40 pack year smoking history. Medication includes ramipril, furosemide and amlodipine Last year he was prescribed amiodarone for paroxysmal ventricular tachycardia and he has taken the medication since then. On examination his blood pressure is 142/85 mmHg, pulse is 85/min and there are scattered crackles on auscultation with evidence of a left-sided pleural effusion. Chest X-ray reveals evidence of lung infiltration with focal opacities and confirms a small left-sided pleural effusion.

Which of the following diagnoses fits best with this clinical picture?

A	Left ventricular failure
B	Amiodarone toxicity
C	Angiotensin-converting enzyme (ACE) inhibitor-induced lung fibrosis
D	Idiopathic pulmonary fibrosis
E	Chronic obstructive pulmonary disease

32428

Submit

Previous Question Skip Question

Calculator

Normal Values

Blog About Pastest Contact Us Help

© Pastest 2017

A 67-year-old man presents with increasing shortness of breath, cough at night and pleuritic chest pain. He has a past history of myocardial infarction and left ventricular failure and a 40 pack year smoking history. Medication includes ramipril, furosemide and amlodipine Last year he was prescribed amiodarone for paroxysmal ventricular tachycardia and he has taken the medication since then. On examination his blood pressure is 142/85 mmHg, pulse is 85/min and there are scattered crackles on auscultation with evidence of a left-sided pleural effusion. Chest X-ray reveals evidence of lung infiltration with focal opacities and confirms a small left-sided pleural effusion.

Which of the following diagnoses fits best with this clinical picture?

A	Left ventricular failure
B	Amiodarone toxicity
C	Angiotensin-converting enzyme (ACE) inhibitor-induced lung fibrosis
D	Idiopathic pulmonary fibrosis
E	Chronic obstructive pulmonary disease

Explanation

Amiodarone toxicity occurs in approximately 5% of patients. This can vary from acute respiratory distress to a picture of cough, pleuritic chest pain, pulmonary infiltrates and small pleural effusions, to interstitial pneumonitis and eventually progressive pulmonary fibrosis. Due to its long half life, amiodarone toxicity takes some weeks to resolve; as such corticosteroids are added when therapy is discontinued as this may lead to more rapid resolution of symptoms. Of course cardiology input is vital before amiodarone is discontinued; as in this case when paroxysmal VT is the indication for therapy, an implantable cardioverter debrillator is the next logical step.

32428

Rate this question:

Next Question

Previous Question | Tag Question

Feedback | End Session

Difficulty: Average

Peer Responses %

Session Progress

Responses Correct:	0
Responses Incorrect:	156
Responses Total:	156
Responses - % Correct:	0%

© Pastest 2017

A 42-year-old street dweller is admitted with confusion, fever and shortness of breath. He is well known to the emergency department and has presented on a number of occasions with alcohol intoxication. On examination he is pyrexial at 38.6°C. He has a cough productive of purulent and blood-stained sputum. Auscultation of the chest reveals findings consistent with left-sided consolidation and chest X-ray confirms consolidation and evidence of cavitation with abscess formation.

Which of the following is the most likely diagnosis?

A	Chlamydia psittaci
B	Haemophilus influenzae
C	Klebsiella pneumoniae
D	Staphylococcus aureus
E	Streptococcus pyogenes

32429

Submit

Previous Question | Skip Question

Calculator

Normal Values

© Pastest 2017

A 42-year-old street dweller is admitted with confusion, fever and shortness of breath. He is well known to the emergency department and has presented on a number of occasions with alcohol intoxication. On examination he is pyrexial at 38.6°C. He has a cough productive of purulent and blood-stained sputum. Auscultation of the chest reveals findings consistent with left-sided consolidation and chest X-ray confirms consolidation and evidence of cavitation with abscess formation.

Which of the following is the most likely diagnosis?

A	Chlamydia psittaci
B	Haemophilus influenzae
C	Klebsiella pneumoniae
D	Staphylococcus aureus
E	Streptococcus pyogenes

Explanation

This patient has pneumonia with evidence of lung abscess formation. Given his history of alcoholism and the fact there is evidence of cavitation on chest x-ray, Klebsiella is a likely cause. Staphylococcus aureus is also associated with cavitation and abscess formation but occurs more commonly after an episode of influenza. Third generation cephalosporins or quinolones provide coverage for community acquired infection, macrolides do not. Mortality is particularly high in patients with a history of alcoholism, potentially as a result of poor nutrition and defective immunity associated with chronic excess alcohol consumption.

32429

Rate this question:

Next Question

Previous Question | Tag Question

Feedback | End Session

Difficulty: Average

Peer Responses %

Session Progress

Responses Correct:	0
Responses Incorrect:	157
Responses Total:	157
Responses - % Correct:	0%

© Pastest 2017

A 49-year-old male head teacher presents with a progressive shortness of breath on exertion for the last six months. He has also suffered from joint pains over the last few months and an erythematous rash affecting sun exposed areas during the summer months. He has previously been fit and has had no medical consultations for 25 years. He does not smoke. On examination his BP is 155/82 mmHg, pulse is 82/min and regular, BMI 22, there are occasional crackles on auscultation of his chest. Full blood count and renal function are within normal limits, but autoantibodies are positive for anti-nuclear antibodies.
Lung function test results are as follows:

	Actual	Predicted
FEV_1 (L/min)	1.4	2.0 - 2.8
VC (L)	1.6	2.4 - 3.4
FEV_1/VC	88%	
TLCO (mL/min/mmHg)	2.8	3.5 - 7.3
KCO	0.9	1.2 - 1.8

Which of the following is the most likely underlying diagnosis with respect to his lung function?

A	Asthma
B	SLE
C	Pulmonary haemorrhage
D	Idiopathic pulmonary fibrosis
E	Multiple pulmonary emboli

32430

Submit

Previous Question | Skip Question

Calculator

Normal Values

© Pastest 2017

A 49-year-old male head teacher presents with a progressive shortness of breath on exertion for the last six months. He has also suffered from joint pains over the last few months and an erythematous rash affecting sun exposed areas during the summer months. He has previously been fit and has had no medical consultations for 25 years. He does not smoke. On examination his BP is 155/82 mmHg, pulse is 82/min and regular, BMI 22, there are occasional crackles on auscultation of his chest. Full blood count and renal function are within normal limits, but autoantibodies are positive for anti-nuclear antibodies.
Lung function test results are as follows:

	Actual	Predicted
FEV_1 (L/min)	1.4	2.0 - 2.8
VC (L)	1.6	2.4 - 3.4
FEV_1/VC	88%	
TLCO (mL/min/mmHg)	2.8	3.5 - 7.3
KCO	0.9	1.2 - 1.8

Which of the following is the most likely underlying diagnosis with respect to his lung function?

A	Asthma
B	SLE
C	Pulmonary haemorrhage
D	Idiopathic pulmonary fibrosis
E	Multiple pulmonary emboli

Explanation

The results show reduced lung volumes with normal FEV_1/VC ratio and impaired gas transfer. The diagnosis is interstitial lung disease, of which the most common in this age group are idiopathic fibrosing alveolitis, and fibrosing alveolitis secondary to connective tissue disease, sarcoidosis and pneumoconiosis.
Spirometry shows reduced lung volumes with FEV_1/FVC ratio > 75%. Gas transfer is also impaired (low KCO).
The history of polyarthritis, photosensitive rash and positive anti-nuclear antibodies fits best with a diagnosis of SLE. Asthma would be supported by an obstructive defect, pulmonary haemorrhage would be expected to have a shorter time course, and multiple pulmonary emboli might be more likely with underlying obesity and inactivity, not usually associated with a restrictive lung defect.

32430

Rate this question:

Next Question

Previous Question | Tag Question

Feedback | End Session

Difficulty: Average

Peer Responses %

Session Progress

Responses Correct:	0
Responses Incorrect:	158
Responses Total:	158
Responses - % Correct:	0%

© Pastest 2017

A 25-year-old teacher presents with a 3-year history of recurrent chest infections that never really completely resolved after completing a course of antibiotics. She has a cough most days and produces large volumes of green sputum on a daily basis. She has had mild haemoptysis in the past. She has noticed weight loss over the past year with increased lethargy and shortness of breath on exertion. She has no previous past medical history and is not on any regular medications. On examination she has clubbing and coarse inspiratory crackles in both her bases, which are worse on the right side. She is 135 cm in height, apparently significantly shorter than her brothers and sisters.

Which of the following tests is most likely to contribute to determining her underlying diagnosis?

A	cANCA (anti-neutrophil cytoplasmic antigen)
B	Delta F508 mutation
C	Hepatitis screen
D	Alpha-1-antitrypsin testing
E	E ESR (erythrocyte sedimentation rate)

32431

Submit

Previous Question Skip Question

Calculator

Normal Values

Blog About Pastest Contact Us Help

© Pastest 2017

A 25-year-old teacher presents with a 3-year history of recurrent chest infections that never really completely resolved after completing a course of antibiotics. She has a cough most days and produces large volumes of green sputum on a daily basis. She has had mild haemoptysis in the past. She has noticed weight loss over the past year with increased lethargy and shortness of breath on exertion. She has no previous past medical history and is not on any regular medications. On examination she has clubbing and coarse inspiratory crackles in both her bases, which are worse on the right side. She is 135 cm in height, apparently significantly shorter than her brothers and sisters.

Which of the following tests is most likely to contribute to determining her underlying diagnosis?

A	cANCA (anti-neutrophil cytoplasmic antigen)
B	Delta F508 mutation
C	Hepatitis screen
D	Alpha-1-antitrypsin testing
E	E ESR (erythrocyte sedimentation rate)

Explanation

B	Delta F508 mutation

The patient clinically has bronchiectasis with coarse inspiratory crackles and clubbing and a history of copious purulent sputum and cough. A number of causes exist with respect to bronchiectasis in this age group, but heterozygosity for the cystic fibrosis CFTR mutation is increasingly recognised as being associated with the disease.

A	cANCA (anti-neutrophil cytoplasmic antigen)

ANCA-positive vasculitis may be associated with pulmonary disease, although pulmonary haemorrhage is the usual presentation.

C	Hepatitis screen

Viral hepatitis is not usually associated with bronchiectasis, although evidence of cirrhosis may co-exist with emphysema in patients with alpha-1-antitrypsin deficiency.

D	Alpha-1-antitrypsin testing

Alpha-1 antitrypsin deficiency is associated with the development of emphysema, rather than bronchiectasis.

E	E ESR (erythrocyte sedimentation rate)

ESR is a non-specific marker of pulmonary inflammation or infection, and is therefore not useful in identifying the underlying cause of her symptoms.

32431

Rate this question:

Next Question

Previous Question	Tag Question
Feedback	End Session

Difficulty: Average

Peer Responses %

Session Progress

Responses Correct:	0
Responses Incorrect:	159
Responses Total:	159
Responses - % Correct:	0%

© Pastest 2017

A 73-year-old man is sent to the Emergency room by ambulance after a GP home visit. The GP found him to be extremely short of breath, with a cough productive of rust-coloured sputum. He has herpetic lesions at the corner of his mouth. On examination he has right-sided crackles and bronchial breathing consistent with pneumonia. His blood pressure is 105/65 mmHg. His abbreviated mental test (AMT) is 10.

Investigations:

Hb	119 g/l
WCC	13.9 × 10^9/l
PLT	203 × 10^9/l
Na+	137 mmol/l
K+	4.8 mmol/l
Creatinine	87 mol/l
Urea	9.2 mmol/l

You use the British Thoracic Society Community Acquired Pneumonia Severity Score (CURB-65) criteria to assess the severity of infection with respect to the need for HDU/ITU.

Which of the following features is associated with a poor prognosis as identified by CURB criteria?

A	AMT score of 10
B	Urea 9.2 mmol/l
C	Systolic BP of 105 mmHg
D	Diastolic BP of 65 mmHg
E	Creatinine of 87 micromol/l

32432

Submit

Previous Question | Skip Question

Calculator

Normal Values

© Pastest 2017

A 73-year-old man is sent to the Emergency room by ambulance after a GP home visit. The GP found him to be extremely short of breath, with a cough productive of rust-coloured sputum. He has herpetic lesions at the corner of his mouth. On examination he has right-sided crackles and bronchial breathing consistent with pneumonia. His blood pressure is 105/65 mmHg. His abbreviated mental test (AMT) is 10.

Investigations:

Hb	119 g/l
WCC	13.9 × 10^9/l
PLT	203 × 10^9/l
Na+	137 mmol/l
K+	4.8 mmol/l
Creatinine	87 mol/l
Urea	9.2 mmol/l

You use the British Thoracic Society Community Acquired Pneumonia Severity Score (CURB-65) criteria to assess the severity of infection with respect to the need for HDU/ITU.

Which of the following features is associated with a poor prognosis as identified by CURB criteria?

A	AMT score of 10
B	Urea 9.2 mmol/l
C	Systolic BP of 105 mmHg
D	Diastolic BP of 65 mmHg
E	Creatinine of 87 micromol/l

Explanation

B	Urea 9.2 mmol/l

Urea is one of the variables assessed in the CURB criteria, where a level of >7 mmol/l is associated with a poor prognostic outcome. Other criteria not listed as part of the options here include age >65 and respiratory rate of 30/min or greater. A score of 3, as in this case, is associated with a risk of mortality of 17% from community-acquired pneumonia. For 5 this rises to a risk of mortality of 57%.

A	AMT score of 10

Confusion with an AMT of 8 or less is associated with a poor prognosis in community-acquired pneumonia.

C	Systolic BP of 105 mmHg

BP criteria used to assess severity in CURB criteria are systolic blood pressure 90 mmHg or less or a diastolic BP of 60 mmHg or less.

D	Diastolic BP of 65 mmHg

The diastolic BP criterion that stratifies poor prognosis in pneumonia is 60 mmHg.

E	Creatinine of 87 micromol/l

Creatinine is not a criterion used to assess prognosis under the CURB criteria.

32432

Rate this question:

Next Question

Previous Question | Tag Question

Feedback | End Session

Difficulty: Average

Peer Responses %

Session Progress

Responses Correct:	0
Responses Incorrect:	160
Responses Total:	160
Responses - % Correct:	0%

External Links

BTS management of CAP
brit-thoracic.org.uk/document-library/clinical-information/pneumonia/adult-pneumo...

© Pastest 2017

A young paint-sprayer who works in a car shop complains of shortness of breath and tiredness over last 2 months. He was prescribed inhalers by GP, but eventually needed a course of steroids for resolution of symptoms. It was found that after a 2-week holiday to Marbella his symptoms had resolved. He then saw GP on return as his symptoms had once again worsened. On examination his BP was 122/72 mmHg, pulse was 75/min and regular and there was scattered wheeze on auscultation of the chest. A peak flow diary revealed a significant reduction, which progressed during the working week and then improved over the weekend.

Which of the following would be the most appropriate intervention?

A	Change of career
B	Oral Monteleukast during the working week
C	Regular inhaled beclomethasone
D	Regular inhaled salmeterol/fluticasone
E	Review of the work environment to ensure exposure to paint fumes is minimised

32433

Submit

Previous Question Skip Question

Calculator

Normal Values

Blog About Pastest Contact Us Help

© Pastest 2017

A young paint-sprayer who works in a car shop complains of shortness of breath and tiredness over last 2 months. He was prescribed inhalers by GP, but eventually needed a course of steroids for resolution of symptoms. It was found that after a 2-week holiday to Marbella his symptoms had resolved. He then saw GP on return as his symptoms had once again worsened. On examination his BP was 122/72 mmHg, pulse was 75/min and regular and there was scattered wheeze on auscultation of the chest. A peak flow diary revealed a significant reduction, which progressed during the working week and then improved over the weekend.

Which of the following would be the most appropriate intervention?

A	Change of career
B	Oral Monteleukast during the working week
C	Regular inhaled beclomethasone
D	Regular inhaled salmeterol/fluticasone
E	Review of the work environment to ensure exposure to paint fumes is minimised

Explanation

E	Review of the work environment to ensure exposure to paint fumes is minimised

The most likely cause of this man's symptoms is occupational asthma. A number of substances such as paint spray (isocyanates) and soldering kit (colophony fumes) used on cars are possible causes of the illness. In the first instance his working environment should be examined to ensure that exposure to fumes is minimised, both for his own health and for others in the same work environment. If changes do not improve his symptoms then he should be offered alternative work, as a commitment to regular asthma therapy is suboptimal in this situation.

A	Change of career

A change of career is only appropriate if despite minimising exposure to paint fumes, symptoms persist. A career change is preferable versus starting regular asthma therapy.

B	Oral Monteleukast during the working week

Oral Monteleukast is a treatment option for patients who fail to respond to high-dose inhaled corticosteroids or to the combination of inhaled corticosteroids and a long-acting beta agonist. It should not be used in lieu of a review of the working environment.

C	Regular inhaled beclomethasone

Regular inhaled beclomethasone is the initial intervention for patients with asthma not related to precipitating factors in the work environment and who do not respond to PRN salbutamol.

D	Regular inhaled salmeterol/fluticasone

Combination inhaled corticosteroid and long-acting beta agonist preparations are used for patients who fail to respond to inhaled corticosteroids alone.

32433

Rate this question:

Next Question

Previous Question | Tag Question

Feedback | End Session

Difficulty: Average

Peer Responses %

Session Progress

Responses Correct:	0
Responses Incorrect:	161
Responses Total:	161
Responses - % Correct:	0%

© Pastest 2017

A 62-year-old man attends for a chest X-ray as part of a medical prior to emigrating to Australia. Unfortunately the chest X-ray reveals a number of rounded opacities predominantly in the left lung field, all less than 3 cm in diameter. He has had 5 kg of unintentional weight loss over the past year but no other history of note.

Which of the following features would be the strongest pointer to malignancy when the chest X-ray is reviewed?

A	Spiculated margin to one of the nodules, with distortion of neighbouring vessels
B	Smaller lesion size
C	A rounded appearance to the nodules
D	No enhancement with contrast on future CT thorax
E	Age 62 at presentation

32434

Submit

Previous Question | Skip Question

Calculator

Normal Values

© Pastest 2017

A 62-year-old man attends for a chest X-ray as part of a medical prior to emigrating to Australia. Unfortunately the chest X-ray reveals a number of rounded opacities predominantly in the left lung field, all less than 3 cm in diameter. He has had 5 kg of unintentional weight loss over the past year but no other history of note.

Which of the following features would be the strongest pointer to malignancy when the chest X-ray is reviewed?

A	Spiculated margin to one of the nodules, with distortion of neighbouring vessels
B	Smaller lesion size
C	A rounded appearance to the nodules
D	No enhancement with contrast on future CT thorax
E	Age 62 at presentation

Explanation

A	Spiculated margin to one of the nodules, with distortion of neighbouring vessels

A spiculated margin to one of the nodules, particularly when there is distortion of neighbouring vessels, raises the possibility of malignancy. Associated ground-glass shadowing, or the presence of cavitation or pseudo-cavitation within the lesion, increases the chances of malignant disease. CT thorax to further characterise the lesions is indicated.

B	Smaller lesion size

Lesions larger than 3 cm are more likely to be associated with underlying malignancy.

C	A rounded appearance to the nodules

Rounded appearance to the nodules, implying organised growth, is less likely to be associated with an underlying malignancy.

D	No enhancement with contrast on future CT thorax

Enhancement of nodules with contrast on CT thorax increases the likelihood that they are malignant in origin.

E	Age 62 at presentation

Older age at presentation and history of smoking are associated with increased likelihood of malignancy.

32434

Rate this question:

Next Question

Previous Question | Tag Question

Feedback | End Session

Difficulty: Average

Peer Responses %

Session Progress

Responses Correct:	0
Responses Incorrect:	162
Responses Total:	162
Responses - % Correct:	0%

© Pastest 2017

A 20-year-old man has recently started work in the bakery section of his local supermarket. He complains of increasing shortness of breath, cough and wheeze during the course of the working week. These symptoms resolve somewhat at weekends and improved markedly during a week's holiday in Spain. Examination in the clinic on a Monday morning reveals no evidence of wheeze; peak flow is 520 (540 predicted).

Which of the following initial actions is most appropriate in this case?

A	Trial of salbutamol
B	2-hourly peak flow recordings during the week, comparing work to rest periods
C	Chest X-ray
D	Bronchial provocation testing
E	Patch testing

32435

Submit

Previous Question | Skip Question

Calculator

Normal Values

© Pastest 2017

A 20-year-old man has recently started work in the bakery section of his local supermarket. He complains of increasing shortness of breath, cough and wheeze during the course of the working week. These symptoms resolve somewhat at weekends and improved markedly during a week's holiday in Spain. Examination in the clinic on a Monday morning reveals no evidence of wheeze; peak flow is 520 (540 predicted).

Which of the following initial actions is most appropriate in this case?

A	Trial of salbutamol
B	2-hourly peak flow recordings during the week, comparing work to rest periods
C	Chest X-ray
D	Bronchial provocation testing
E	Patch testing

Explanation

B	2-hourly peak flow recordings during the week, comparing work to rest periods

It is important to establish the relationship of deterioration in peak flow to work periods as there is a suspicion of occupational asthma here. Occupational asthma in bakers may occur due to flour dust or to other allergens used in making breads and cakes. Review of the worker's work pattern, allowing for removal of exposure to the potential allergen, is optimal therapy, of course with the cooperation of the employer.

A	Trial of salbutamol

A trial of salbutamol is inappropriate given the likely history of occupational triggers for this patient's asthma. Removal of exposure to any potential allergen is much more important than starting asthma therapy.

C	Chest X-ray

A chest x-ray is not useful when evaluating potential bronchoconstriction related to asthma.

D	Bronchial provocation testing

Bronchial provocation testing should only be undertaken in specialised centres, with appropriate anaesthetist support, and only when there is doubt as to the underlying trigger.

E	Patch testing

Patch testing is rarely useful in evaluating occupational asthma.

32435

Rate this question:

Next Question

Previous Question | Tag Question

Feedback | End Session

Difficulty: Average

Peer Responses %

Session Progress

Responses Correct:	0
Responses Incorrect:	163
Responses Total:	163
Responses - % Correct:	0%

© Pastest 2017

A 45-year-old woman presents with increasing wheeze and paroxysms of coughing. Most recently she has had two episodes of pneumonia in succession and an episode of haemoptysis. She is a non-smoker. Chest X-ray reveals a well-defined single lesion in the right lower lobe. Biopsy of the lesion reveals a multitude of abnormal cells but no necrosis, occasional nuclear pleomorphism and absent mitoses.

Which of the following diagnoses fits best with this clinical picture?

A	Small cell carcinoma of the bronchus
B	Adenocarcinoma of the bronchus
C	Squamous cell carcinoma of the bronchus
D	Organised lung abscess
E	Bronchial carcinoid

32436

Submit

Previous Question | Skip Question

Calculator

Normal Values

© Pastest 2017

A 45-year-old woman presents with increasing wheeze and paroxysms of coughing. Most recently she has had two episodes of pneumonia in succession and an episode of haemoptysis. She is a non-smoker. Chest X-ray reveals a well-defined single lesion in the right lower lobe. Biopsy of the lesion reveals a multitude of abnormal cells but no necrosis, occasional nuclear pleomorphism and absent mitoses.

Which of the following diagnoses fits best with this clinical picture?

A	Small cell carcinoma of the bronchus
B	Adenocarcinoma of the bronchus
C	Squamous cell carcinoma of the bronchus
D	Organised lung abscess
E	Bronchial carcinoid

Explanation

E	Bronchial carcinoid

A solitary lesion with only occasional nuclear pleomorphism and absent or late mitoses fits with the biopsy picture of 'typical' bronchial carcinoid. Endobronchial lesions fit with this clinical picture of symptoms of obstruction and bouts of pneumonia. Patients with isolated lesions should be considered for resection. If the tumour shows atypical features or is close to the resection margin, then patients should be followed up with serial chest X-rays. Aggressive carcinoid may be managed with chemotherapy; symptoms of the carcinoid syndrome may be managed with octreotide, but by the time patients present with carcinoid syndrome, lesions are irresectable.

A	Small cell carcinoma of the bronchus

Small cell carcinoma is associated with marked nuclear pleomorphism and a large number of mitoses. Early metastasis is very common, and it is associated with exposure to tobacco smoke.

B	Adenocarcinoma of the bronchus

Adenocarcinoma presents with atypical cells showing frequent mitoses, often potentially forming ducts or glands.

C	Squamous cell carcinoma of the bronchus

Squamous cell carcinoma usually arises centrally, in larger bronchi, with metastases to hilar lymph nodes early in its development. It is strongly associated with cigarette smoking.

D	Organised lung abscess

Nuclear pleomorphism would not be expected in an organised lung abscess; white cell infiltration, particularly with neutrophils, would be a prominent feature.

32436

Rate this question:

Next Question

Previous Question | Tag Question

Feedback | End Session

Difficulty: Average

Peer Responses %

Session Progress

Responses Correct:	0
Responses Incorrect:	164
Responses Total:	164
Responses - % Correct:	0%

© Pastest 2017

A 35-year-old woman with a 15-year smoking history and a diagnosis of myasthenia gravis is referred by the neurologists for review. She has complained of progressive dyspnoea over the past few months. On examination her BP is 123/82, with pulse 67 and regular. You note she seems extremely fatigued, with obvious partial ptosis and proximal muscle weakness. The weakness increases with repetitive testing. Chest X-ray reveals a mediastinal mass and detailed pulmonary function testing reveals evidence of extrinsic obstruction.

Which of the following diagnoses is most likely given this clinical history?

A	Multinodular goitre
B	Thymoma
C	Schwannoma
D	Neurofibroma
E	Bronchial carcinoma

32437

Submit

Previous Question | Skip Question

Calculator

Normal Values

Blog About Pastest Contact Us Help

© Pastest 2017

A 35-year-old woman with a 15-year smoking history and a diagnosis of myasthenia gravis is referred by the neurologists for review. She has complained of progressive dyspnoea over the past few months. On examination her BP is 123/82, with pulse 67 and regular. You note she seems extremely fatigued, with obvious partial ptosis and proximal muscle weakness. The weakness increases with repetitive testing. Chest X-ray reveals a mediastinal mass and detailed pulmonary function testing reveals evidence of extrinsic obstruction.

Which of the following diagnoses is most likely given this clinical history?

A	Multinodular goitre
B	Thymoma
C	Schwannoma
D	Neurofibroma
E	Bronchial carcinoma

Explanation

B	Thymoma

Given the clinical history of myasthenia gravis and a mediastinal mass, thymoma represents the most likely diagnosis in this case (30–40% of thymoma cases have co-existent myasthenia gravis). Thymoma has equal sex distribution and rarely presents below the age of 20 years. Removal of the thymoma can significantly improve symptoms of myasthenia and is the next logical step once the diagnosis is confirmed in this patient.

A	Multinodular goitre

Multinodular goitre is associated with extrinsic airways obstruction, although it isn't associated with myasthenia gravis.

C	Schwannoma

Myasthenia gravis can be associated with multiple schwannomas, although these are not associated with extrinsic airways obstruction.

D	Neurofibroma

Superficial plexiform neurofibromas have been reported to occur in patients with myasthenia gravis, and this may occur because of inflammation around the neuromuscular junction.

E	Bronchial carcinoma

Bronchial carcinoma is associated with Lambert-Eaton myasthenic syndrome, which is associated with potentiation on repeated muscle testing rather than exacerbated weakness as seen here.

32437

Rate this question:

Next Question

Previous Question | Tag Question

Feedback | End Session

Difficulty: Average

Peer Responses %

Session Progress

Responses Correct:	0
Responses Incorrect:	165
Responses Total:	165
Responses - % Correct:	0%

© Pastest 2017

A 62-year-old male smoker of 30 cigarettes per day presents with symptoms of cough and dyspnoea accompanied by vague, non-specific chest pain. There is general malaise and joint pain which has been relieved by using prn diclofenac, and his cough has not been improved by a PRN salbutamol inhaler. Chest X-ray reveals bilateral enlarged hilar lymph nodes. There is a non-specific increase in immunoglobulins and raised serum angiotensin-converting enzyme (ACE).

Which of the following diagnoses fits best with this clinical picture?

A	Bronchial carcinoma
B	Sarcoidosis
C	Multiple myeloma
D	Lymphoma
E	Tuberculosis

32438

Submit

Previous Question | Skip Question

Calculator

Normal Values

© Pastest 2017

A 62-year-old male smoker of 30 cigarettes per day presents with symptoms of cough and dyspnoea accompanied by vague, non-specific chest pain. There is general malaise and joint pain which has been relieved by using prn diclofenac, and his cough has not been improved by a PRN salbutamol inhaler. Chest X-ray reveals bilateral enlarged hilar lymph nodes. There is a non-specific increase in immunoglobulins and raised serum angiotensin-converting enzyme (ACE).

Which of the following diagnoses fits best with this clinical picture?

A	Bronchial carcinoma
B	Sarcoidosis
C	Multiple myeloma
D	Lymphoma
E	Tuberculosis

Explanation

B	Sarcoidosis

More than 90% of patients with sarcoidosis have abnormal chest X-ray findings. Both immunoglobulins and serum angiotensin-converting enzyme (ACE) can be raised in active sarcoidosis. Renal function, liver function tests and serum calcium should also be assessed at initial appointment. High-resolution CT scanning may demonstrate micronodules in a subpleural and bronchioalveolar distribution, fissural nodularity and bronchial distortion. Irregular linear opacities and ground-glass shadowing may also be seen. Air trapping due to endobronchial granulomas and 'honeycombing' may also be seen. Kveim tests are no longer performed due to perceived danger of infection. If the CT scan is diagnostic, then mediastinoscopy, bronchoscopy or biopsies can often be avoided.

A	Bronchial carcinoma

Bronchial carcinoma is more usually associated with a unilateral mass as seen on CXR with lymph node spread to the ipsilateral side.

C	Multiple myeloma

Multiple myeloma is associated with the appearance of a paraprotein band on immunoglobulin testing rather than the non-specific increases seen here.

D	Lymphoma

Lymphoma is associated with hilar lymphadenopathy, although the dry cough and elevated serum ACE are more consistent with a diagnosis of sarcoidosis.

E	Tuberculosis

Tuberculosis is less likely given the hilar lymphadenopathy is bilateral, and no risk factors for TB are proffered in the clinical scenario.

32438

Rate this question:

Next Question

Previous Question | Tag Question

Feedback | End Session

Difficulty: Average

Peer Responses %

Session Progress

Responses Correct:	0
Responses Incorrect:	166
Responses Total:	166
Responses - % Correct:	0%

© Pastest 2017

A 32-year-old woman with a history of intravenous drug abuse attends for review. She has a history of gradually increasing shortness of breath over the past 18 months to 2 years. There has been associated intermittent fevers and weight loss of some 5 kg. She has tested negative for hepatitis B some 6 months earlier. On examination there are lower zone inspiratory crackles.

Investigations reveal haemoglobin (Hb) of 9.2 g/dl and a diffuse increase in immunoglobulins, renal function testing is normal. Chest X-ray reveals diffuse lower zone alveolar shadowing. Lung biopsy reveals diffuse interstitial lymphoid infiltrates and pulmonary function tests suggest a restrictive lung defect.

Which of the following diagnoses fits best with this clinical picture?

A	Lymphoid interstitial pneumonia
B	Idiopathic pulmonary fibrosis
C	Viral pneumonia
D	Hypersensitivity pneumonitis
E	Respiratory bronchiolitis-associated interstitial lung disease

32439

Submit

Previous Question Skip Question

Calculator

Normal Values

Blog About Pastest Contact Us Help

© Pastest 2017

A 32-year-old woman with a history of intravenous drug abuse attends for review. She has a history of gradually increasing shortness of breath over the past 18 months to 2 years. There has been associated intermittent fevers and weight loss of some 5 kg. She has tested negative for hepatitis B some 6 months earlier. On examination there are lower zone inspiratory crackles.

Investigations reveal haemoglobin (Hb) of 9.2 g/dl and a diffuse increase in immunoglobulins, renal function testing is normal. Chest X-ray reveals diffuse lower zone alveolar shadowing. Lung biopsy reveals diffuse interstitial lymphoid infiltrates and pulmonary function tests suggest a restrictive lung defect.

Which of the following diagnoses fits best with this clinical picture?

A	Lymphoid interstitial pneumonia
B	Idiopathic pulmonary fibrosis
C	Viral pneumonia
D	Hypersensitivity pneumonitis
E	Respiratory bronchiolitis-associated interstitial lung disease

Explanation

A	Lymphoid interstitial pneumonia

Clinical features of lymphoid interstitial pneumonia include gradual-onset breathlessness over a considerable time, intermittent fevers and weight loss, with inspiratory crackles on examination. There is mild anaemia with a diffuse increase in immunoglobulins. Chest X-ray features include lower zone shadowing, and histology reveals lymphoid interstitial infiltrates. Steroids may improve symptoms, although around one-third of patients progress to extensive fibrosis. Associations include HIV, connective tissue disease, hepatitis B infection, chronic active hepatitis and Hashimoto's thyroiditis.

B	Idiopathic pulmonary fibrosis

Idiopathic pulmonary fibrosis implies there is no identified underlying cause; against a background of IV drug abuse, secondary interstitial lung disease should be excluded before describing the changes seen here as idiopathic.

C	Viral pneumonia

Given the chronic nature of this patient's symptoms, viral pneumonia is very unlikely to be responsible.

D	Hypersensitivity pneumonitis

Although hypersensitivity pneumonitis may be seen, particularly against a background of cocaine smoking, it is stated that this patient's mode of drug abuse is primarily intravenous.

E	Respiratory bronchiolitis-associated interstitial lung disease

RBALD is primarily associated with heavy smoking and presents with pigment-loaded macrophages in the pulmonary infiltrates rather than the lymphocytes seen here.

32439

Rate this question:

Next Question

Previous Question | Tag Question

Feedback | End Session

Difficulty: Average

Peer Responses %

Session Progress

Responses Correct:	0
Responses Incorrect:	167
Responses Total:	167
Responses - % Correct:	0%

© Pastest 2017

A 54-year-old farmer's wife with a history of rheumatoid arthritis presents to the clinic with increasing shortness of breath, cough and intermittent pleuritic chest pain. Previous agents have included corticosteroids and hydroxychloroquine, and she has commenced methotrexate, with appropriate folic acid replacement 2 years ago. On examination her BP is 135/85, with pulse 73 and regular. She has scattered crackles throughout both lung fields on auscultation, and there is no pitting oedema of the ankles. Lung function tests reveal a restrictive lung defect and chest X-ray reveals pulmonary infiltrates. Lung function tests were normal some 4 years ago.

What diagnosis fits best with this clinical picture?

A	Extrinsic allergic alveolitis
B	Methotrexate-related lung toxicity
C	Hydroxychloroquine-related lung toxicity
D	Obliterative bronchiolitis
E	Idiopathic pulmonary fibrosis

32440

Submit

Previous Question | Skip Question

Calculator

Normal Values

Blog About Pastest Contact Us Help

© Pastest 2017

A 54-year-old farmer's wife with a history of rheumatoid arthritis presents to the clinic with increasing shortness of breath, cough and intermittent pleuritic chest pain. Previous agents have included corticosteroids and hydroxychloroquine, and she has commenced methotrexate, with appropriate folic acid replacement 2 years ago. On examination her BP is 135/85, with pulse 73 and regular. She has scattered crackles throughout both lung fields on auscultation, and there is no pitting oedema of the ankles. Lung function tests reveal a restrictive lung defect and chest X-ray reveals pulmonary infiltrates. Lung function tests were normal some 4 years ago.

What diagnosis fits best with this clinical picture?

A	Extrinsic allergic alveolitis
B	Methotrexate-related lung toxicity
C	Hydroxychloroquine-related lung toxicity
D	Obliterative bronchiolitis
E	Idiopathic pulmonary fibrosis

Explanation

B	Methotrexate-related lung toxicity

In this case the time course of lung disease (commencement of methotrexate 2 years ago, against a background of normal lung function 4 years ago) helps to point to methotrexate-related lung toxicity as the most likely cause of her symptoms. A spectrum of disease may occur with methotrexate toxicity, from interstitial pneumonitis to cough, pleuritic chest pain and shortness of breath related to subacute lung infiltration, associated with bilateral pleural effusions. Histology may demonstrate alveolitis, pneumonitis, epithelial cell hyperplasia, eosinophil infiltration and granuloma formation, and is more useful than when investigating other drug toxicities. Treatment is methotrexate withdrawal - in this case substitution with an anti-TNF or anti-CD20 antibody would be the next most logical step.

A	Extrinsic allergic alveolitis

We are given no information as to possible antigenic triggers, and EAA often presents with an obstructive lung function defect with an asthma pattern of symptoms.

C	Hydroxychloroquine-related lung toxicity

Hydroxychloroquine toxicity primarily involves the eye, leading to retinal damage which may be permanent, and to deposition of the drug within the cornea.

D	Obliterative bronchiolitis

Obliterative bronchiolitis is characterised by fixed airways obstruction, rather than the restrictive lung defect seen here.

E	Idiopathic pulmonary fibrosis

The fact that lung function was normal 4 years ago anchors the defect seen here to the initiation of methotrexate, making this for more likely to be the cause of the restrictive lung defect seen.

32440

Rate this question:

Next Question

Previous Question | Tag Question

Feedback | End Session

Difficulty: Average

Peer Responses %

Session Progress

Responses Correct:	0
Responses Incorrect:	168
Responses Total:	168
Responses - % Correct:	0%

© Pastest 2017

You review a 67-year-old man with severe chronic obstructive pulmonary disease (COPD) who stopped smoking 3 years ago. He has a history of myocardial infarction 4 years ago and chronic peripheral vascular disease. His medications include ramipril, indapamide, salbutamol and ipratropium.

Which of the following clinical features would best support prescription of long-term oxygen therapy (LTOT)?

A	$Pa(O_2)$ of 8.2 kPa
B	Pitting oedema of the lower limbs
C	$Pa(CO_2)$ of 5.1 kPa
D	FEV_1 (forced expiratory volume in 1 s) of 1.7 l
E	History of angina

32441

Submit

Previous Question | Skip Question

Calculator

Normal Values

© Pastest 2017

You review a 67-year-old man with severe chronic obstructive pulmonary disease (COPD) who stopped smoking 3 years ago. He has a history of myocardial infarction 4 years ago and chronic peripheral vascular disease. His medications include ramipril, indapamide, salbutamol and ipratropium.

Which of the following clinical features would best support prescription of long-term oxygen therapy (LTOT)?

A	$Pa(O_2)$ of 8.2 kPa
B	Pitting oedema of the lower limbs
C	$Pa(CO_2)$ of 5.1 kPa
D	FEV_1 (forced expiratory volume in 1 s) of 1.7 l
E	History of angina

Explanation

B	Pitting oedema of the lower limbs

According the British Thoracic Society guidelines on long-term oxygen therapy (LTOT) in regard to patients with stable chronic obstructive pulmonary disease (COPD) (see weblink below), a resting $Pa(O_2) \leqslant 7.3$ kPa should be assessed for LTOT, which offers survival benefit when used for at least 15 h per day and improves pulmonary haemodynamics. LTOT should be offered to those patients with stable COPD and a resting $Pa(O_2) \leqslant 8$ kPa with evidence of peripheral oedema, polycythaemia (haematocrit $\geqslant 55\%$) or pulmonary hypertension. Swollen ankles indicate the possibility of right heart failure, which may be occurring as a result of pulmonary hypertension which is in keeping with the guidelines above.

Two measures are required to make the decision on therapy, and samples should be taken at least 3 weeks apart whilst the patient is stable and free of an exacerbation. This leads to a reduction in secondary polycythaemia, reduced sympathetic outflow and consequent salt and water retention, a reduction in cardiac arrhythmias, and improved sleep quality due to reduced hypoxia-induced sleep arousals.

A	$Pa(O_2)$ of 8.2 kPa

$Pa(O_2)$ >8kPa should not lead to a prescription of LTOT.

C	$Pa(CO_2)$ of 5.1 kPa

Although LTOT should be ordered for patients with resting hypercapnia (if they fulfil all other criteria for LTOT), this gentleman does not have resting hypercapnia.

D	FEV_1 (forced expiratory volume in 1 s) of 1.7 l

Spirometry findings do warrant criteria for oxygen therapy and do not indicate hypoxia.

E	History of angina

Although it can be used in chronic heart failure, history of angina is not an appropriate use of LTOT. Anti-anginal medication or a coronary angiogram would be required if patient has recurrent episodes of angina.

32441

Rate this question:

Next Question

Previous Question | Tag Question

Feedback | End Session

Difficulty: Average

Peer Responses %

Session Progress

Responses Correct:	0
Responses Incorrect:	169
Responses Total:	169
Responses - % Correct:	0%

External Links

BTS Guidelines for Home - Oxygen Use in Adults
brit-thoracic.org.uk/document-library/clinical-information/oxygen/home-oxygen-gui...

© Pastest 2017

A 54-year-old man with chronic obstructive pulmonary disease (COPD) attends for smoking cessation advice.

Which of the following methods is likely to be associated with the greatest chance of quitting?

A	Bupropion
B	Nicotine replacement lozenges
C	Willpower
D	Nicotine replacement gum
E	Hypnosis

32442

Submit

Previous Question Skip Question

Calculator

Normal Values

© Pastest 2017

A 54-year-old man with chronic obstructive pulmonary disease (COPD) attends for smoking cessation advice.

Which of the following methods is likely to be associated with the greatest chance of quitting?

A	Bupropion
B	Nicotine replacement lozenges
C	Willpower
D	Nicotine replacement gum
E	Hypnosis

Explanation

A	Bupropion

Studies have shown success in smoking cessation in 20–30% of patients involved in bupropion studies at 1 year, with marginally higher quit rates seen when bupropion and nicotine replacement were combined (35%). Studies have shown that varenicline also aids smoking cessation in combination with motivational support, resulting in higher quit rates when higher doses were used (44% success rate).

B	Nicotine replacement lozenges

Nicotine replacement is associated with a quit rate of only around 10% in clinical trials.

C	Willpower

Willpower quit rates are thought to be around only 2–4% at 1 year in reality.

D	Nicotine replacement gum

Like option B, nicotine replacement is associated with a quit rate of only around 10% in clinical trials.

E	Hypnosis

Hypnosis aims to improve willpower in the subconscious state, and trials have showed no greater abstinence rate.

32442

Rate this question:

Next Question

Previous Question | Tag Question

Feedback | End Session

Difficulty: Average

Peer Responses %

Session Progress

Responses Correct:	0
Responses Incorrect:	170
Responses Total:	170
Responses - % Correct:	0%

© Pastest 2017

A 67-year-old man presents with bilateral motor and sensory weakness of his lower limbs associated with urinary incontinence and constipation. Over the past few months he has suffered chronic back pain. Past history involves asthma, smoking of 30 pack years and chronic depression. Medication history includes amitriptyline and salbutamol. On examination he was unable to move off the trolley, his BP is 142/82 mmHg, with pulse 80/min and regular. There is a palpable bladder, a sensory level at T10 and bilateral lower limb power weakness.

Investigations:

Hb	12.6 g/dl
WCC	5.0×10^9/l
PLT	160×10^9/l
Ca^{2+}	2.9 mmol/l
ALT	145 U/l
ALP	352 U/l
GGT	50 U/l
Bilirubin	25 µmol/l
Albumin	30 g/l
MCV	80 fl

Which of the following is the investigation of choice in this case?

A	Magnetic resonance imaging (MRI) scan of the spine
B	Computed tomography (CT) scan of the spine
C	Plain X-ray of the spine
D	Bone scan of the spine
E	Skeletal survey

32443

Submit

Previous Question | Skip Question

Calculator

Normal Values

© Pastest 2017

A 67-year-old man presents with bilateral motor and sensory weakness of his lower limbs associated with urinary incontinence and constipation. Over the past few months he has suffered chronic back pain. Past history involves asthma, smoking of 30 pack years and chronic depression. Medication history includes amitriptyline and salbutamol. On examination he was unable to move off the trolley, his BP is 142/82 mmHg, with pulse 80/min and regular. There is a palpable bladder, a sensory level at T10 and bilateral lower limb power weakness.

Investigations:

Hb	12.6 g/dl
WCC	5.0×10^9/l
PLT	160×10^9/l
Ca^{2+}	2.9 mmol/l
ALT	145 U/l
ALP	352 U/l
GGT	50 U/l
Bilirubin	25 µmol/l
Albumin	30 g/l
MCV	80 fl

Which of the following is the investigation of choice in this case?

A	Magnetic resonance imaging (MRI) scan of the spine
B	Computed tomography (CT) scan of the spine
C	Plain X-ray of the spine
D	Bone scan of the spine
E	Skeletal survey

Explanation

A	Magnetic resonance imaging (MRI) scan of the spine

Symptoms and signs are consistent with spinal cord compression, and MRI scanning is useful to demonstrate the level of compression. It also provides valuable information as to the nature of the lesion leading to compression, and hence potential therapeutic options.

B	Computed tomography (CT) scan of the spine

This is less reliable than MRI but can be used if the latter is unavailable.

C	Plain X-ray of the spine

Although it will show evidence of metastases (smoking, raised calcium and ALP with possible bronchial carcinoma as primary), it will not show the degree of spinal cord compression.

D	Bone scan of the spine

Like plain X-ray, it will show metastases but not spinal cord compression.

E	Skeletal survey

This will not show spinal cord involvement, which is the investigation required to determine level of compression in keeping with the symptoms and signs that gentleman presents with. Skeletal survey is useful in conditions such as multiple myeloma, metastatic bone disease or Paget's disease.

32443

Rate this question:

Next Question

Previous Question | Tag Question

Feedback | End Session

Difficulty: Average

Peer Responses %

Session Progress

Responses Correct:	0
Responses Incorrect:	171
Responses Total:	171
Responses - % Correct:	0%

© Pastest 2017

A 48-year-old builder working in the UK for over 5 years presents to your clinic with a 1-year history of wheeze and cough that is worse in the early hours of the morning. On direct questioning he admits to mild haemoptysis over the past few days with no increase or change in his sputum production, occasional mild night sweats and he has noticed a slight weight loss over the past few months due to decreased appetite. His past medical history includes previous alcohol excess and type 2 diabetes. A chest X-ray taken two years ago showed clear lung fields and no signs of previous lung pathology.

Which of the following pathologies is the most likely cause of his haemoptysis?

A	Aspergilloma
B	Allergic bronchopulmonary aspergillosis (ABPA)
C	Semi-invasive aspergillosis
D	Invasive aspergillosis
E	Asthma exacerbation

32444

Submit

Previous Question | Skip Question

Calculator

Normal Values

© Pastest 2017

A 48-year-old builder working in the UK for over 5 years presents to your clinic with a 1-year history of wheeze and cough that is worse in the early hours of the morning. On direct questioning he admits to mild haemoptysis over the past few days with no increase or change in his sputum production, occasional mild night sweats and he has noticed a slight weight loss over the past few months due to decreased appetite. His past medical history includes previous alcohol excess and type 2 diabetes. A chest X-ray taken two years ago showed clear lung fields and no signs of previous lung pathology.

Which of the following pathologies is the most likely cause of his haemoptysis?

A	Aspergilloma
B	Allergic bronchopulmonary aspergillosis (ABPA)
C	Semi-invasive aspergillosis
D	Invasive aspergillosis
E	Asthma exacerbation

Explanation

C Semi-invasive aspergillosis

This is a chronic indolent disease that affects people with mild immunosuppression, such as those with diabetes or chronic obstructive pulmonary disease or those who abuse alcohol, are elderly or on prolonged steroid use. If left untreated there is a significant associated mortality; however, it is difficult to diagnose due to its slow progression both radiologically and clinically. Symptoms include cough, wheeze, bronchitis and constitutional symptoms, and about 15% present with haemoptysis.

A Aspergilloma

This is a ball of fungus within a pre-existing cavity such as that caused by tuberculosis (TB). With a recent clear chest X-ray (2 years ago), this patient is unlikely to have any cavities in which an aspergilloma could reside. Furthermore, aspergillomas are usually asymptomatic but can cause weight loss, cough and haemoptysis, which can be massive and require emergency surgical excision. Oral antifungals can be given, but with limited success.

B Allergic bronchopulmonary aspergillosis (ABPA)

This is an IgE and IgG reaction to *Aspergillus* sp. in asthmatics. The key criteria for diagnosis include a long history of asthma, skin-prick/IgE, positive/IgG precipitins to *Aspergillus* fumigates, central bronchiectasis, elevated total serum IgE, blood/sputum eosinophilia and pulmonary infiltrates.

D Invasive aspergillosis

This patient is not acutely unwell. This condition occurs in immunosuppressed individuals and is caused by haematogenous spread of the fungus, so prompt diagnosis and treatment are required to prevent a high mortality rate.

E Asthma exacerbation

Night sweats and haemoptysis are not features of asthma exacerbation.

32444

Rate this question:

Next Question

Previous Question | Tag Question

Feedback | End Session

Difficulty: Difficult

Peer Responses %

Session Progress

Responses Correct:	0
Responses Incorrect:	172
Responses Total:	172
Responses - % Correct:	0%

© Pastest 2017

A 50-year-old housewife is being followed up in the chest clinic for her asthma. Over the past 2 years she has had intermittent low-grade fevers, weight loss, cough and shortness of breath. On examination she has end-expiratory wheeze with occasional crackles that do not resolve on coughing. She does not have any clubbing. She is a non-smoker. Her past medical history includes asthma and atrial fibrillation. Her drug history includes salbutamol inhaler, high-dose steroid inhaler and amiodarone. Her chest X-ray shows peripheral infiltrates on the outer two-thirds of the peripheries. Her sputum microbiology is negative but she has a raised number of eosinophils. Her blood tests show a raised serum eosinophil count, IgG and ESR.

Which of the following is the most likely diagnosis?

A	Amiodarone-induced fibrosis
B	Chronic eosinophilic pneumonia (CEP)
C	Allergic bronchopulmonary aspergillosis (ABPA)
D	Treatment-resistant asthma
E	Acute eosinophilic pneumonia (AEP)

32445

Submit

Previous Question | Skip Question

Calculator

Normal Values

© Pastest 2017

A 50-year-old housewife is being followed up in the chest clinic for her asthma. Over the past 2 years she has had intermittent low-grade fevers, weight loss, cough and shortness of breath. On examination she has end-expiratory wheeze with occasional crackles that do not resolve on coughing. She does not have any clubbing. She is a non-smoker. Her past medical history includes asthma and atrial fibrillation. Her drug history includes salbutamol inhaler, high-dose steroid inhaler and amiodarone. Her chest X-ray shows peripheral infiltrates on the outer two-thirds of the peripheries. Her sputum microbiology is negative but she has a raised number of eosinophils. Her blood tests show a raised serum eosinophil count, IgG and ESR.

Which of the following is the most likely diagnosis?

A	Amiodarone-induced fibrosis
B	Chronic eosinophilic pneumonia (CEP)
C	Allergic bronchopulmonary aspergillosis (ABPA)
D	Treatment-resistant asthma
E	Acute eosinophilic pneumonia (AEP)

Explanation

B Chronic eosinophilic pneumonia (CEP)

Eosinophilic pneumonia is a rare respiratory pathology characterised by pulmonary infiltrates and pulmonary eosinophilia. It can be idiopathic or secondary to parasites, drugs or systemic diseases such as vasculitis. The peripheral eosinophil count is not always raised. The serum IgG is raised in two-thirds and the ESR is elevated. Sputum and bronchoalveolar lavage often show an eosinophilia.

This presents over months to years. CEP usually occurs in those aged in their 50s, with a female:male ratio of 2:1. It can be irreversible. About 60% of patients with CEP have asthma and 90% are non-smokers. Patients present with constitutional symptoms, cough, wheeze and fever. Chest X-ray in CEP shows dense, bilateral peripheral infiltrates often 'opposite to pulmonary oedema' with a distribution in the outer two-thirds of the lung. Treatment is with steroids.

A Amiodarone-induced fibrosis

In this condition, changes are usually seen in the bases. The treatment is to stop the drug, and steroids may help.

C Allergic bronchopulmonary aspergillosis (ABPA)

There would be an elevated total serum IgE rather than IgG and IgG precipitins to *Aspergillus fumigatus*.

D Treatment-resistant asthma

Asthma does not present with intermittent low-grade fevers, and CXR would be normal rather than show pulmonary infiltrates.

E Acute eosinophilic pneumonia (AEP)

This presents over a few days. Patients with AEP are acutely unwell with temperature, tachycardia and tachypnoea. AEP chest X-ray may show bilateral diffuse infiltrates associated with an effusion.

32445

Rate this question:

Next Question

Previous Question | Tag Question

Feedback | End Session

Difficulty: Average

Peer Responses %

Session Progress

Responses Correct:	0
Responses Incorrect:	173
Responses Total:	173
Responses - % Correct:	0%

© Pastest 2017

A 35-year-old, HIV-positive, East African patient presents to A&E with shortness of breath and night sweats. On examination he is thin and tachypnoeic, and has a right base that is stony dull to percussion with reduced air entry. On his chest X-ray there is a moderate-sized pleural effusion. His past medical history includes tuberculosis (TB) as a child for which he can't remember whether he had treatment. His initial three sputum samples do not stain for acid-fast bacilli on Ziehl–Neelsen (ZN) stain. You want to carry out a test with the highest pick-up rate for TB diagnosis.

Which of the following would be the most useful?

A	Pleural fluid aspirate culture
B	Pleural biopsy culture
C	Pleural biopsy histology
D	CD4 count
E	Heaf test

32446

Submit

Previous Question | Skip Question

Calculator

Normal Values

© Pastest 2017

A 35-year-old, HIV-positive, East African patient presents to A&E with shortness of breath and night sweats. On examination he is thin and tachypnoeic, and has a right base that is stony dull to percussion with reduced air entry. On his chest X-ray there is a moderate-sized pleural effusion. His past medical history includes tuberculosis (TB) as a child for which he can't remember whether he had treatment. His initial three sputum samples do not stain for acid-fast bacilli on Ziehl–Neelsen (ZN) stain. You want to carry out a test with the highest pick-up rate for TB diagnosis.

Which of the following would be the most useful?

A	Pleural fluid aspirate culture
B	Pleural biopsy culture
C	Pleural biopsy histology
D	CD4 count
E	Heaf test

Explanation

B	Pleural biopsy culture

Tuberculous effusion occurs in about 30% of patients with TB; this is comparable to HIV-positive and -negative patients. ZN stains are positive in about 75% of cases. Indications for pleural biopsy are exudative recurrent pleural effusion of unknown aetiology and pleural mass or thickening.

A	Pleural fluid aspirate culture

ZN stains of pleural fluid are positive in 10–20% of tuberculous effusions.

C	Pleural biopsy histology

Although it may demonstrate granulomas, it cannot give bacterial sensitivities.

D	CD4 count

A low CD4 count not only predisposes to TB. CD4 cell counts give an indication of the health of the immune system. Monitoring CD4 cell counts is less important while taking HIV treatment than before starting. The count should go up when you take HIV treatment. Patients with higher CD4 counts present similar to those who are HIV-negative with TB.

E	Heaf test

This test has been discontinued since 2005 and has been replaced by the Mantoux test – a person's medical risk factors determine at which increment (5, 10 or 15 mm) of induration the result is considered positive. Other techniques used include bronchoscopy/endobronchial ultrasound in those who have a non-productive cough/ unhelpful sputum culture and a high index of clinical suspicion.

Adenosine deaminase (ADA) levels are useful when TB is suspected in those with negative pleural fluid or biopsy cultures. However, raised ADA levels can be observed in other conditions leading to a false-positive diagnosis of TB, such as in empyema, rheumatoid effusion and malignancy.

32446

Rate this question:

Next Question

Previous Question | Tag Question

Feedback | End Session

Difficulty: Average

Peer Responses %

Session Progress

Responses Correct:	0
Responses Incorrect:	174
Responses Total:	174
Responses - % Correct:	0%

© Pastest 2017

A 40-year-old farmer presents with a 1-month history of wheeze and shortness of breath associated with working on the farm and resolving about 6 h after stopping work. On examination his BP is 136/82 mmHg, pulse is 82/min and regular and oxygen saturation is 94% on air. He has coarse inspiratory crackles and a dry cough. You suspect he is suffering from extrinsic allergic alveolitis.

Which feature is most likely to be seen on his chest X-ray?

A	Bilateral hilar lymphadenopathy
B	Lower zone nodular pattern of fibrosis
C	Upper zone nodular pattern of fibrosis
D	Pleural thickening
E	Honeycomb pattern in the upper zones

32447

Submit

Previous Question Skip Question

Calculator

Normal Values

Blog About Pastest Contact Us Help

© Pastest 2017

A 40-year-old farmer presents with a 1-month history of wheeze and shortness of breath associated with working on the farm and resolving about 6 h after stopping work. On examination his BP is 136/82 mmHg, pulse is 82/min and regular and oxygen saturation is 94% on air. He has coarse inspiratory crackles and a dry cough. You suspect he is suffering from extrinsic allergic alveolitis.

Which feature is most likely to be seen on his chest X-ray?

A	Bilateral hilar lymphadenopathy
B	Lower zone nodular pattern of fibrosis
C	Upper zone nodular pattern of fibrosis
D	Pleural thickening
E	Honeycomb pattern in the upper zones

Explanation

C	Upper zone nodular pattern of fibrosis

Extrinsic allergic alveolitis usually has a nodular pattern bilaterally, with a predilection for the upper lobes. An upper lobe fibrosis pattern is common in the conditions described by the mnemonic BREASTS CLAP.

A	Bilateral hilar lymphadenopathy

This is rarely seen in extrinsic allergic alveolitis. It is more commonly associated with sarcoidosis, malignancy (lymphoma and carcinoma) and infection (tuberculosis, mycoplasma and silicosis).

B	Lower zone nodular pattern of fibrosis

Extrinsic allergic alveolitis affects the upper lobes. Lower zone fibrosis usually occurs in those with asbestosis, rheumatoid arthritis or connective tissue diseases, or as a side effect of certain drugs (busulphan, bleomycin, nitrofurantoin, methotrexate, amiodarone).

D	Pleural thickening

This is a non-specific feature that can occur with both benign (such as occupational – asbestos exposure) and malignant pleural disease (mesothelioma, pleural metastases) rather than extrinsic allergic alveolitis.

E	Honeycomb pattern in the upper zones

This is usually a manifestation of end-stage interstitial fibrosis. This gentleman has a short presentation history and saturating 94% on air, making honeycomb pattern on radiology unlikely. Honeycombing occurs due to the airspaces consisting of irregular, thickened fibrotic walls and inflammatory cells.

Useful mnemonic:

BREASTS CLAP+ for upper lobe fibrosis pattern

32447

Rate this question:

Next Question

Previous Question | Tag Question

Feedback | End Session

Difficulty: Average

Peer Responses %

Session Progress

Responses Correct:	0
Responses Incorrect:	175
Responses Total:	175
Responses - % Correct:	0%

© Pastest 2017

A 40-year-old nurse is admitted to the Medical Unit with a 2-day history of wheeze and exacerbation of asthma during peak pollen season. She has had this diagnosis for four years, since moving from her home in West Africa to the UK. She also has a history of hay fever since moving to the UK, and her daughter has developed asthma too. She has no other past medical history and is a non-smoker.

Investigations:

Hb	13.5 g/dl
WCC	10×10^9/l
Eosinophils	1.5×10^9/l
PLT	350×10^9/l

Her lung fields on the chest X-ray show minor patchy shadowing.

Which additional test would you opt to do to best exclude causes, other than asthma, of her wheeze and current exacerbation?

A	Antinuclear antibody (ANA)
B	IgE
C	*Aspergillus*-specific IgE radioallergosorbant (RAST) level
D	Peak flow reading
E	Stool culture for ova, cysts and parasites

32448

Submit

Previous Question | Skip Question

Calculator

Normal Values

© Pastest 2017

A 40-year-old nurse is admitted to the Medical Unit with a 2-day history of wheeze and exacerbation of asthma during peak pollen season. She has had this diagnosis for four years, since moving from her home in West Africa to the UK. She also has a history of hay fever since moving to the UK, and her daughter has developed asthma too. She has no other past medical history and is a non-smoker.

Investigations:

Hb	13.5 g/dl
WCC	10×10^9/l
Eosinophils	1.5×10^9/l
PLT	350×10^9/l

Her lung fields on the chest X-ray show minor patchy shadowing.

Which additional test would you opt to do to best exclude causes other than asthma, of her wheeze and current exacerbation?

A	Antinuclear antibody (ANA)
B	IgE
C	*Aspergillus*-specific IgE radioallergosorbant (RAST) level
D	Peak flow reading
E	Stool culture for ova, cysts and parasites

Explanation

C	*Aspergillus*-specific IgE radioallergosorbant (RAST) level

Allergic bronchopulmonary aspergillosis (ABPA) should always be excluded in people with asthma who have a raised eosinophil count. ABPA is a hypersensitivity reaction to *Aspergillus* in people with asthma. This can be done by sputum culture or testing for atopy to the fungi with RAST, skin-prick tests or IgE specific to the fungi. *Aspergillus* precipitins testing looks for the presence of the antibody in the serum; if the result is highly positive, the patient may have invasive aspergillosis.

A	Antinuclear antibody (ANA)

Although eosinophil count can also be raised in Churg–Strauss syndrome, a small-to-medium-vessel vasculitis that presents usually in adults with asthma-like symptoms, this results in a positive pANCA, not ANA.

B	IgE

A high eosinophil count may be due to her atopy and the high pollen count, so her total IgE would also be raised.

D	Peak flow reading

Peak flow readings will likely be low in respiratory diseases like asthma, ABPA and Churg–Strauss, and therefore not good at excluding causes of wheeze and exacerbation.

E	Stool culture for ova, cysts and parasites

Stool culture may be positive in a parasitic cause of eosinophilia pneumonia, but this is unlikely given the very minor chest X-ray changes.

32448

Rate this question:

Next Question

Previous Question | Tag Question

Feedback | End Session

Difficulty: Average

Peer Responses %

Session Progress

Responses Correct:	0
Responses Incorrect:	176
Responses Total:	176
Responses - % Correct:	0%

© Pastest 2017

You review a 35-year-old woman who is overweight, with a body mass index (BMI) of 31. She presents with increasing lethargy and shortness of breath over the past few weeks. She has a past history of deep vein thrombosis three years ago. Electrocardiogram (ECG) reveals evidence of right ventricular hypertrophy. Her BP is 145/82 mmHg, with pulse 92/min and regular. Saturations are 91% on air and fall on only minor exercise. D-dimers are above the upper limit of normal.

Which of the following diagnoses fits best with this clinical picture?

A	Right heart failure
B	Sleep apnoea syndrome
C	Single massive pulmonary embolus
D	Multiple pulmonary emboli
E	Cardiomyopathy

32449

Submit

Previous Question | Skip Question

Calculator

Normal Values

© Pastest 2017

You review a 35-year-old woman who is overweight, with a body mass index (BMI) of 31. She presents with increasing lethargy and shortness of breath over the past few weeks. She has a past history of deep vein thrombosis three years ago. Electrocardiogram (ECG) reveals evidence of right ventricular hypertrophy. Her BP is 145/82 mmHg, with pulse 92/min and regular. Saturations are 91% on air and fall on only minor exercise. D-dimers are above the upper limit of normal.

Which of the following diagnoses fits best with this clinical picture?

A	Right heart failure
B	Sleep apnoea syndrome
C	Single massive pulmonary embolus
D	Multiple pulmonary emboli
E	Cardiomyopathy

Explanation

D	Multiple pulmonary emboli

Right ventricular hypertrophy and the previous history of deep venous thrombosis point towards a diagnosis of multiple pulmonary emboli; raised D-dimers also support the diagnosis of thromboembolic disease. Lifelong warfarinisation is the treatment of choice. If further pulmonary emboli occur, then the patient should be considered for insertion of an inferior vena cava (IVC) filter.

A	Right heart failure

There is no evidence of right heart failure symptoms, such as elevated JVP, peripheral oedema or ascites.

B	Sleep apnoea syndrome

Although this patient is overweight (a risk factor for sleep apnoea), she does not have the features suggestive of sleep apnoea such as sleepiness and snoring.

C	Single massive pulmonary embolus

There is no evidence of circulatory collapse – this patient does not have a low systolic blood pressure drop to suggest a massive pulmonary embolus.

E	Cardiomyopathy

Unless this patient has arrhythmogenic right cardiomyopathy (a rare genetic condition), right ventricular hypertrophy on ECG does not fit with this picture.

32449

Rate this question:

Next Question

Previous Question | Tag Question

Feedback | End Session

Difficulty: Average

Peer Responses %

Session Progress

Responses Correct:	0
Responses Incorrect:	177
Responses Total:	177
Responses - % Correct:	0%

© Pastest 2017

You are asked to review a 34-year-old woman with progressively worsening shortness of breath. She has worked in a printing works for some years and smokes 5–8 cigarettes per day. She complains of intermittent fever and cough. On examination her BP is 122/82 mmHg, with pulse 80/min and regular. There are coarse crackles and sparse wheeze on auscultation of the chest. On further questioning you understand that her GP has given her beclomethasone and salbutamol, with no significant improvement.

Lung function tests reveal:

Forced expiratory volume (FEV)	Decreased
Forced vital capacity (FVC)	Decreased
FEV in 1 s (FEV_1)/FVC	Decreased to 62% (predicted 75%)
Carbon monoxide gas transfer	Reduced

Which of the following diagnoses fits best with this clinical picture?

A	Extrinsic allergic alveolitis
B	Idiopathic pulmonary fibrosis
C	Chronic obstructive pulmonary disease (COPD)
D	Asthma
E	Bronchiectasis

32450

Submit

Previous Question | Skip Question

Calculator

Normal Values

© Pastest 2017

You are asked to review a 34-year-old woman with progressively worsening shortness of breath. She has worked in a printing works for some years and smokes 5–8 cigarettes per day. She complains of intermittent fever and cough. On examination her BP is 122/82 mmHg, with pulse 80/min and regular. There are coarse crackles and sparse wheeze on auscultation of the chest. On further questioning you understand that her GP has given her beclomethasone and salbutamol, with no significant improvement.

Lung function tests reveal:

Forced expiratory volume (FEV)	Decreased
Forced vital capacity (FVC)	Decreased
FEV in 1 s (FEV_1)/FVC	Decreased to 62% (predicted 75%)
Carbon monoxide gas transfer	Reduced

Which of the following diagnoses fits best with this clinical picture?

A Extrinsic allergic alveolitis

B Idiopathic pulmonary fibrosis

C Chronic obstructive pulmonary disease (COPD)

D Asthma

E Bronchiectasis

Explanation

A Extrinsic allergic alveolitis

There is reduced transfer factor with restrictive and obstructive pattern, and reduced lung volume. High-dose oral prednisolone may be used to achieve regression during the early stages of the disease.

Interpretation of lung function tests: obstructive – (FEV_1)/FVC decreased, FVC normal; restrictive – (FEV_1)/FVC normal, FVC decreased; mixed pattern – (FEV_1)/FVC decreased, FVC decreased.

This woman may be suffering from so called 'humidifier fever', which occurs as a result of exposure to contaminated humidifying systems in air conditioners/ large-scale factory humidifiers such as those found in printing works. The condition is associated with a mixed obstructive and restrictive picture, as seen when these lung function tests are reviewed.

B Idiopathic pulmonary fibrosis

This typically presents with reduced FVC and transfer factor.

C Chronic obstructive pulmonary disease (COPD)

This is an obstructive picture and unlikely to present at an early age unless alpha-1-antitrypsin deficiency is present.

D Asthma

Asthma would not show reduced gas transfer.

E Bronchiectasis

This presents with an obstructive picture.

32450

Rate this question:

Next Question

Previous Question | Tag Question

Feedback | End Session

Difficulty: Average

Peer Responses %

Session Progress

Responses Correct:	0
Responses Incorrect:	178
Responses Total:	178
Responses - % Correct:	0%

© Pastest 2017

The airway pressure graph of a patient receiving ventilator support is shown below.

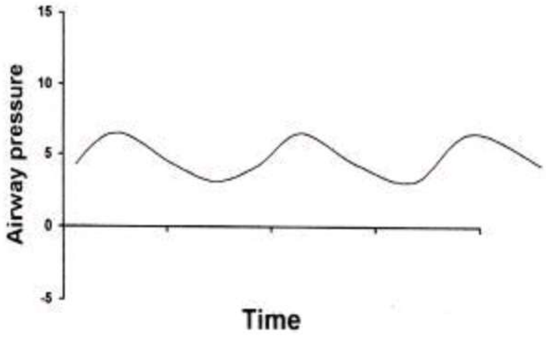

What form of ventilatory support is this patient receiving?

A	Continuous positive airways pressure (CPAP)
B	Positive end-expiratory pressure (PEEP)
C	None
D	Intermittent mandatory ventilation (IMV)
E	Inverse ratio ventilation

32451

Submit

Previous Question | Skip Question

Calculator

Normal Values

© Pastest 2017

The airway pressure graph of a patient receiving ventilator support is shown below.

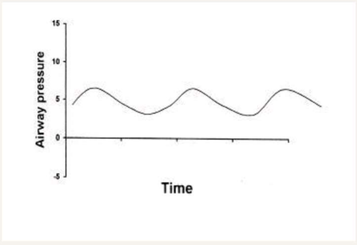

What form of ventilatory support is this patient receiving?

A	Continuous positive airways pressure (CPAP)
B	Positive end-expiratory pressure (PEEP)
C	None
D	Intermittent mandatory ventilation (IMV)
E	Inverse ratio ventilation

Explanation

A	Continuous positive airways pressure (CPAP)

CPAP generates continuous increased pressure, where the shape of the curve of inspiration and expiration stays the same but the whole curve is shifted upwards.

B	Positive end-expiratory pressure (PEEP)

In PEEP, positive pressure is applied at the end of expiration and hence this portion of the curve remains positive for a more prolonged period, with a rapid fall-off at the end of the breath, versus normal respiration.

C	None

In normal respiration the airway pressure returns to baseline at the beginning and end of each breath.

D	Intermittent mandatory ventilation (IMV)

Intermittent mandatory ventilation intersperses ventilator-driven breathing with normal breathing, when the patient's own respiratory effort is inadequate.

E	Inverse ratio ventilation

Inverse ratio ventilation extends the inspiratory phase of breathing, leading to a greater AUC for the inspiratory phase of ventilation, versus the symmetrical curves seen here.

32451

Rate this question:

Next Question

Previous Question | Tag Question

Feedback | End Session

Difficulty: Average

Peer Responses %

Session Progress

Responses Correct:	0
Responses Incorrect:	179
Responses Total:	179
Responses - % Correct:	0%

© Pastest 2017

A 21-year-old woman with a history of well-controlled asthma on salmeterol/fluticasone combination inhaler goes out to an Indonesian restaurant with friends. While eating her main course she suddenly develops a wheeze, feels very light-headed and looks flushed in the face. A taxi is called, which brings her to the Emergency Room. On examination she looks unwell with a BP of 95/55 mmHg, a pulse of 100/min and severe wheeze on auscultation of the chest. She has significant facial flushing and a hives-like rash over her neck. She is given back-to-back salbutamol nebulisers, IV normal saline and IV hydrocortisone.

Which of the following additional therapies is appropriate for her?

A	IV adrenaline
B	IV aminophylline
C	IV magnesium
D	SC adrenalin
E	IM adrenaline

32452

Submit

Previous Question | Skip Question

Calculator

Normal Values

© Pastest 2017

A 21-year-old woman with a history of well-controlled asthma on salmeterol/fluticasone combination inhaler goes out to an Indonesian restaurant with friends. While eating her main course she suddenly develops a wheeze, feels very light-headed and looks flushed in the face. A taxi is called, which brings her to the Emergency Room. On examination she looks unwell with a BP of 95/55 mmHg, a pulse of 100/min and severe wheeze on auscultation of the chest. She has significant facial flushing and a hives-like rash over her neck. She is given back-to-back salbutamol nebulisers, IV normal saline and IV hydrocortisone.

Which of the following additional therapies is appropriate for her?

A	IV adrenaline
B	IV aminophylline
C	IV magnesium
D	SC adrenalin
E	IM adrenaline

Explanation

E	IM adrenaline

This woman has presented with severe anaphylaxis, possibly due to something contained in her Indonesian meal. Immediate therapy centres on volume expansion with normal saline, IV corticosteroids to manage inflammation, IM adrenaline to assist blood pressure and relieve bronchoconstriction, and back-to-back salbutamol nebulisers. Common causes of anaphylaxis, particularly where a trip out for an oriental meal is involved, include allergies to shellfish proteins. Many referral centres have a batch of antigens that can be tested against, either via patch or RAST testing. Of course, she may require long-term anti-histamines or even an adrenaline auto-injector pen, but some attempt at least should be made to identify the precipitating antigen first. Desensitisation therapy may be particularly effective where bee or wasp stings precipitate the anaphylactic attack.

A	IV adrenaline

IV adrenalin has a greater propensity to lead to arrhythmia, and as such would not necessarily be the first choice ahead of the IM option.

B	IV aminophylline

Aminophylline has limited added efficacy versus salbutamol alone with respect to bronchodilatation, and increases the risk of arrhythmia.

C	IV magnesium

Although IV magnesium has a role in the treatment of acute asthma, it doesn't have a positive effect on blood pressure compared with IM adrenalin.

D	SC adrenalin

SC adrenalin leads to local vasoconstriction, which can drive unpredictable absorption and potentially reduced systemic effects. As such, this is not advised.

32452

Rate this question:

Next Question

Previous Question	Tag Question
Feedback	End Session

Difficulty: Average

Peer Responses %

Session Progress

Responses Correct:	0
Responses Incorrect:	180
Responses Total:	180
Responses - % Correct:	0%

© Pastest 2017

A 72-year-old man with a history of COPD and symptoms of benign prostatic hypertrophy presents to the clinic complaining of bone pain. He is a 40 pack-year smoker and takes a range of medications including ramipril, aspirin, atorvastatin, finasteride and a salmeterol/fluticasone combination inhaler. He has lost a few kilos in weight over the past few months without trying, and has seen his GP due to an episode of pneumonia. On examination his BP is 155/81 mmHg, with pulse 75/min (atrial fibrillation). There are coarse crackles on auscultation of the chest consistent with COPD. He looks clubbed.

Investigations:

Hb	11.0 g/dl
WCC	5.2 x10^9/l
PLT	198 x10^9/l
Na^+	138 mmol/l
K^+	4.5 mmol/l
Creatinine	130 µmol/l
ESR	60 mm/hr
Ca^{2+}	2.3 mmol/l

You arrange a bone scan, which reveals a symmetrical increase in uptake along the tubular bones and around the periarticular surfaces. The mandible and both scapulae also show signs of increased isotope uptake.

Which of the following is the most likely diagnosis?

A	Multiple bony metastases from a lung primary
B	Paget's disease
C	Hypertrophic pulmonary osteoarthropathy
D	Osteomalacia
E	Primary hyperparathyroidism

32453

Submit

Previous Question | Skip Question

Calculator

Normal Values

© Pastest 2017

A 72-year-old man with a history of COPD and symptoms of benign prostatic hypertrophy presents to the clinic complaining of bone pain. He is a 40 pack-year smoker and takes a range of medications including ramipril, aspirin, atorvastatin, finasteride and a salmeterol/fluticasone combination inhaler. He has lost a few kilos in weight over the past few months without trying, and has seen his GP due to an episode of pneumonia. On examination his BP is 155/81 mmHg, with pulse 75/min (atrial fibrillation). There are coarse crackles on auscultation of the chest consistent with COPD. He looks clubbed.

Investigations:

Hb	11.0 g/dl
WCC	5.2 $x10^9$/l
PLT	198 $x10^9$/l
Na^+	138 mmol/l
K^+	4.5 mmol/l
Creatinine	130 μmol/l
ESR	60 mm/hr
Ca^{2+}	2.3 mmol/l

You arrange a bone scan, which reveals a symmetrical increase in uptake along the tubular bones and around the periarticular surfaces. The mandible and both scapulae also show signs of increased isotope uptake.

Which of the following is the most likely diagnosis?

A	Multiple bony metastases from a lung primary
B	Paget's disease
C	Hypertrophic pulmonary osteoarthropathy
D	Osteomalacia
E	Primary hyperparathyroidism

Explanation

C Hypertrophic pulmonary osteoarthropathy

Hypertrophic pulmonary osteoarthropathy is a condition seen in patients with a bronchial carcinoma, and may predate the discovery of the underlying lesion. It is characterised by finger clubbing and long bone pain. The most sensitive investigation for making the diagnosis is the isotope bone scan: the findings are typically uptake in long bones, around periarticular surfaces and sometimes also the mandible and scapulae. Symptoms of the condition may resolve when the primary tumour is removed. A chest X-ray has the potential to reveal the primary lung tumour.

A Multiple bony metastases from a lung primary

Symmetrical increase in uptake along tubular bones around periarticular surfaces is seen here, rather than haphazardly increased uptake over the area of the bone scan.

B Paget's disease

Paget's disease often involves one joint only, and most frequently this is only one side of the pelvis. A rise in alkaline phosphatase is seen, in the presence of a normal calcium.

D Osteomalacia

Osteomalacia is associated with a borderline/low serum calcium, proximal bone pain and muscle weakness.

E Primary hyperparathyroidism

Primary hyperparathyroidism is associated with hypercalcaemia, rather than the normal calcium level seen here.

32453

Rate this question:

Next Question

Previous Question | Tag Question

Feedback | End Session

Difficulty: Average

Peer Responses %

Session Progress

Responses Correct:	0
Responses Incorrect:	181
Responses Total:	181
Responses - % Correct:	0%

© Pastest 2017

A 21-year-old man is brought to the Emergency department by his girlfriend. She is very concerned because he appears to fall asleep suddenly during normal activities such as driving the car, sometimes while walking and even whilst having sex on one occasion. On examination his BMI is 25, his BP is 142/60 mmHg. Neurological examination is unremarkable.

Investigations;

Hb	13.1 g/dl
WCC	4.5 $x10^9$/l
PLT	231 $x10^9$/l
Na^+	140 mmol/l
K^+	4.9 mmol/l
Creatinine	105 µ mol/l
Fasting glucose	4.5 mmol/l

Which of the following is the most likely diagnosis?

A	Atypical epilepsy
B	Obstructive sleep apnoea
C	Narcolepsy
D	Syncope
E	Transient global amnesia

32866

Submit

Previous Question | Skip Question

Calculator

Normal Values

© Pastest 2017

A 21-year-old man is brought to the Emergency department by his girlfriend. She is very concerned because he appears to fall asleep suddenly during normal activities such as driving the car, sometimes while walking and even whilst having sex on one occasion. On examination his BMI is 25, his BP is 142/60 mmHg. Neurological examination is unremarkable.

Investigations;

Hb	13.1 g/dl
WCC	4.5 $x10^9$/l
PLT	231 $x10^9$/l
Na^+	140 mmol/l
K^+	4.9 mmol/l
Creatinine	105 µ mol/l
Fasting glucose	4.5 mmol/l

Which of the following is the most likely diagnosis?

A	Atypical epilepsy
B	Obstructive sleep apnoea
C	Narcolepsy
D	Syncope
E	Transient global amnesia

Explanation

The Answer is - Narcolepsy

This patient has the typical features of narcolepsy with sudden falls and lapsing into sleep during normal activities. Unfortunately confirmation of the diagnosis may be difficult. Sleep studies are essential, including the need to rule out obstructive sleep apnoea or other sleep disorders as an alternative cause for the symptoms seen. The falls are caused by loss of muscle tone associated with REM sleep during wakefulness.
Modafinil is a CNS stimulant which increases wakefulness, vigilance and performance. Modafinil appears to be distinct from other stimulants such as methylphenidate as it does not seem to act via the dopaminergic system. Standard dosing is 200-400mg usually given as a single dose in the morning. A number of p450 interactions may occur in patients taking modafinil, so that the datasheet should be scanned for possible cross reactions prior to beginning therapy.

32866

Rate this question:

Next Question

Previous Question | Tag Question

Feedback | End Session

Difficulty: Average

Peer Responses %

Session Progress

Responses Correct:	0
Responses Incorrect:	182
Responses Total:	182
Responses - % Correct:	0%

© Pastest 2017

A 28-year-old man who is currently prescribed highly active anti-retroviral therapy (HAART) comes to the clinic for review. He is extremely worried as he has been working in a homeless shelter with a man who has recently been identified as having active pulmonary tuberculosis. He is currently feeling well. On examination his BP is 122/72 mmHg, pulse is 80/min and regular and he is apyrexial. His chest is clear. His BMI is 25 and has been stable over the past 6 months at least. His CD4 count is 420, and an interferon gamma screen for TB is positive.

Which of the following is the most appropriate next step?

A	Quadruple anti-tuberculous therapy with rifampicin, pyrazinamide, ethambutol and isoniazid for 6 months
B	Dual anti-tuberculous therapy for with rifampicin and pyrazinamide for 2 months
C	Dual anti-tuberculous therapy with rifampicin and isoniazid for 3 months
D	Monotherapy with isoniazid for 6 months
E	Monotherapy with isoniazid for 1 year

34963

Submit

Previous Question Skip Question

Calculator

Normal Values

Blog About Pastest Contact Us Help

© Pastest 2017

A 28-year-old man who is currently prescribed highly active anti-retroviral therapy (HAART) comes to the clinic for review. He is extremely worried as he has been working in a homeless shelter with a man who has recently been identified as having active pulmonary tuberculosis. He is currently feeling well. On examination his BP is 122/72 mmHg, pulse is 80/min and regular and he is apyrexial. His chest is clear. His BMI is 25 and has been stable over the past 6 months at least. His CD4 count is 420, and an interferon gamma screen for TB is positive.

Which of the following is the most appropriate next step?

A	Quadruple anti-tuberculous therapy with rifampicin, pyrazinamide, ethambutol and isoniazid for 6 months
B	Dual anti-tuberculous therapy for with rifampicin and pyrazinamide for 2 months
C	Dual anti-tuberculous therapy with rifampicin and isoniazid for 3 months
D	Monotherapy with isoniazid for 6 months
E	Monotherapy with isoniazid for 1 year

Explanation

C	Dual anti-tuberculous therapy with rifampicin and isoniazid for 3 months

This patient fits the criteria for a diagnosis of latent TB, and in this situation against a background of HIV, anti-tuberculous chemotherapy is considered. The most commonly used option is rifampicin and isoniazid for a 3-month period.

A	Quadruple anti-tuberculous therapy with rifampicin, pyrazinamide, ethambutol and isoniazid for 6 months

Quadruple anti-tuberculous therapy is the intervention for patients suffering from active TB.

B	Dual anti-tuberculous therapy for with rifampicin and pyrazinamide for 2 months

In an attempt to improve adherence, a 2-month rifampicin and pyrazinamide regime was considered but this is not widely used because of reported cases of hepatotoxicity.

D	Monotherapy with isoniazid for 6 months

Monotherapy with isoniazid for 6 months is associated with poor compliance, and so this option risks either incomplete therapy or driving drug resistance.

E	Monotherapy with isoniazid for 1 year

For the reasons stated above, (compliance and potential drug resistance), 1 year of monotherapy with isoniazid is not recommended.

34963

Rate this question:

Next Question

Previous Question	Tag Question
Feedback	End Session

Difficulty: Average

Peer Responses %

Session Progress

Responses Correct:	0
Responses Incorrect:	183
Responses Total:	183
Responses - % Correct:	0%

External Links

BHIVA guidelines for the treatment of TB/HIV coinfection 2011
bhiva.org/TB-HIV-coinfection-guidelines.aspx

© Pastest 2017

A 45-year-old woman is referred to the Respiratory Clinic for review. She has a history of SLE which is currently treated with hydroxychloroquine, but she continues to have multiple joint pains and a photosensitive rash. Over the past few weeks she has suffered from increasingly severe left-sided pleuritic chest pain and a dull chest ache. On examination her BP is 155/85 mmHg, with pulse 75/min and regular. There are decreased breath sounds at the left base on auscultation.

Investigations:

Hb	12.1 g/dl
WCC	10.5 $x10^9$/l
PLT	155 $x10^9$/l
Na^+	137 mmol/l
K^+	4.4 mmol/l
Creatinine	133 micromol/l
ESR	72 mm/1st hour
CXR	small left sided pleural effusion

Which of the following is the most likely underlying cause of her chest symptoms?

A	Alveolar haemorrhage
B	Bronchiolitis obliterans
C	Chronic interstitial pneumonitis
D	Multiple pulmonary emboli
E	Pleuritis

36027

Submit

Previous Question | Skip Question

Calculator

Normal Values

© Pastest 2017

A 45-year-old woman is referred to the Respiratory Clinic for review. She has a history of SLE which is currently treated with hydroxychloroquine, but she continues to have multiple joint pains and a photosensitive rash. Over the past few weeks she has suffered from increasingly severe left-sided pleuritic chest pain and a dull chest ache. On examination her BP is 155/85 mmHg, with pulse 75/min and regular. There are decreased breath sounds at the left base on auscultation.

Investigations:

Hb	12.1 g/dl
WCC	10.5 $x10^9$/l
PLT	155 $x10^9$/l
Na^+	137 mmol/l
K^+	4.4 mmol/l
Creatinine	133 micromol/l
ESR	72 mm/1st hour
CXR	small left sided pleural effusion

Which of the following is the most likely underlying cause of her chest symptoms?

A Alveolar haemorrhage

B Bronchiolitis obliterans

C Chronic interstitial pneumonitis

D Multiple pulmonary emboli

E Pleuritis

Explanation

E Pleuritis

Pleuritis is the most common manifestation of SLE-related lung disease; up to 60% of patients with SLE may report pleuritic chest pain, with or without concomitant pleural effusion. Pleural biopsies are rarely performed, although when they are, usually to exclude alternative diagnoses, non-specific inflammation is seen.

A Alveolar haemorrhage

Alveolar haemorrhage may be seen in SLE, although more rarely than pleuritis, and it is associated with interstitial shadowing rather than the pleural effusion seen here.

B Bronchiolitis obliterans

Bronchiolitis obliterans isn't classically associated with a pleural effusion – it is associated with hyperinflation, attenuation of vascular markings and reticulonodular shadowing in some cases.

C Chronic interstitial pneumonitis

Chronic interstitial pneumonitis (CIP) is associated with more widespread inflammatory infiltrates and may be seen in up to 15% of individuals with SLE.

D Multiple pulmonary emboli

Although pulmonary embolism is a possible differential, multiple pulmonary emboli would be unlikely to affect one segment of the lung only.

36027

Rate this question:

Next Question

Previous Question | Tag Question

Feedback | End Session

Difficulty: Average

Peer Responses %

Session Progress

Responses Correct:	0
Responses Incorrect:	184
Responses Total:	184
Responses - % Correct:	0%

© Pastest 2017

A 24-year-old woman presents to the clinic with a nine-month history of nocturnal cough and shortness of breath, particularly first thing in the morning. She works as a PA in a solicitor's office. She notices wheezing on a number of days during the week. She is a non-smoker. Her weight is stable but she reports symptoms of reflux. A salbutamol inhaler used PRN has had limited impact on her symptoms. On examination her BP is 138/72 mmHg, with pulse 70/min and regular. Her chest is clear. Her BMI is 28. Chest X-ray is unremarkable and her peak flow is 400 (predicted is 480).

Which of the following is the most appropriate intervention for her asthma?

A	Omeprazole
B	Propping up the head of the bed
C	Regular Salbutamol
D	Regular Beclomethasone
E	Regular salmeterol and fluticasone

36468

Submit

Previous Question Skip Question

Calculator

Normal Values

Blog About Pastest Contact Us Help

© Pastest 2017

A 24-year-old woman presents to the clinic with a nine-month history of nocturnal cough and shortness of breath, particularly first thing in the morning. She works as a PA in a solicitor's office. She notices wheezing on a number of days during the week. She is a non-smoker. Her weight is stable but she reports symptoms of reflux. A salbutamol inhaler used PRN has had limited impact on her symptoms. On examination her BP is 138/72 mmHg, with pulse 70/min and regular. Her chest is clear. Her BMI is 28. Chest X-ray is unremarkable and her peak flow is 400 (predicted is 480).

Which of the following is the most appropriate intervention for her asthma?

A	Omeprazole
B	Propping up the head of the bed
C	Regular Salbutamol
D	Regular Beclomethasone
E	Regular salmeterol and fluticasone

Explanation

D	Regular Beclomethasone

This patient has symptoms of asthma, particularly with nocturnal cough, which are not responsive to PRN salbutamol. As such, the next step is regular inhaled beclomethasone.

A	Omeprazole

Although it was previously thought that proton pump inhibitors are effective at treating asthma in this situation, a meta-analysis (see weblink below) has challenged that view.

B	Propping up the head of the bed

Although this is an effective option for managing symptoms of reflux, it's unlikely to impact on her worsening nocturnal cough.

C	Regular Salbutamol

Regular salbutamol is relatively short acting and is therefore a poor treatment option for nocturnal symptoms of asthma.

E	Regular salmeterol and fluticasone

Regular salmeterol and fluticasone is considered a potential escalation step, in the event that symptoms are not controlled on regular inhaled beclomethasone alone.

36468

Rate this question:

Next Question

Previous Question | Tag Question

Feedback | End Session

Difficulty: Difficult

Peer Responses %

Session Progress

Responses Correct:	0
Responses Incorrect:	185
Responses Total:	185
Responses - % Correct:	0%

External Links

The efficacy of proton pump inhibitors for the treatment of asthma in adults: ...
ncbi.nlm.nih.gov/pubmed/21482834

© Pastest 2017

A 69-year-old woman who is known to have severe COPD managed with high-dose fluticasone and salmeterol (combined) and tiotropium comes to the Emergency Department with an infectious exacerbation. She has had a cough productive of thick, yellow sputum for the past few days and now has a severe cough and shortness of breath. She is unable to mobilise more than a few metres from her chair at home. On examination she is pyrexial (38.2°C), her pulse is 90/min and there is atrial fibrillation. Her blood pressure is 123/82 mmHg. There is bilateral wheeze and poor air entry on auscultation of her chest.

Investigations (after 1 h of back-to-back nebulisers and hydrocortisone IV):

Hb	13.4 g/dl
WCC	8.9×10^9/l
PLT	204×10^9/l
Na^+	138 mmol/l
K^+	4.8 mmol/l
Creatinine	139 mol/l
Bicarbonate	28 mmol/l
pH	7.29
pO_2	8.8 kPa
pCO_2	8.0 Ppa

Which of the following is the most appropriate next step?

A	Further nebulisers
B	Intubation and ventilation
C	NIPPV
D	Co-amoxiclav
E	IV Aminophylline

36477

Submit

Previous Question | Skip Question

Calculator

Normal Values

© Pastest 2017

A 69-year-old woman who is known to have severe COPD managed with high-dose fluticasone and salmeterol (combined) and tiotropium comes to the Emergency Department with an infectious exacerbation. She has had a cough productive of thick, yellow sputum for the past few days and now has a severe cough and shortness of breath. She is unable to mobilise more than a few metres from her chair at home. On examination she is pyrexial (38.2°C), her pulse is 90/min and there is atrial fibrillation. Her blood pressure is 123/82 mmHg. There is bilateral wheeze and poor air entry on auscultation of her chest.

Investigations (after 1 h of back-to-back nebulisers and hydrocortisone IV):

Hb	13.4 g/dl
WCC	8.9×10^9/l
PLT	204×10^9/l
Na^+	138 mmol/l
K^+	4.8 mmol/l
Creatinine	139 mol/l
Bicarbonate	28 mmol/l
pH	7.29
pO_2	8.8 kPa
pCO_2	8.0 Ppa

Which of the following is the most appropriate next step?

A Further nebulisers

B Intubation and ventilation

C NIPPV

D Co-amoxiclav

E IV Aminophylline

Explanation

C NIPPV

Guidelines suggest that NIPPV should be considered in all patients with COPD who have respiratory acidosis despite maximal medical therapy. NIPPV should be instigated in a timely fashion, before there is further deterioration.

A Further nebulisers

Further nebulisers are unlikely to impact on air entry or CO_2 retention, only extending the time before NIPPV is instigated.

B Intubation and ventilation

In those with a pH of <7.26, there is evidence that intervention should be stepped up further, with ITU review to consider intubation and ventilation the next step.

D Co-amoxiclav

Antibiotics are instigated only if there is evidence of underlying bacterial infection, and wouldn't acutely impact on his gas exchange.

E IV Aminophylline

Aminophylline is no longer routinely used because of the risk of inducing atrial arrhythmias, with little added beta agonist impact.

36477

Rate this question:

Next Question

Previous Question | Tag Question

Feedback | End Session

Difficulty: Average

Peer Responses %

Session Progress

Responses Correct:	0
Responses Incorrect:	186
Responses Total:	186
Responses - % Correct:	0%

External Links

The Use of Non - Invasive Ventilation in the management of patients with chr...
brit-thoracic.org.uk/document-library/clinical-information/niv/niv-guidelines/the-use...

© Pastest 2017

A 64-year-old man with a history of COPD managed with high-dose fluticasone and salmeterol (combined) comes to the Emergency Department with sudden-onset shortness of breath and left-sided pleuritic chest pain. He is found to have a 1.5 cm pneumothorax. On aspiration this reduces to 0.75 cm.

Which of the following is the most appropriate next step?

A	Discharge with follow-up in 24 h
B	Admit for formal chest drain
C	Admit overnight for oxygen supplementation
D	Repeat aspiration
E	Discharge with follow-up in 2 weeks

36568

Submit

Previous Question | Skip Question

Calculator

Normal Values

© Pastest 2017

A 64-year-old man with a history of COPD managed with high-dose fluticasone and salmeterol (combined) comes to the Emergency Department with sudden-onset shortness of breath and left-sided pleuritic chest pain. He is found to have a 1.5 cm pneumothorax. On aspiration this reduces to 0.75 cm.

Which of the following is the most appropriate next step?

A	Discharge with follow-up in 24 h
B	Admit for formal chest drain
C	Admit overnight for oxygen supplementation
D	Repeat aspiration
E	Discharge with follow-up in 2 weeks

Explanation

C	Admit overnight for oxygen supplementation

This man has a history of COPD, and therefore this case follows the secondary pneumothorax line of the BTS algorithm with respect to management. Because, after aspiration the pneumothorax has reduced in size to <1 cm, observation overnight with oxygen supplementation is the management of choice.

A	Discharge with follow-up in 24 h

Discharge of patients with pneumothorax applies if primary pneumothorax has occurred and has been successfully aspirated; however, review within 2–4 weeks is advised.

B	Admit for formal chest drain

Admission and insertion of a chest drain is only required if air aspiration of the pneumothorax has proved unsuccessful.

D	Repeat aspiration

Repeat aspiration is not required. In the event that air aspiration is unsuccessful, insertion of an 8–14 Fr chest drain is the next step.

E	Discharge with follow-up in 2 weeks

This is the correct course of action when a primary pneumothorax has been successfully aspirated.

36568

Rate this question:

Next Question

Previous Question | Tag Question

Feedback | End Session

Difficulty: Average

Peer Responses %

Session Progress

Responses Correct:	0
Responses Incorrect:	187
Responses Total:	187
Responses - % Correct:	0%

External Links

BTS Pleural Disease Guideline 2010
brit-thoracic.org.uk/document-library/clinical-information/pleural-disease/pleural-dis...

© Pastest 2017

A 62-year-old man who has a history of COPD, for which he takes fluticasone and salmeterol (combined) and salbutamol, comes to the Emergency Department with sudden-onset shortness of breath and right-sided pleuritic chest pain. He takes a number of medications for hypertension and ischaemic heart disease, but has recently enrolled on a pulmonary rehabilitation programme and is walking up to 2 miles per day. On examination his BP is 155/90 mmHg with pulse 92/min and regular. He has diminished breath sounds over the right-hand side on auscultation. Oxygen saturation is reduced at 90%. CXR reveals a right-sided pneumothorax with a 1.5 cm rim of air.

Which of the following is the most appropriate intervention?

A	Admit for high-flow oxygen
B	Air aspiration
C	Discharge and review in 24 h
D	Discharge and review in 2 weeks
E	Insert size 8–14 Fr chest drain

40118

Submit

Previous Question | Skip Question

Calculator

Normal Values

© Pastest 2017

A 62-year-old man who has a history of COPD, for which he takes fluticasone and salmeterol (combined) and salbutamol, comes to the Emergency Department with sudden-onset shortness of breath and right-sided pleuritic chest pain. He takes a number of medications for hypertension and ischaemic heart disease, but has recently enrolled on a pulmonary rehabilitation programme and is walking up to 2 miles per day. On examination his BP is 155/90 mmHg with pulse 92/min and regular. He has diminished breath sounds over the right-hand side on auscultation. Oxygen saturation is reduced at 90%. CXR reveals a right-sided pneumothorax with a 1.5 cm rim of air.

Which of the following is the most appropriate intervention?

A	Admit for high-flow oxygen
B	Air aspiration
C	Discharge and review in 24 h
D	Discharge and review in 2 weeks
E	Insert size 8–14 Fr chest drain

Explanation

E	Insert size 8–14 Fr chest drain

Although the rim is <2 cm, in the presence of significant symptoms (i.e. shortness of breath) a chest drain is preferred to air aspiration and is therefore the correct course of action.

A	Admit for high-flow oxygen

This is the correct course of action after successful air aspiration for secondary pneumothorax, where patients are usually brought into hospital for a period of 24 h.

B	Air aspiration

This is the recommended intervention for a secondary pneumothorax of size 1–2 cm that isn't associated with symptoms.

C	Discharge and review in 24 h

Discharge and review in 2–4 weeks is recommended after successful air aspiration of a primary pneumothorax.

D	Discharge and review in 2 weeks

This is the correct course of action after successful air aspiration of a primary pneumothorax.

40118

Rate this question:

Next Question

Previous Question | Tag Question

Feedback | End Session

Difficulty: Average

Peer Responses %

Session Progress

Responses Correct:	0
Responses Incorrect:	188
Responses Total:	188
Responses - % Correct:	0%

External Links

BTS Pleural Disease Guideline 2010
brit-thoracic.org.uk/document-library/clinical-information/pleural-disease/pleural-dis...

© Pastest 2017

A 72-year-old man presents on the Emergency Medical Take with a worsening cough, productive of scanty, blood-stained sputum. He has stable COPD treated with a high-dose fluticasone and salmeterol inhaler and has not been admitted for an exacerbation for over 2 years. On examination his BP is 135/85 mmHg with pulse 80/min and regular. There are scattered coarse crackles and wheeze on auscultation, consistent with the COPD.

Investigations:

Hb	13.1 g/dl
WCC	9.4 $x10^9$/l
PLT	178 $x10^9$/l
Na^+	133 mmol/l
K^+	4.9 mmol/l
Creatinine	112 micromol/l
ESR	75 mm/1st hour
CXR	Left hilar mass suspicious of malignancy, small left pleural effusion

Which of the following is the most appropriate next step?

A	Blind pleural biopsy
B	Bronchoscopy
C	Contrast enhanced CT
D	Sputum cytology
E	Thoracoscopy

40252

Submit

Previous Question | Skip Question

Calculator

Normal Values

© Pastest 2017

A 72-year-old man presents on the Emergency Medical Take with a worsening cough, productive of scanty, blood-stained sputum. He has stable COPD treated with a high-dose fluticasone and salmeterol inhaler and has not been admitted for an exacerbation for over 2 years. On examination his BP is 135/85 mmHg with pulse 80/min and regular. There are scattered coarse crackles and wheeze on auscultation, consistent with the COPD.

Investigations:

Hb	13.1 g/dl
WCC	9.4 x10^9/l
PLT	178 x10^9/l
Na^+	133 mmol/l
K^+	4.9 mmol/l
Creatinine	112 micromol/l
ESR	75 mm/1st hour
CXR	Left hilar mass suspicious of malignancy, small left pleural effusion

Which of the following is the most appropriate next step?

A	Blind pleural biopsy
B	Bronchoscopy
C	Contrast enhanced CT
D	Sputum cytology
E	Thoracoscopy

Explanation

C Contrast enhanced CT

In this situation, with a central lesion suspicious of bronchial carcinoma, thoraco-abdominal CT including the liver and adrenals is the most appropriate next step. This is carried out before bronchoscopy, because it can provide valuable information about the location of the lung malignancy and nature of the pleural effusion.

A Blind pleural biopsy

Blind pleural biopsy is not recommended because of the risk that an abnormal area of pleura may be missed, and unintended trauma caused versus an ultrasound guided attempt.

B Bronchoscopy

Bronchoscopy is recommended after a CT has been conducted to define the anatomy of an underlying lesion.

D Sputum cytology

Sputum cytology is not of value in the majority of patients and should only be considered when patients refuse, or are unable, to undergo bronchoscopy.

E Thoracoscopy

This may be required for investigation and biopsy of pleural tissue, but CT is more useful as an initial step to define the nature of the effusion.

© Pastest 2017

A 41-year-old man was referred to the hospital with a 1-week history of fever, malaise, increasing confusion, cough and breathlessness. The cough was initially dry but has become productive of yellow sputum in the last few days. He saw the GP 4 days ago, who prescribed Amoxicillin with no benefit. His wife reports that he has also been suffering from abdominal pain and vomiting. He is a smoker of 20/day and works in a large law firm.

On examination he looks unwell and dehydrated. Temperature 39°C, BP 100/50 mmHg, pulse 120/min, respiratory rate 30/min, SpO_2 89% on air and Glasgow Coma Scale score 12. Auscultation of his chest reveals crackles in the left lower zone. His abdomen is generally tender on palpation. Examination is otherwise unremarkable. Urinalysis Blood +++

Investigations;

Hb	11.1 g/dl
WCC	10.6 $x10^9$/l
Neutrophils	9.2 $x10^9$/l
PLT	151 $x10^9$/l
Na^+	127 mmol/l
K^+	3.4 mmol/l
Urea	9.0 mmol/l
Creatinine	120 micromol/l
Bilirubin	28 micromol/l
AST	220 U/l
ALT	190 U/l
ALP	140 U/l
Albumin	28 g/l
CRP	110 mg/l
Arterial blood gases (ABG) on air:	
pH	7.39
PCO_2	4.66 kPa
PO_2	7.3 kPa
Bicarbonate	21.4 mmol/l

Which organism is most likely to be responsible?

A	Streptococcus pneumoniae
B	Legionella pneumophilia
C	Mycoplasma pneumoniae
D	Coxiella burnettii
E	Chlamydia psittaci

70073

Submit

Previous Question | Skip Question

Calculator

Normal Values

© Pastest 2017

A 41-year-old man was referred to the hospital with a 1-week history of fever, malaise, increasing confusion, cough and breathlessness. The cough was initially dry but has become productive of yellow sputum in the last few days. He saw the GP 4 days ago, who prescribed Amoxicillin with no benefit. His wife reports that he has also been suffering from abdominal pain and vomiting. He is a smoker of 20/day and works in a large law firm.

On examination he looks unwell and dehydrated. Temperature 39°C, BP 100/50 mmHg, pulse 120/min, respiratory rate 30/min, SpO_2 89% on air and Glasgow Coma Scale score 12. Auscultation of his chest reveals crackles in the left lower zone. His abdomen is generally tender on palpation. Examination is otherwise unremarkable. Urinalysis Blood +++

Investigations;

Hb	11.1 g/dl
WCC	10.6 x10^9/l
Neutrophils	9.2 x10^9/l
PLT	151 x10^9/l
Na^+	127 mmol/l
K^+	3.4 mmol/l
Urea	9.0 mmol/l
Creatinine	120 micromol/l
Bilirubin	28 micromol/l
AST	220 U/l
ALT	190 U/l
ALP	140 U/l
Albumin	28 g/l
CRP	110 mg/l
Arterial blood gases (ABG) on air:	
pH	7.39
PCO_2	4.66 kPa
PO_2	7.3 kPa
Bicarbonate	21.4 mmol/l

Which organism is most likely to be responsible?

A Streptococcus pneumoniae

B Legionella pneumophilia

C Mycoplasma pneumoniae

D Coxiella burnettii

E Chlamydia psittaci

Explanation

B Legionella pneumophilia

Legionella pneumophila is an aerobic, waterborne, Gram-negative, non-motile bacillus and has three epidemiological patterns:

- Outbreaks due to contaminated water-cooling systems, air-conditioning or showers. May be an occupational history or recent hotel holiday. Usually occurs in previously fit individuals. This man worked in a law firm and it is presumed this contains an air-conditioning system
- Sporadic causes. Rare at extremes of age. Usually age 40-70. More common in men than in women. At-risk groups: smokers, chronic illness – especially chest disease, diabetes mellitus – and alcoholics
- Outbreaks occurring in immunosuppressed individuals, e.g. those on corticosteroids

L. pneumophila can cause 2 distinct disease entities:

- Legionnaires disease which characterised by pneumonia
- Pontiac fever which is a milder self limiting illness consisting of fever and myalgia but no pneumonia

2-15% of community acquired pneumonias requiring hospitalisation globally are secondary to L. pneumophila. Mortality is 10% in treated patients who are not immunocompromised rising to nearly 50% in nosocomial infections.

The incubation period of L. pneumophila is 2-10 days and it typically presents with flu-like symptoms – fevers, malaise, myalgia and headaches; the patient later develops cough (often non-productive), breathlessness and confusion; 50% develop gastrointestinal symptoms (usually diarrhea and vomiting). Patients may also experience pleuritic chest pain and episodes of haemoptysis.

Investigations: hyponatraemia (due to SIADH), lymphopaenia, haematuria, proteinuria and hypoxia. Abnormal liver biochemistry (especially aminotransferases) and renal function occur in 50% of patients.

Diagnosis: the quickest way is to test for Legionella antigen in urine, and direct immunofluorescent staining of the organism in sputum, pleural fluid, or bronchial washings. L. pneumophila is a fastidious organism. Gram stain does not usually reveal an organism and culture on standard media is often negative.

Chest X-ray usually shows lobar and then multilobar shadowing. Small pleural effusions may occur.

Treatment is with a macrolide. The other clue in this question is the lack of response to beta-lactam antibiotics.

A Streptococcus pneumoniae

Whilst S. pneumoniae is the commonest cause of community acquired pneumonia (accounting for 50-70% cases) this gentleman has features of an atypical pneumonia: initial dry cough, lack of response to beta lactam antibiotics, gastrointestinal disturbance in addition to hyponatraemia and deranged liver function. Herpetic cold sores are associated with pneumococcal pneumonia and may be specifically mentioned in an exam question relating to pneumococcal pneumonia.

C Mycoplasma pneumoniae

Pneumonia caused by M. pneumoniae typically affects young adults but usually has a longer prodrome of 2 weeks or more. White cell count may be normal. Cold agglutinins may be present in 50% of patients. Extrapulmonary manifestations include pericarditis, myocarditis, rashes such as erythema multiforme and erythema nodosum, neurological pathology such as cranial or peripheral nerve palsies and meningoencephalitis. Thrombocytopenia and haemolyticanaemia may occur which are not suggested by the blood results given for this question.

D Coxiella burnettii

C. burnetii infection is associated with Q fever. In acute Q fever 60% of patients are asymptomatic. The incubation period varies from 2-6 weeks. There are 3 main clinical presentations:

1. A self limiting flu like illness with abrupt onset of fever, headache, myalgia and arthralgia. This presentation does not fit with the case described
2. Pneumonia (predominant in North America), usually of mild severity and often an incidental finding on CXR. If patients have symptoms typically there will be a dry cough, breathlessness and pleuritic chest pain. Again this presentation does not fit with the case described
3. Hepatitis (predominant in Europe) usually with mild elevation of LFTs. Nausea and vomiting can occur but diarrhea is rare. Whilst some elements of the case described fit with this there are many other symptoms and results in the case which do not and make L. pneumophila more likely

E Chlamydia psittaci

Pneumonia due to C .psittaci is called psittacosis. This is an infection acquired from an avian reservoir and is classically associated with parrots. Incubation period is 5-14 days. Common symptoms include fever, chills and malaise, cough (usually dry), sore throat, mild pharyngitis, epistaxis and severe headache. Whilst some of these symptoms are described in this case the lack of mention of avian contact along with several features more in keeping with L. pneumophila make this option unlikely.

70073

Rate this question:

Next Question

Previous Question | Tag Question

Feedback | End Session

Difficulty: Average

Peer Responses %

Session Progress

Responses Correct:	0
Responses Incorrect:	190
Responses Total:	190
Responses - % Correct:	0%

© Pastest 2017

A 19-year-old man presented with a 10-day history of headaches and malaise. He then developed a dry cough and breathlessness and was admitted to hospital.

On examination he was pyrexial, and he had a rash.

Investigations;

Hb	9.4 g/dl
WCC	10 x 10^9/l
Neutrophils	9.2 x 10^9/l
PLT	200 x 10^9/l
Reticulocytes	5.1%
Na^+	129 mmol/l
K^+	5.0 mmol/l
Urea	4.4 mmol/l
Creatinine	90 micromol/l
Bilirubin	30 micromol/l
AST	44 U/l
ALT	30 U/l
ALP	121 U/l
Albumin	35 g/l
LDH	495 U/l

His CXR is shown below;

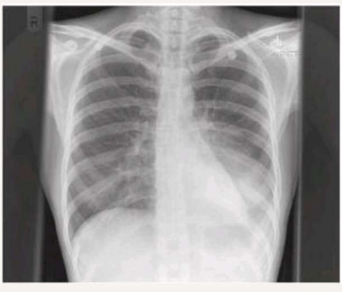

What is the diagnosis?

A	Epstein-Barr virus
B	Legionella pneumonia
C	Streptococcal pneumonia
D	Tuberculosis
E	Mycoplasma pneumonia

70075

Submit

Previous Question | Skip Question

Calculator

Normal Values

© Pastest 2017

A 19-year-old man presented with a 10-day history of headaches and malaise. He then developed a dry cough and breathlessness and was admitted to hospital.

On examination he was pyrexial, and he had a rash.

Investigations;

Hb	9.4 g/dl
WCC	10 x 10^9/l
Neutrophils	9.2 x 10^9/l
PLT	200 x 10^9/l
Reticulocytes	5.1%
Na^+	129 mmol/l
K^+	5.0 mmol/l
Urea	4.4 mmol/l
Creatinine	90 micromol/l
Bilirubin	30 micromol/l
AST	44 U/l
ALT	30 U/l
ALP	121 U/l
Albumin	35 g/l
LDH	495 U/l

His CXR is shown below;

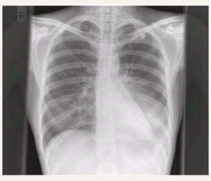

What is the diagnosis?

A	Epstein-Barr virus
B	Legionella pneumonia
C	Streptococcal pneumonia
D	Tuberculosis
E	Mycoplasma pneumonia

Explanation

E	Mycoplasma pneumonia

Mycoplasma usually affects young individuals and occurs in epidemics every 3-4 years. Chest symptoms are usually preceded by non-specific symptoms such as malaise and headaches.

The CXR usually shows only one lobe to be involved; however, about 20% show bilateral pneumonia. There is often a discrepancy between X-ray appearances and the clinical condition of the patient.

Diagnosis is by Mycoplasma serology; cold agglutinins occur in 50%. The image shows erythema multiforme, which further supports the diagnosis. The blood results suggest a haemolyticanaemia with a reticulocytosis, hyperbilirubinaemia and elevated LDH; autoimmune haemolyticanaemia (AHIA), when caused by cold agglutinins, is associated with Mycoplasma and can be diagnosed with a direct Coomb's test.

A	Epstein-Barr virus

EBV causes infectious mononucleosis. It is not assocated with pneumonia. Disease is characterised by malaise and upper respiratory tract symptoms.

B	Legionella pneumonia

Whilst dry cough, malaise, hyponatraemia and pneumonia are compatible with the diagnosis of Legionella pneumonia, the presence or erythema multiforme and headache with normal LFTs in a teenage patient is more consistent with Mycoplasma pneumonia.

C	Streptococcal pneumonia

This patient presents with features of an atypical pneumonia.

D	Tuberculosis

TB tends to affect upper lobes, is usually associated with associated with fever, night sweats and weight loss. No potential contact source of TB is mentioned making this diagnosis unlikely.

70075

Rate this question:

Next Question

Previous Question | Tag Question

Feedback | End Session

Difficulty: Average

Peer Responses %

Session Progress

Responses Correct:	0
Responses Incorrect:	191
Responses Total:	191
Responses - % Correct:	0%

© Pastest 2017

A 19-year-old man presented with a 10-day history of headaches and malaise. He then developed a dry cough and breathlessness and was admitted to hospital.

On examination he was pyrexial, and he had a rash.

Investigations;

Hb	9.4 g/dl
WCC	10 x 10^9/l
Neutrophils	9.2 x 10^9/l
PLT	200 x 10^9/l
Reticulocytes	5.1%
Na^+	129 mmol/l
K^+	5.0 mmol/l
Urea	4.4 mmol/l
Creatinine	90 micromol/l
Bilirubin	30 micromol/l
AST	44 U/l
ALT	30 U/l
ALP	121 U/l
Albumin	35 g/l
LDH	495 U/l

His CXR is shown below;

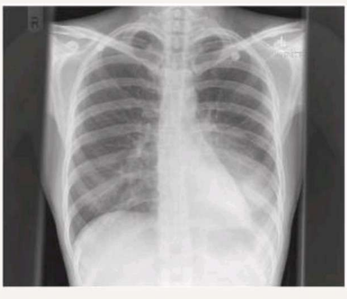

Which investigation is most likely to lead to the correct diagnosis?

A	EBV serology
B	Urine Legionella antigen
C	Standard sputum culture
D	Mycobacterial culture
E	Mycoplasma serology

70076

Submit

Previous Question | Skip Question

Calculator

Normal Values

© Pastest 2017

A 19-year-old man presented with a 10-day history of headaches and malaise. He then developed a dry cough and breathlessness and was admitted to hospital.

On examination he was pyrexial, and he had a rash.

Investigations;

Hb	9.4 g/dl
WCC	10 x 10^9/l
Neutrophils	9.2 x 10^9/l
PLT	200 x 10^9/l
Reticulocytes	5.1%
Na^+	129 mmol/l
K^+	5.0 mmol/l
Urea	4.4 mmol/l
Creatinine	90 micromol/l
Bilirubin	30 micromol/l
AST	44 U/l
ALT	30 U/l
ALP	121 U/l
Albumin	35 g/l
LDH	495 U/l

His CXR is shown below;

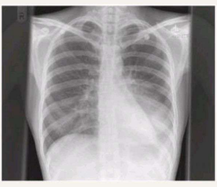

Which investigation is most likely to lead to the correct diagnosis?

A	EBV serology
B	Urine Legionella antigen
C	Standard sputum culture
D	Mycobacterial culture
E	Mycoplasma serology

Explanation

E	Mycoplasma serology

Mycoplasma usually affects young individuals and occurs in epidemics every 3-4 years. Chest symptoms are usually preceded by non-specific symptoms such as malaise and headaches.

The CXR usually shows only one lobe to be involved; however, about 20% show bilateral pneumonia. There is often a discrepancy between X-ray appearances and the clinical condition of the patient.

Diagnosis is by Mycoplasma serology; cold agglutinins occur in 50%. The image shows erythema multiforme, which further supports the diagnosis. The blood results suggest a haemolyticanaemia with a reticulocytosis, hyperbilirubinaemia and elevated LDH; autoimmune haemolyticanaemia (AHIA), when caused by cold agglutinins, is associated with Mycoplasma and can be diagnosed with a direct Coomb's test.

A	EBV serology

The diagnosis here is Mycoplasma so this is not an appropriate option.

B	Urine Legionella antigen

The diagnosis here is Mycoplasma so this is not an appropriate option.

C	Standard sputum culture

The diagnosis here is Mycoplasma so this is not an appropriate option.

D	Mycobacterial culture

The diagnosis here is Mycoplasma so this is not an appropriate option.

70076

Rate this question:

Next Question

Previous Question	Tag Question
Feedback	End Session

Difficulty: Average

Peer Responses %

Session Progress

Responses Correct:	0
Responses Incorrect:	192
Responses Total:	192
Responses - % Correct:	0%

© Pastest 2017

54-year-old stonemason was referred to the clinic with a 3-year history of progressive breathlessness. He is an ex-smoker (40 pack-years) having stopped 14 years ago.

On examination he looked well, was not clubbed and there was no lymphadenopathy. His chest was hyperexpanded and he had basal inspiratory crackles.

His spirometry revealed:

FEV_1	38% predicted
FVC	70% predicted
KCO	55% predicted

His CXR is shown below;

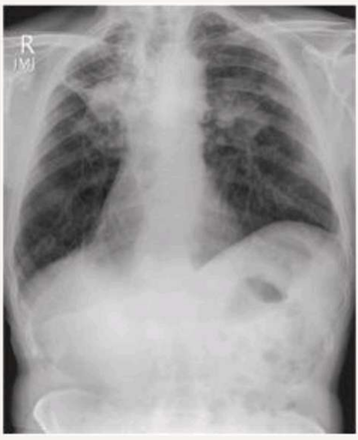

What is the underlying diagnosis?

A	Silicosis
B	Asbestosis
C	Byssinosis
D	Berylliosis
E	Simple pneumoconiosis

70077

Submit

Previous Question | Skip Question

Calculator

Normal Values

© Pastest 2017

54-year-old stonemason was referred to the clinic with a 3-year history of progressive breathlessness. He is an ex-smoker (40 pack-years) having stopped 14 years ago.

On examination he looked well, was not clubbed and there was no lymphadenopathy. His chest was hyperexpanded and he had basal inspiratory crackles.

His spirometry revealed:

FEV_1	38% predicted
FVC	70% predicted
KCO	55% predicted

His CXR is shown below;

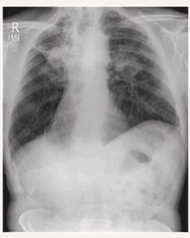

What is the underlying diagnosis?

A	Silicosis
B	Asbestosis
C	Byssinosis
D	Berylliosis
E	Simple pneumoconiosis

Explanation

A Silicosis

Silicosis is a fibrotic lung disease associated with inhalation of silica (silicon dioxide), which is highly fibrogenic. It is usually seen in quarrying and mining tunneling occupations and in sandblasters, ceramic workers, pottery workers and in stonemasons if the dust generated contains quartz.

Acute silicosis may present as an acute illness within 12 months of exposure to very heavy exposure and is characterised by dry cough and breathlessness. Patients deteriorate rapidly over 1-2 years and there is no effective treatment to slow the progression. Chronic silicosis runs a more chronic course as in this patient and is associated with a gradual worsening of breathlessness associated with restrictive lung function and a reduced transfer factor. Chronic silicosis is associated with silicotic nodule formation 3-5mm in diameter which predominatly affect the upper lobes.These nodules may coalesce and cause progressive massive fibrosis. Diagnosis is made on history of exposure and chest X-ray changes. The chest X-ray may show hilar eggshell calcification (pathognomonic of silicosis), as in the chest X-ray shown, with our without upper zone pulmonary nodules and fibrosis.

B Asbestosis

There is no mention of potential exposure to asbestos and the chest radiograph shows no pleural or diaphragmatic calcification to suggest previous asbestos exposure.

C Byssinosis

Byssinosis is associated with exposure to cotton dust, flax and hemp.

D Berylliosis

Berylliosis is associated with inhalation of fumes from the molten metal beryllium.

E Simple pneumoconiosis

Simple pneumoconiosis, also known as simple coal worker's pneumoconiosis, is associated with exposure to coal dust and is classically seen in miners. It is usually relatively asymptomatic unless progressive massive fibrosis develops.

70077

Rate this question:

Next Question

Previous Question | Tag Question

Feedback | End Session

Difficulty: Average

Peer Responses %

Session Progress

Responses Correct:	0
Responses Incorrect:	193
Responses Total:	193
Responses - % Correct:	0%

© Pastest 2017

54-year-old stonemason was referred to the clinic with a 3-year history of progressive breathlessness. He is an ex-smoker (40 pack-years) having stopped 14 years ago.

On examination he looked well, was not clubbed and there was no lymphadenopathy. His chest was hyperexpanded and he had basal inspiratory crackles.

His spirometry revealed:

FEV_1	38% predicted
FVC	70% predicted
KCO	55% predicted

His CXR from the original referral is shown below;

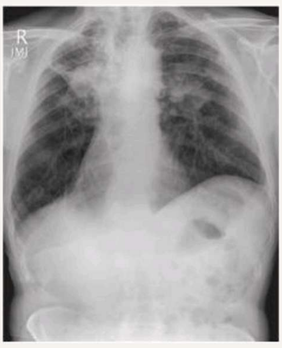

Three years later he presented to the Emergency Department with increasing shortness of breath, cough and wheeze. Over the last year he had recurrent chest infections and now had a cough productive of green sputum.

On examination: respiratory rate 30/min, temperature 36.2°C, BP 160/100 mmHg, pulse 130/min, SpO_2 57% on air.

He was breathing through pursed lips. Auscultation of his chest revealed expiratory wheeze and crackles throughout.

Blood gases on 28% oxygen;

pH	7.22
PO_2	7.9 kPa
PCO_2	8.0 kPa
Bicarbonate	20 mmol/l
Base excess	-3

What do the blood gases show?

A	Metabolic acidosis
B	Respiratory acidosis
C	Mixed respiratory and metabolic acidosis
D	Respiratory acidosis with metabolic compensation
E	Metabolic acidosis with respiratory compensation

70078

Submit

Previous Question | Skip Question

Calculator

Normal Values

© Pastest 2017

54-year-old stonemason was referred to the clinic with a 3-year history of progressive breathlessness. He is an ex-smoker (40 pack-years) having stopped 14 years ago.

On examination he looked well, was not clubbed and there was no lymphadenopathy. His chest was hyperexpanded and he had basal inspiratory crackles.

His spirometry revealed:

FEV_1	38% predicted
FVC	70% predicted
KCO	55% predicted

His CXR from the original referral is shown below;

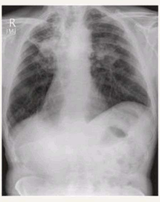

Three years later he presented to the Emergency Department with increasing shortness of breath, cough and wheeze. Over the last year he had recurrent chest infections and now had a cough productive of green sputum.

On examination: respiratory rate 30/min, temperature 36.2°C, BP 160/100 mmHg, pulse 130/min, SpO_2 57% on air.

He was breathing through pursed lips. Auscultation of his chest revealed expiratory wheeze and crackles throughout.

Blood gases on 28% oxygen;

pH	7.22
PO_2	7.9 kPa
PCO_2	8.0 kPa
Bicarbonate	20 mmol/l
Base excess	-3

What do the blood gases show?

A	Metabolic acidosis
B	Respiratory acidosis
C	Mixed respiratory and metabolic acidosis
D	Respiratory acidosis with metabolic compensation
E	Metabolic acidosis with respiratory compensation

Explanation

C	Mixed respiratory and metabolic acidosis

This man also has an element of chronic obstructive pulmonary disease (COPD) – mixed obstructive and restrictive spirometry (FEV1 more markedly reduced than FVC) and a history of smoking. He later presents with an exacerbation, made worse by the underlying silicosis, with a mixed respiratory and metabolic acidosis. He is commenced on a trial of non-invasive ventilation (NIV) and initially does well. He later desaturates as he develops a pneumothorax. The treatment of choice in any ventilated patient with a pneumothorax is insertion of a chest drain. If the patient had a tension pneumothorax, a chest drain should be inserted after initial decompression with a cannula.

Silicosis is a fibrotic lung disease associated with inhalation of silica (silicon dioxide), which is highly fibrogenic. It is usually seen in quarrying and mining tunneling occupations and in sandblasters, ceramic workers, pottery workers and in stonemasons if the dust generated contains quartz.

Acute silicosis may present as an acute illness within 12 months of exposure to very heavy exposure and is characterised by dry cough and breathlessness. Patients deteriorate rapidly over 1-2 years and there is no effective treatment to slow the progression. Chronic silicosis runs a more chronic course as in this patient and is associated with a gradual worsening of breathlessness associated with restrictive lung function and a reduced transfer factor. Chronic silicosis is associated with silicotic nodule formation 3-5mm in diameter which predominatly affect the upper lobes.These nodules may coalesce and cause progressive massive fibrosis. Diagnosis is made on history of exposure and chest X-ray changes. The chest X-ray may show hilar eggshell calcification (pathognomonic of silicosis), as in the chest X-ray shown, with our without upper zone pulmonary nodules and fibrosis.

A	Metabolic acidosis

His CO_2 is raised in addition to a low bicarbonate and base excess.

B	Respiratory acidosis

His CO_2 is raised in addition to a low bicarbonate and base excess.

D	Respiratory acidosis with metabolic compensation

If he had metabolic compensation his base excess and bicarbonate would be raised.

E	Metabolic acidosis with respiratory compensation

In respiratory compensation the carbon dioxide is reduced.

70078

Rate this question:

Next Question

Previous Question | Tag Question

Feedback | End Session

Difficulty: Average

Peer Responses %

Session Progress

Responses Correct:	0
Responses Incorrect:	194
Responses Total:	194
Responses - % Correct:	0%

© Pastest 2017

54-year-old stonemason was referred to the clinic with a 3-year history of progressive breathlessness. He is an ex-smoker (40 pack-years) having stopped 14 years ago.

On examination he looked well, was not clubbed and there was no lymphadenopathy. His chest was hyperexpanded and he had basal inspiratory crackles.

His spirometry revealed:

FEV_1	38% predicted
FVC	70% predicted
KCO	55% predicted

His CXR from the original referral is shown below;

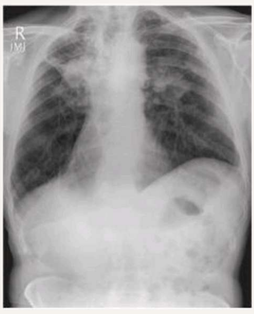

Three years later he presented to the Emergency Department with increasing shortness of breath, cough and wheeze. Over the last year he had recurrent chest infections and now had a cough productive of green sputum.

On examination: respiratory rate 30/min, temperature 36.2°C, BP 160/100 mmHg, pulse 130/min, SpO_2 57% on air.

He was breathing through pursed lips. Auscultation of his chest revealed expiratory wheeze and crackles throughout.

Blood gases on 28% oxygen;

pH	7.22
PO_2	7.9 kPa
PCO_2	8.0 kPa
Bicarbonate	20 mmol/l
Base excess	-3

Despite controlled oxygen, antibiotics, nebulisers and hydrocortisone, he fails to improve and is moved to ICU where he is started on non-invasive ventilation (inspiratory positive airway pressure, IPAP, 12 cm H_2O; and expiratory positive airway pressure, EPAP, 5 cm H_2O).

Initially he does very well but he suddenly desaturates, although his BP remains stable.

On examination the left side of his chest had reduced expansion, was hyper-resonant on percussion with diminished breath sounds. The trachea was not deviated.

What would you do?

A	Aspirate left side of the chest with a 16- or 14-G cannula – maximum 2 litres
B	Insert a left-sided chest drain
C	Remove non-invasive ventilation
D	Increase IPAP
E	Reduce EPAP

70079

Submit

Previous Question | Skip Question

Calculator

Normal Values

© Pastest 2017

54-year-old stonemason was referred to the clinic with a 3-year history of progressive breathlessness. He is an ex-smoker (40 pack-years) having stopped 14 years ago.

On examination he looked well, was not clubbed and there was no lymphadenopathy. His chest was hyperexpanded and he had basal inspiratory crackles.

His spirometry revealed:

FEV_1	38% predicted
FVC	70% predicted
KCO	55% predicted

His CXR from the original referral is shown below;

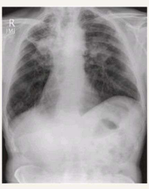

Three years later he presented to the Emergency Department with increasing shortness of breath, cough and wheeze. Over the last year he had recurrent chest infections and now had a cough productive of green sputum.

On examination: respiratory rate 30/min, temperature 36.2°C, BP 160/100 mmHg, pulse 130/min, SpO_2 57% on air.

He was breathing through pursed lips. Auscultation of his chest revealed expiratory wheeze and crackles throughout.

Blood gases on 28% oxygen;

pH	7.22
PO_2	7.9 kPa
PCO_2	8.0 kPa
Bicarbonate	20 mmol/l
Base excess	-3

Despite controlled oxygen, antibiotics, nebulisers and hydrocortisone, he fails to improve and is moved to ICU where he is started on non-invasive ventilation (inspiratory positive airway pressure, IPAP, 12 cm H_2O; and expiratory positive airway pressure, EPAP, 5 cm H_2O).

Initially he does very well but he suddenly desaturates, although his BP remains stable.

On examination the left side of his chest had reduced expansion, was hyper-resonant on percussion with diminished breath sounds. The trachea was not deviated.

What would you do?

A	Aspirate left side of the chest with a 16- or 14-G cannula – maximum 2 litres
B	Insert a left-sided chest drain
C	Remove non-invasive ventilation
D	Increase IPAP
E	Reduce EPAP

Explanation

B	Insert a left-sided chest drain

Silicosis is a fibrotic lung disease associated with inhalation of silica (silicon dioxide), which is highly fibrogenic. It is usually seen in quarrying and mining tunneling occupations and in sandblasters, ceramic workers, pottery workers and in stonemasons if the dust generated contains quartz.

Acute silicosis may present as an acute illness within 12 months of exposure to very heavy exposure and is characterised by dry cough and breathlessness. Patients deteriorate rapidly over 1-2 years and there is no effective treatment to slow the progression. Chronic silicosis runs a more chronic course as in this patient and is associated with a gradual worsening of breathlessness associated with restrictive lung function and a reduced transfer factor. Chronic silicosis is associated with silicotic nodule formation 3-5mm in diameter which predominatly affect the upper lobes.These nodules may coalesce and cause progressive massive fibrosis. Diagnosis is made on history of exposure and chest X-ray changes. The chest X-ray may show hilar eggshell calcification (pathognomonic of silicosis), as in the chest X-ray shown, with or without upper zone pulmonary nodules and fibrosis.

This man also has an element of chronic obstructive pulmonary disease (COPD) – mixed obstructive and restrictive spirometry (FEV1 more markedly reduced than FVC) and a history of smoking. He later presents with an exacerbation, made worse by the underlying silicosis, with a mixed respiratory and metabolic acidosis. He is commenced on a trial of non-invasive ventilation (NIV) and initially does well. He later desaturates as he develops a pneumothorax. The treatment of choice in any ventilated patient with a pneumothorax is insertion of a chest drain. If the patient had a tension pneumothorax, a chest drain should be inserted after initial decompression with a cannula.

A	Aspirate left side of the chest with a 16- or 14-G cannula – maximum 2 litres

He has no clinical evidence to suggest tension pneumothorax. He is on non invasive ventilation therefore a chest drain is required.

C	Remove non-invasive ventilation

The priority is definitive treatment for his pneumothorax.

D	Increase IPAP

Increasing his IPAP will increase positive airway pressure and accelerate progression of his pneumothorax.

E	Reduce EPAP

Increasing his EPAP will reduce his pressure support and undertreat his respiratory failure and will not treat his pneumothorax.

70079

Rate this question:

Next Question

Previous Question | Tag Question

Feedback | End Session

Difficulty: Average

Peer Responses %

Session Progress

Responses Correct:	0
Responses Incorrect:	195
Responses Total:	195
Responses - % Correct:	0%

© Pastest 2017

A 70-year-old lady presented in acute respiratory distress. She had some chest pain earlier that morning. She is an ex-smoker of 30 pack-years (20/day for 30 years).

On examination she looked unwell. Respiratory rate 30/min, pulse 120/min, BP 80/50 mmHg and O_2 saturation was 80% on air. Heart sounds were normal and her chest was clear.

ABG on air:

pH	7.44
PO_2	7.0 kPa
PCO_2	3.25 kPa
Base excess	-2.6
Bicarbonate	19.5 mmol/l

You manage to get an urgent CT within the hour, shown below:

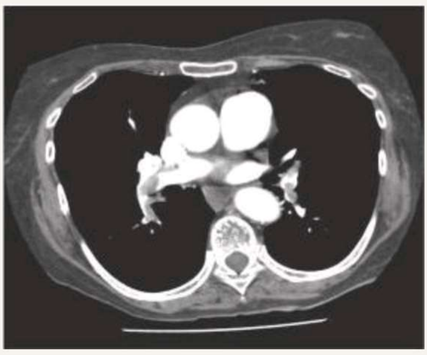

What is the diagnosis?

A	Congestive cardiac failure
B	Myocardial infarction
C	Pneumonia
D	Pulmonary embolism
E	Pneumothorax

70080

Submit

Previous Question Skip Question

Calculator

Normal Values

Blog About Pastest Contact Us Help

© Pastest 2017

A 70-year-old lady presented in acute respiratory distress. She had some chest pain earlier that morning. She is an ex-smoker of 30 pack-years (20/day for 30 years).

On examination she looked unwell. Respiratory rate 30/min, pulse 120/min, BP 80/50 mmHg and O_2 saturation was 80% on air. Heart sounds were normal and her chest was clear.

ABG on air:

pH	7.44
PO_2	7.0 kPa
PCO_2	3.25 kPa
Base excess	-2.6
Bicarbonate	19.5 mmol/l

You manage to get an urgent CT within the hour, shown below:

What is the diagnosis?

A	Congestive cardiac failure
B	Myocardial infarction
C	Pneumonia
D	Pulmonary embolism
E	Pneumothorax

Explanation

D	Pulmonary embolism

This is a 'get it or you don't'-type question. The reason it is PE and not any of the other options is because the CTPA clearly shows pulmonary emboli, which rules out all the other options.

This lady has had a massive pulmonary embolus. She presented with shortness of breath and tachypnoea. Her arterial blood gases show she has type I respiratory failure; note the low CO_2 – common in PE.

The CT shows large filling defects in the left and right main pulmonary arteries.

The aim of this question is to ensure the candidate is aware of the British Thoracic Society guidelines on the treatment of massive PE.[1] The guidelines state that if a PE is severe enough to cause circulatory collapse, thrombolysis should be given as early as possible. The current guidelines recommend alteplase as the thrombolytic agent of choice as it can be given to the hypotensive patient, as in this example.

[1]British Thoracic Society Standards of Care Committee, Pulmonary Embolism Guidelines Development Group. 2003. British Thoracic Society guidelines for the management of suspected acute pulmonary embolism. Thorax, 58, 470-484.

http://www.brit-thoracic.org.uk/index.asp

A	Congestive cardiac failure
B	Myocardial infarction
C	Pneumonia
E	Pneumothorax

This is a 'get it or you don't'-type question. The reason it is PE and not any of the other options is because the CTPA clearly shows pulmonary emboli, which rules out all the other options.

This lady has had a massive pulmonary embolus. She presented with shortness of breath and tachypnoea. Her arterial blood gases show she has type I respiratory failure; note the low CO2 - common in PE.

The CT shows large filling defects in the left and right main pulmonary arteries.

The aim of this question is to ensure the candidate is aware of the British Thoracic Society guidelines on the treatment of massive PE.[1] The guidelines state that if a PE is severe enough to cause circulatory collapse, thrombolysis should be given as early as possible. The current guidelines recommend alteplase as the thrombolytic agent of choice as it can be given to the hypotensive patient, as in this example.

[1]British Thoracic Society Standards of Care Committee, Pulmonary Embolism Guidelines Development Group. 2003. British Thoracic Society guidelines for the management of suspected acute pulmonary embolism. Thorax, 58, 470-484.

http://www.brit-thoracic.org.uk/index.asp

70080

Rate this question:

Next Question

Previous Question | Tag Question

Feedback | End Session

Difficulty: Average

Peer Responses %

Session Progress

Responses Correct:	0
Responses Incorrect:	196
Responses Total:	196
Responses - % Correct:	0%

Blog About Pastest Contact Us Help

© Pastest 2017

A 70-year-old lady presented in acute respiratory distress. She had some chest pain earlier that morning. She is an ex-smoker of 30 pack-years (20/day for 30 years).

On examination she looked unwell. Respiratory rate 30/min, pulse 120/min, BP 80/50 mmHg and O_2 saturation was 80% on air. Heart sounds were normal and her chest was clear.

ABG on air:

pH	7.44
PO_2	7.0 kPa
PCO_2	3.25 kPa
Base excess	-2.6
Bicarbonate	19.5 mmol/l

You manage to get an urgent CT within the hour, shown below:

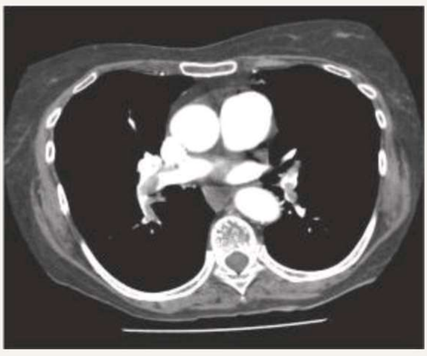

The patient deteriorates; What is the immediate management?

A	Diuretics
B	Intravenous antibiotics
C	Streptokinase
D	Alteplase
E	Low molecular weight heparin

70081

Submit

Previous Question | Skip Question

Calculator

Normal Values

© Pastest 2017

A 70-year-old lady presented in acute respiratory distress. She had some chest pain earlier that morning. She is an ex-smoker of 30 pack-years (20/day for 30 years).

On examination she looked unwell. Respiratory rate 30/min, pulse 120/min, BP 80/50 mmHg and O_2 saturation was 80% on air. Heart sounds were normal and her chest was clear.

ABG on air:

pH	7.44
PO_2	7.0 kPa
PCO_2	3.25 kPa
Base excess	-2.6
Bicarbonate	19.5 mmol/l

You manage to get an urgent CT within the hour, shown below:

The patient deteriorates; What is the immediate management?

A Diuretics

B Intravenous antibiotics

C Streptokinase

D Alteplase

E Low molecular weight heparin

Explanation

D Alteplase

This lady has had a massive pulmonary embolus. She presented with shortness of breath and tachypnoea. Her arterial blood gases show she has type I respiratory failure; note the low CO_2 – common in PE.

The CT shows large filling defects in the left and right main pulmonary arteries.

The aim of this question is to ensure the candidate is aware of the British Thoracic Society guidelines on the treatment of massive PE.[1] The guidelines state that if a PE is severe enough to cause circulatory collapse, thrombolysis should be given as early as possible. The current guidelines recommend alteplase as the thrombolytic agent of choice as it can be given to the hypotensive patient, as in this example.

[1]British Thoracic Society Standards of Care Committee, Pulmonary Embolism Guidelines Development Group. 2003. British Thoracic Society guidelines for the management of suspected acute pulmonary embolism. Thorax, 58, 470-484.

http://www.brit-thoracic.org.uk/index.asp

A Diuretics

Diuretics would be an appropriate treatment for acute pulmonary oedema.

B Intravenous antibiotics

Intravenous antibiotics would be appropriate treatment if clinically she had severe pneumonia or sepsis.

C Streptokinase

The thrombolytic therapy of choice for PE with haemodynamic instability is Alteplase.

E Low molecular weight heparin

Low molecular weight heparin is used to treat patients with PE and no haemodynamic compromise whilst they are initiated on long-term anticoagulation such as warfarin to therapeutic levels. Unfractionated heparin is used alongside thrombolysis in patients with PE and haemodynamic instability.

70081

Rate this question:

Next Question

Previous Question | Tag Question

Feedback | End Session

Difficulty: Average

Peer Responses %

Session Progress

Responses Correct:	0
Responses Incorrect:	197
Responses Total:	197
Responses - % Correct:	0%

© Pastest 2017

You are on call on Boxing Day and you are referred a 61-year-old lady with shortness of breath. Her only other complaint is of recent diarrhoea. She is a smoker of 30/day. She tells you that she consumed far too much alcohol the previous day and does not remember going to bed. She woke up on the floor.

On examination she looks unwell. Her temperature is 38.5°C. On auscultation of her chest she has coarse crackles at the right base. She has a distended abdomen with dullness in the flanks.

Investigations reveal;

Hb	11.1 g/dl
WCC	12.3 x109/l
Neutrophils	9.5 $x10^9$/l
PLT	88 $x10^9$/l
MCV	101 fl
Na^+	130 mmol/l
K^+	3.4 mmol/l
Urea	7.8 mmol/l
Creatinine	77 micromol/l
INR	1.4
Bilirubin	16 micromol/l
AST	73 U/l
ALP	300 U/l
Albumin	30 g/l
Gamma-GT	100 U/l
Creatine Kinase	700 U/l

Her CXR is shown below;

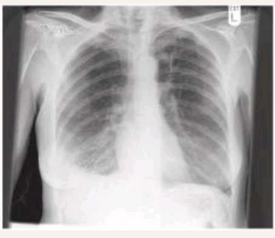

The most likely diagnosis is?

A	Mycoplasma pneumonia
B	Legionella pneumonia
C	Aspiration pneumonia
D	Streptococcal pneumonia
E	Klebsiella pneumonia

70082

Submit

Previous Question | Skip Question

Calculator

Normal Values

© Pastest 2017

You are on call on Boxing Day and you are referred a 61-year-old lady with shortness of breath. Her only other complaint is of recent diarrhoea. She is a smoker of 30/day. She tells you that she consumed far too much alcohol the previous day and does not remember going to bed. She woke up on the floor.

On examination she looks unwell. Her temperature is 38.5°C. On auscultation of her chest she has coarse crackles at the right base. She has a distended abdomen with dullness in the flanks.

Investigations reveal;

Hb	11.1 g/dl
WCC	12.3 x109/l
Neutrophils	9.5 $x10^9$/l
PLT	88 $x10^9$/l
MCV	101 fl
Na^+	130 mmol/l
K^+	3.4 mmol/l
Urea	7.8 mmol/l
Creatinine	77 micromol/l
INR	1.4
Bilirubin	16 micromol/l
AST	73 U/l
ALP	300 U/l
Albumin	30 g/l
Gamma-GT	100 U/l
Creatine Kinase	700 U/l

Her CXR is shown below;

The most likely diagnosis is?

A	Mycoplasma pneumonia
B	Legionella pneumonia
C	Aspiration pneumonia
D	Streptococcal pneumonia
E	Klebsiella pneumonia

Explanation

C	Aspiration pneumonia

This is aspiration pneumonia. This lady is an alcoholic (thrombocytopaenia, macrocytosis, raised INR and abnormal liver function tests, in particular the gamma GT). She has consumed too much alcohol on Christmas Day, fallen (note creatine kinase) and aspirated. The chest X-ray shows a right lower lobe pneumonia consistent with an aspiration pneumonia.

A	Mycoplasma pneumonia

Mycoplasma pneumonia usually affects young adults and is associated with dry cough, fever, headache and malaise.

B	Legionella pneumonia

The clinical findings are compatible with ascites and her bloods are consistent with chronic rather than acute liver disease.

D	Streptococcal pneumonia

The history is suggestive of aspiration pneumonia rather than classical community acquired pneumonia.

E	Klebsiella pneumonia

Klebsiella pneumonia is associated with lung destruction including cavitation and abscess formation.

70082

Rate this question:

Next Question

Previous Question | Tag Question

Feedback | End Session

Difficulty: Average

Peer Responses %

Session Progress

Responses Correct:	0
Responses Incorrect:	198
Responses Total:	198
Responses - % Correct:	0%

© Pastest 2017

A 39-year old Irish accountant was referred to the clinic with a 4-month history of progressive breathlessness. He noticed this mainly on climbing the stairs. Over the last few months he had been using some eye drops from the local pharmacy for dry eyes. He was also complaining of fatigue, night sweats and polyuria. He was a non-smoker and drank 20 units of alcohol a week.

On examination he had conjunctival injection, but examination of his eyes was otherwise unremarkable. He had no rash or joint swelling. On auscultation of his chest he had fine inspiratory crackles. Heart sounds were normal. He had no organomegaly on palpation of the abdomen. Urinalysis was unremarkable.

Investigations:

Hb	10.1 g/dl
MCV	84 fl
WCC	6.4 x10^9/l
PLT	201 x10^9/l
ESR	45 mm/1st hour
Na^+	141 mmol/l
K^+	3.9 mmol/l
Urea	7.2 mmol/l
Creatinine	100 micromol/l
Bilirubin	23 micromol/l
AST	51 U/l
ALP	191 U/l
Albumin	45 g/l
Tuberculin test	Negative
Pulmonary function tests:	
FEV1	75% predicted
FVC	70% predicted
TLCO	80% predicted

His CXR is shown;

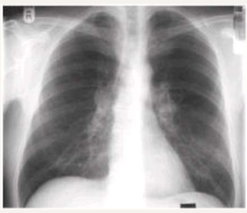

What is the most likely diagnosis?

A	Tuberculosis
B	Berylliosis
C	Small-cell lung carcinoma
D	Sarcoidosis
E	Langerhan's cell histiocytosis

70083

Submit

Previous Question | Skip Question

Calculator

Normal Values

© Pastest 2017

A 39-year old Irish accountant was referred to the clinic with a 4-month history of progressive breathlessness. He noticed this mainly on climbing the stairs. Over the last few months he had been using some eye drops from the local pharmacy for dry eyes. He was also complaining of fatigue, night sweats and polyuria. He was a non-smoker and drank 20 units of alcohol a week.

On examination he had conjunctival injection, but examination of his eyes was otherwise unremarkable. He had no rash or joint swelling. On auscultation of his chest he had fine inspiratory crackles. Heart sounds were normal. He had no organomegaly on palpation of the abdomen. Urinalysis was unremarkable.

Investigations:

Hb	10.1 g/dl
MCV	84 fl
WCC	6.4 x10^{9}/l
PLT	201 x10^{9}/l
ESR	45 mm/1st hour
Na^{+}	141 mmol/l
K^{+}	3.9 mmol/l
Urea	7.2 mmol/l
Creatinine	100 micromol/l
Bilirubin	23 micromol/l
AST	51 U/l
ALP	191 U/l
Albumin	45 g/l
Tuberculin test	Negative
Pulmonary function tests:	
FEV1	75% predicted
FVC	70% predicted
TLCO	80% predicted

His CXR is shown;

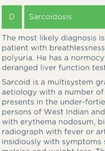

What is the most likely diagnosis?

A	Tuberculosis
B	Beryllliosis
C	Small-cell lung carcinoma
D	Sarcoidosis
E	Langerhan's cell histiocytosis

Explanation

D Sarcoidosis

The most likely diagnosis is sarcoidosis. This is a relatively young patient with breathlessness, dry eyes, fatigue, night sweats and polyuria. He has a normocytic anaemia, a raised ESR and slightly deranged liver function tests.

Sarcoid is a multisystem granulomatous disorder of unkown aetiology with a number of different presentations. It usually presents in the under-forties, and is more common in women and persons of West Indian and Africand escent. Presentation may be with erythema nodosum, bilateral hilar lymphadenopathy on chest radiograph with fever or arthralgia (Löfgrens syndrome), or more insidiously with symptoms such as dyspnoea, dry cough, fever, malaise and weight loss. The main differential diagnoses are TB and lymphoma.

The diagnosis is suggested from a chest X-ray and high-resolution CT. High resolution CT characteristically shows features such as hilar and mediastinal lymphadenopathy, peribronchovascular nodules, ground glass shadowing, parenchymal bands, cysts and fibrosis. Pulmonary involvement can be classified according to the radiographic stage of the disease as below:

Stage 0: Clear chest radiograph
Stage 1: Bihilar adenopathy
Stage 2: Bihilar adenopathy and interstitial infiltrates
Stage 3: Diffuse interstitial disease
Stage 4: Advanced fibrosis

Transbronchial biopsy is the investigation with the highest yield as positive results are seen in 90% of patients with pulmonary sarcoidosis. Endobronchial biopsies are also useful but less sensitive. Histology typically shows non-caseating granulomas composed of macrophages, lymphocytes and epithelioid histiocytes which fuse to form multinucleate giant cells.

Serum ACE is not specific as raised levels are also seen in pulmonary TB, asbestosis, silicosis and lymphoma. It is elevated in about 75% of patients with untreated sarcoid. The value of using serum ACE to monitor disease activity remains unclear. 24-hour urinary calcium excretion is often raised

The lung function tests depend on severity of the disease. The tuberculin test is negative in 80% of patients with sarcoidosis but clinicians must be mindful that anergy can also be seen in HIV positive patients or patients who have overwhelming TB.

Treatment is rarely required in stage 0 or 1 disease. Corticosteroids should be given to patients with stage 2 or higher disease with deterioration in lung function or patients with ocular sarcoid, hypercalcaemia, severe or persistent erythema nodosum, myocardial and neurological manifestations of sarcoidosis. Prednisolone dose is 0.5mg/kg for first 4 weeks of treatment and is then downtitrated to lowest maintenance dose that controls the disease. Treatment withdrawal should be considered after 6-24 months. Steroid sparing agents such as Methotrexate or Azathioprine may be used for relapsing disease.

In this question the other diagnoses can be ruled out as follows: Langerhans' cell histiocytosis is unlikely as it usually presents in younger patients and nearly all affected individuals have a history of current or previous smoking; he has a negative (grade 0-1) Heaf test, making TB unlikely, because with the degree of change on the CXR one would expect a positive Heaf test (unless the patient was immunosuppressed) and the patient to be more unwell (also one would expect most Irish citizens to have a positive (up to grade 2) Heaf test (due to previous BCG vaccination); berylliosis is a possible alternative, but there is no evidence of exposure; small-cell lung cancer is unusual in a young non-smoker.

Common clinical characteristics of sarcoidosis include:

- Skin:
  Erythema nodosum – caution, not always on the shins
  Lupus pernio – red crusty lesions, often around the nose
  Annular lesion
- Polyuria:
  Secondary to hypercalciuria/hypercalcaemia (can also cause renal calculi and nephrocalcinosis)
  Secondary to central diabetes insipidus
- Cardiac:
  Ventricular arrhythmias
  Conduction defects
  Cardiomyopathy
  Congestive cardiac failure
- Neurological:
  Involvement of CNS occurs in 2%
  Cranial diabetes insipidus
- Ocular:
  Anterior uveitis
  Conjunctivitis
  Retinal lesions
  Keratoconjunctivitis sicca and lacrimal gland enlargement
  Optic neuritis
- Metabolic:
  Hypercalcaemia and hypercalciuria
- Bone and joints:
  Arthralgia
  Bone cysts
- Others:
  Hepatosplenomegaly
  Löfgren's syndrome (acute sarcodosis) – triad of bihilar lymphadenopathy, arthritis and erythema nodosum

A Tuberculosis

No history of contact with TB, no fevers. Inflammatory markers are normal and tuberculin test is negative (with no history to suggest immunosuppression).

B Beryllliosis

No history suggestive of beryllium exposure. Bilateral hilar lymphadenopathy is not a feature of berylliosis.

C Small-cell lung carcinoma

The patient is young and is a non smoker, the chest radiograph does not show any lung lesion suggestive of a lung malignancy, it shows bilateral lymphadenopathy and diffuse interstitial infiltrates.

E Langerhan's cell histiocytosis

Langerhan's histiocytosis is associated with smoking and patients are usually young.

TOTAL

Rate this question:

Next Question

Previous Question | Tag Question

Feedback | End Session

Difficulty: Average

Peer Responses %

Session Progress

Responses Correct:	0
Responses Incorrect:	199
Responses Total:	199
Responses - % Correct:	0%

Blog About Pastest Contact Us Help

© Pastest 2017

A 39-year old Irish accountant was referred to the clinic with a 4-month history of progressive breathlessness. He noticed this mainly on climbing the stairs. Over the last few months he had been using some eye drops from the local pharmacy for dry eyes. He was also complaining of fatigue, night sweats and polyuria. He was a non-smoker and drank 20 units of alcohol per week.

On examination he had conjunctival injection, but examination of his eyes was otherwise unremarkable. He had no rash or joint swelling. On auscultation of his chest he had fine inspiratory crackles. Heart sounds were normal. He had no organomegaly on palpation of the abdomen. Urinalysis was unremarkable.

Investigations:

Hb	10.1 g/dl
WCC	6.4 × 10^9/l
PLT	201 × 10^9/l
Na+	141 mmol/l
K+	3.9 mmol/l
Creatinine	100 mol/l
MCV	84 fl
ESR	45 mm/1st h
Urea	7.2 mmol/l
Bilirubin	23 mol/l
AST	51 U/l
ALP	91 U/l
Albumin	45 g/l
Tuberculin test	-
FEV1	75% predicted
FVC	70% predicted
TLCO	80% predicted

His CXR is shown below.

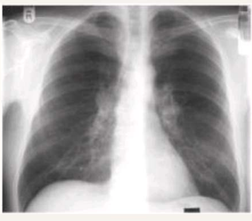

Which of the following is most likely to give you a definitive diagnosis?

A	Serum angiotensin-converting enzyme
B	Sputum for microbiology
C	Bronchoscopy and transbronchial biopsies
D	Bronchoscopy and endobronchial biopsies
E	Kveim test

70084

Submit

Previous Question | Skip Question

Calculator

Normal Values

© Pastest 2017

A 39-year old Irish accountant was referred to the clinic with a 4-month history of progressive breathlessness. He noticed this mainly on climbing the stairs. Over the last few months he had been using some eye drops from the local pharmacy for dry eyes. He was also complaining of fatigue, night sweats and polyuria. He was a non-smoker and drank 20 units of alcohol per week.

On examination he had conjunctival injection, but examination of his eyes was otherwise unremarkable. He had no rash or joint swelling. On auscultation of his chest he had fine inspiratory crackles. Heart sounds were normal. He had no organomegaly on palpation of the abdomen. Urinalysis was unremarkable.

Investigations:

Hb	10.1 g/dl
WCC	6.4 × 10^9/l
PLT	201 × 10^9/l
Na+	141 mmol/l
K+	3.9 mmol/l
Creatinine	100 mol/l
MCV	84 fl
ESR	45 mm/1st h
Urea	7.2 mmol/l
Bilirubin	23 mol/l
AST	51 U/l
ALP	91 U/l
Albumin	45 g/l
Tuberculin test	-
FEV1	75% predicted
FVC	70% predicted
TLCO	80% predicted

His CXR is shown below.



Which of the following is most likely to give you a definitive diagnosis?

A	Serum angiotensin-converting enzyme
B	Sputum for microbiology
C	Bronchoscopy and transbronchial biopsies
D	Bronchoscopy and endobronchial biopsies
E	Kveim test

Explanation

C Bronchoscopy and transbronchial biopsies

The most likely diagnosis is sarcoidosis. This is a relatively young patient with breathlessness, dry eyes, fatigue, night sweats and polyuria. He has a normocytic anaemia, a raised ESR and slightly deranged liver function tests.

Sarcoid is a multi-system granulomatous disorder of unknown aetiology with a number of different presentations. It usually presents in the under-forties, and is more common in women and persons of West Indian and African descent. Presentation may be with erythema nodosum, bilateral hilar lymphadenopathy on chest radiography with fever or arthralgia (Löfgren syndrome) or, more insidiously, with symptoms such as dyspnoea, dry cough, fever, malaise and weight loss. The main differential diagnoses are TB and lymphoma.

The diagnosis is suggested from a chest X-ray and high-resolution CT. High-resolution CT characteristically shows features such as hilar and mediastinal lymphadenopathy, peribronchovascular nodules, ground-glass shadowing, parenchymal bands, cysts and fibrosis. Pulmonary involvement can be classified according to the radiographic stage of the disease:

Stage 0: Clear chest radiograph
Stage 1: Bi-hilar adenopathy
Stage 2: Bi-hilar adenopathy and interstitial infiltrates
Stage 3: Diffuse interstitial disease
Stage 4: Advanced fibrosis.

Transbronchial biopsy is the investigation with the highest yield, as positive results are seen in 90% of patients with pulmonary sarcoidosis. Endobronchial biopsies are also useful, but less sensitive. Histology typically shows non-caseating granulomas composed of macrophages, lymphocytes and epithelioid histiocytes, which fuse to form multinucleate giant cells.

The lung function tests depend on severity of the disease. The tuberculin test is negative in 80% of patients with sarcoidosis, but clinicians must be mindful that anergy can also be seen in HIV-positive patients or patients who have overwhelming TB.

Treatment is rarely required in stage 0 or 1 disease. Corticosteroids should be given to patients with stage 2 or higher disease with deterioration in lung function or in patients with ocular sarcoid, hypercalcaemia, severe or persistent erythema nodosum, myocardial and neurological manifestations of sarcoidosis. Prednisolone dose is 0.5 mg/kg for first 4 weeks of treatment and is then down-titrated to the lowest maintenance dose that controls the disease. Treatment withdrawal should be considered after 6-24 months. Steroid-sparing agents such as methotrexate or azathioprine may be used for relapsing disease.

Common clinical characteristics of sarcoidosis include:

- Skin:
  Erythema nodosum – caution, not always on the shins
  Lupus pernio – red crusty lesions, often around the nose
  Annular lesion
- Polyuria:
  Secondary to hypercalciuria/hypercalcaemia (can also cause renal calculi and nephrocalcinosis)
  Secondary to central diabetes insipidus
- Cardiac:
  Ventricular arrhythmias
  Conduction defects
  Cardiomyopathy
  Congestive cardiac failure
- Neurological:
  Involvement of CNS occurs in 2%
  Cranial diabetes insipidus
- Ocular:
  Anterior uveitis
  Conjunctivitis
  Retinal lesions
  Keratoconjunctivitis sicca and lacrimal gland enlargement
  Optic neuritis
- Metabolic:
  Hypercalcaemia and hypercalciuria
- Bone and joints:
  Arthralgia
  Bone cysts

Others:
Hepatosplenomegaly
Löfgren syndrome (acute sarcodosis) – triad of bi-hilar lymphadenopathy, arthritis and erythema nodosum.

A Serum angiotensin-converting enzyme

Serum ACE is not a specific test for sarcoidosis. Raised ACE levels are also seen in pulmonary TB, asbestosis, silicosis and lymphoma. It is elevated in about 75% of patients with untreated sarcoid. The value of using serum ACE to monitor disease activity remains unclear – currently inflammatory markers are thought to be more useful.

B Sputum for microbiology

This is not a history of infection. Sputum culture will be negative. Culture may be useful in the event that TB is suspected, although there is no history of potential TB exposure.

D Bronchoscopy and endobronchial biopsies

Endobronchial biopsies may give a diagnosis of sarcoidosis, but transbronchial biopsies in addition to endobronchial biopsies will give a higher yield.

E Kveim test

The Kveim test is now obsolete because of potential infection risk. It involves using material from the spleen of a patient suffering from sarcoidosis.

700144

Rate this question:

Next Question

Previous Question | Tag Question
Feedback | End Session

Difficulty: Average

Peer Responses %

Session Progress

Responses Correct:	0
Responses Incorrect:	200
Responses Total:	200
Responses - % Correct:	0%

Blog About Pastest Contact Us Help

© Pastest 2017

An 18-year-old man presents to the Outpatients Department having coughed up a small amount of bright red blood. He is mildly short of breath and feels 'wheezy'. His mother says he has always been a 'chesty' child. He was teased at school as he has always been the smallest in his class. His brother and sister were fit and well. He had a dog at home.

On examination he looked well and was not breathless at rest. He had clubbing. He had nasal polyps and auscultation of his chest revealed coarse crackles throughout both lung fields. His abdomen was distended but soft.

Urinalysis:

Protein	+
Glucose	++
Nitrites	-
Leucocytes	-

Haematology:

Hb	11.0 g/dl
WCC	12.1 × 10^9/l
PLT	450 × 10^9/l
Na+	137 mmol/l
K+	3.9 mmol/l
Creatinine	62 mol/l
Neutrophils	91%
Lymphocytes	8%
Monocytes	0.4%
MVC	84 fl
ESR	35 mm/1st h
CRP	40 g/l
Urea	6.4 mmol/l
Bilirubin	31 mol/l
AST	46 U/l
ALP	221 U/l
Albumin	38 g/l
Protein	74 g/l
Mg^{2+}	0.64 mmol/l
Ca^{2+}	2.1 mmol/l
Phosphate	0.75 mmol/l

Spirometry:

FEV1	60% predicted
FVC	80% predicted
PEF	350 l/min
KCO	70% predicted

His CXR is shown below.

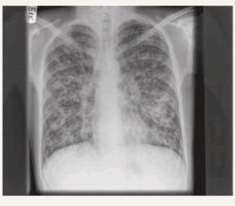

What is the most likely underlying diagnosis?

A	Cystic fibrosis
B	Kartagener's syndrome
C	Asthma
D	Allergic bronchopulmonary aspergillosis
E	Goodpasture's syndrome

70085

Submit

Previous Question | Skip Question

Calculator

Normal Values

© Pastest 2017

An 18-year-old man presents to the Outpatients Department having coughed up a small amount of bright red blood. He is mildly short of breath and feels 'wheezy'. His mother says he has always been a 'chesty' child. He was teased at school as he has always been the smallest in his class. His brother and sister were fit and well. He had a dog at home.

On examination he looked well and was not breathless at rest. He had clubbing. He had nasal polyps and auscultation of his chest revealed coarse crackles throughout both lung fields. His abdomen was distended but soft.

Urinalysis:

Protein	+
Glucose	++
Nitrites	-
Leucocytes	-

Haematology:

Hb	11.0 g/dl
WCC	12.1 × 10^9/l
PLT	450 × 10^9/l
Na+	137 mmol/l
K+	3.9 mmol/l
Creatinine	62 mol/l
Neutrophils	91%
Lymphocytes	8%
Monocytes	0.4%
MVC	84 fl
ESR	35 mm/1st h
CRP	40 g/l
Urea	6.4 mmol/l
Bilirubin	31 mol/l
AST	46 U/l
ALP	221 U/l
Albumin	38 g/l
Protein	74 g/l
Mg^{2+}	0.64 mmol/l
Ca^{2+}	2.1 mmol/l
Phosphate	0.75 mmol/l

Spirometry:

FEV1	60% predicted
FVC	80% predicted
PEF	350 l/min
KCO	70% predicted

His CXR is shown below.

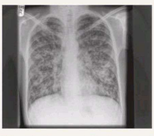

What is the most likely underlying diagnosis?

A	Cystic fibrosis
B	Kartagener's syndrome
C	Asthma
D	Allergic bronchopulmonary aspergillosis
E	Goodpasture's syndrome

Explanation

A Cystic fibrosis

This patient has cystic fibrosis. He has had recurrent chest infections secondary to bronchiectasis (confirmed by examination findings and the chest X-ray, but also note the long line inserted via the left antecubital fossa), he is small for his age and has nasal polyps (which occur in one third of patients with CF) and clubbing. Pulmonary function tests show airflow obstruction. He has mildly deranged liver function tests – secondary to obstruction of biliary ductules in the liver. This can eventually lead to cirrhosis. He has glucose in his urine – pancreatic islet cells are destroyed as the pancreas becomes fibrotic, resulting in CF-related diabetes in 30% of patients by adulthood.

The most likely cause of this patient's haemoptysis is secondary to infection. Larger-volume hemoptysis can occur in cystic fibrosis due to bronchial artery hypertrophy. Ninety per cent of patients with cystic fibrosis will have steatorrhoea secondary to pancreatic insufficiency if pancreatic enzyme replacement therapy is not taken with food.

B Kartagener's syndrome

Kartagener syndrome causes bronchiectasis and situs inversus. The chest radiograph does not show dextrocardia.

C Asthma

The chest X-ray is inconsistent with a diagnosis of simple asthma. With significant patchy interstitial shadowing and failure to thrive, cystic fibrosis is suspected.

D Allergic bronchopulmonary aspergillosis

ABPA is associated with proximal bronchiectasis, fleeting pulmonary infiltrates, lobar collapse and wheeze. It responds to treatment with systemic corticosteroids and itraconazole.

E Goodpasture's syndrome

Goodpasture syndrome, or anti-GBM disease, is a cause of haemoptysis, although it is associated with acute deterioration in renal function with glomerulonephritis and marked haemoptysis.

70085

Rate this question:

Next Question

Previous Question | Tag Question

Feedback | End Session

Difficulty: Average

Peer Responses %

Session Progress

Responses Correct:	0
Responses Incorrect:	201
Responses Total:	201
Responses - % Correct:	0%

© Pastest 2017

An 18-year-old man presents to the Outpatients Department having coughed up a small amount of bright red blood. He is mildly short of breath and feels 'wheezy'. His mother says he has always been a 'chesty' child. He was teased at school as he has always been the smallest in his class. His brother and sister were fit and well. He had a dog at home.

On examination he looked well and was not breathless at rest. He had clubbing. He had nasal polyps and auscultation of his chest revealed coarse crackles throughout both lung fields. His abdomen was distended but soft.

Urinalysis:

Protein	+
Glucose	++
Nitrites	-
Leucocytes	-

Haematology:

Hb	11.0 g/dl
WCC	12.1 × 10^9/l
PLT	450 × 10^9/l
Na^+	137 mmol/l
K^+	3.9 mmol/l
Creatinine	62 mol/l
Neutrophils	91%
Lymphocytes	8%
Monocytes	0.4%
MVC	84 fl
ESR	35 mm/1st h
CRP	40 g/l
Urea	6.4 mmol/l
Bilirubin	31 mol/l
AST	46 U/l
ALP	221 U/l
Albumin	38 g/l
Protein	74 g/l
Mg^{2+}	0.64 mmol/l
Ca^{2+}	2.1 mmol/l
Phosphate	0.75 mmol/l

Spirometry:

FEV1	60% predicted
FVC	80% predicted
PEF	350 l/min
KCO	70% predicted

His CXR is shown below.

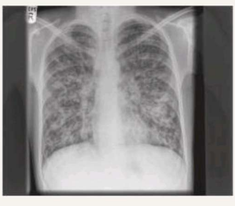

What is the test most likely to establish a diagnosis?

A	Metacholine challenge test
B	Anti-GBM antibodies
C	Electron microscopy of cilia
D	Sweat test
E	Aspergillus precipitins

70086

Submit

Previous Question | Skip Question

Calculator

Normal Values

© Pastest 2017

An 18-year-old man presents to the Outpatients Department having coughed up a small amount of bright red blood. He is mildly short of breath and feels 'wheezy'. His mother says he has always been a 'chesty' child. He was teased at school as he has always been the smallest in his class. His brother and sister were fit and well. He had a dog at home.

On examination he looked well and was not breathless at rest. He had clubbing. He had nasal polyps and auscultation of his chest revealed coarse crackles throughout both lung fields. His abdomen was distended but soft.

Urinalysis:

Protein	+
Glucose	++
Nitrites	-
Leucocytes	-

Haematology:

Hb	11.0 g/dl
WCC	12.1 × 10^9/l
PLT	450 × 10^9/l
Na^+	137 mmol/l
K^+	3.9 mmol/l
Creatinine	62 mol/l
Neutrophils	91%
Lymphocytes	8%
Monocytes	0.4%
MVC	84 fl
ESR	35 mm/1st h
CRP	40 g/l
Urea	6.4 mmol/l
Bilirubin	31 mol/l
AST	46 U/l
ALP	221 U/l
Albumin	38 g/l
Protein	74 g/l
Mg^{2+}	0.64 mmol/l
Ca^{2+}	2.1 mmol/l
Phosphate	0.75 mmol/l

Spirometry:

FEV1	60% predicted
FVC	80% predicted
PEF	350 l/min
KCO	70% predicted

His CXR is shown below.

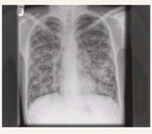

What is the test most likely to establish a diagnosis?

A	Metacholine challenge test
B	Anti-GBM antibodies
C	Electron microscopy of cilia
D	Sweat test
E	Aspergillus precipitins

Explanation

D	Sweat test

The correct answer is A), cystic fibrosis. This patient has cystic fibrosis. He has had recurrent chest infections secondary to bronchiectasis (confirmed by examination findings and the chest X-ray, but also note the long line inserted via the left antecubital fossa), he is small for his age and has nasal polyps (which occur in one third of patients with CF) and clubbing. Pulmonary function tests show airflow obstruction. He has mildly deranged liver function tests – secondary to obstruction of biliary ductules in the liver. This can eventually lead to cirrhosis. He has glucose in his urine – pancreatic islet cells are destroyed as the pancreas becomes fibrotic, resulting in CF-related diabetes in 30% of patients by adulthood.

The most likely cause of this patient's haemoptysis is secondary to infection. Larger-volume hemoptysis can occur in cystic fibrosis due to bronchial artery hypertrophy. Ninety per cent of patients with cystic fibrosis will have steatorrhoea secondary to pancreatic insufficiency if pancreatic enzyme replacement therapy is not taken with food.

A	Metacholine challenge test

This is a test for asthma. It is rarely performed, given that a diagnosis of asthma can usually be made according to other clinical criteria.

B	Anti-GBM antibodies

This is a test for Goodpasture syndrome, which is associated with a deterioration in renal function accompanied by haemoptysis over a relatively short period of time.

C	Electron microscopy of cilia

This test is used to diagnose primary ciliary dyskinesia or Kartagener syndrome.

E	Aspergillus precipitins

This is a test used in the diagnosis of ABPA, which is associated with symptoms of asthma and patchy shadowing on the CXR. A poor response is usually seen to conventional inhaled asthma medications.

70086

Rate this question:

Next Question

Previous Question | Tag Question

Feedback | End Session

Difficulty: Average

Peer Responses %

Session Progress

Responses Correct:	0
Responses Incorrect:	202
Responses Total:	202
Responses - % Correct:	0%

© Pastest 2017

A 16-year-old boy presents to the Outpatients Department having coughed up a small amount of bright-red blood. He is mildly short of breath and feels 'wheezy'. His mother says he has always been a 'chesty' child. He was teased at school as he has always been the smallest in his class. His brother and sister were fit and well. He had a dog at home.

On examination he looked well and was not breathless at rest. He had clubbing. He had nasal polyps and auscultation of his chest revealed coarse crackles throughout both lung fields. His abdomen was distended but soft.

Urinalysis reveals;

Protein	+
Glucose	++
Nitrites	negative
Leucocytes	negative

Investigations reveal;

Hb	11.0 g/dl
WCC	12.1 x 10^9/l
Neutrophils	91%
Lymphocytes	8%
Monocytes	0.4%
MCV	84 fl
PLT	450 x 10^9/l
ESR	35 mm/1st hour
CRP	40 mg/l
Na^+	137 mmol/l
K^+	3.9 mmol/l
Urea	6.4 mmol/l
Creatinine	62 micromol/l
Bilirubin	31 micromol/l
AST	46 U/l
ALP	221 U/l
Albumin	38 g/l
Protein	74 g/l
Magnesium	0.64 mmol/l
Calcium	2.1 mmol/l
Phosphate	0.75 mmol/l

Spirometry:

FEV1	60% predicted
FVC	80% predicted
PEF	350 l/min
KCO	70% predicted

His CXR is displayed below;

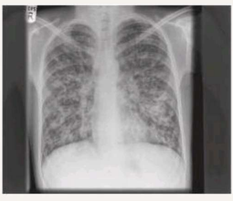

Which pathogen is most likely to colonise this patient?

A	Streptococcus pneumoniae
B	Staphylococcus aureus
C	Aspergillus fumigatus
D	Pseudomonas aeruginosa
E	Mycobacterium tuberculosis

70087

Submit

Previous Question | Skip Question

Calculator

Normal Values

© Pastest 2017

A 16-year-old boy presents to the Outpatients Department having coughed up a small amount of bright-red blood. He is mildly short of breath and feels 'wheezy'. His mother says he has always been a 'chesty' child. He was teased at school as he has always been the smallest in his class. His brother and sister were fit and well. He had a dog at home.

On examination he looked well and was not breathless at rest. He had clubbing. He had nasal polyps and auscultation of his chest revealed coarse crackles throughout both lung fields. His abdomen was distended but soft.

Urinalysis reveals;

Protein	+
Glucose	++
Nitrites	negative
Leucocytes	negative

Investigations reveal;

Hb	11.0 g/dl
WCC	12.1 x 10^9/l
Neutrophils	91%
Lymphocytes	8%
Monocytes	0.4%
MCV	84 fl
PLT	450 x 10^9/l
ESR	35 mm/1st hour
CRP	40 mg/l
Na^+	137 mmol/l
K^+	3.9 mmol/l
Urea	6.4 mmol/l
Creatinine	62 micromol/l
Bilirubin	31 micromol/l
AST	46 U/l
ALP	221 U/l
Albumin	38 g/l
Protein	74 g/l
Magnesium	0.64 mmol/l
Calcium	2.1 mmol/l
Phosphate	0.75 mmol/l

Spirometry:

FEV1	60% predicted
FVC	80% predicted
PEF	350 l/min
KCO	70% predicted

His CXR is displayed below;

Which pathogen is most likely to colonise this patient?

A	Streptococcus pneumoniae
B	Staphylococcus aureus
C	Aspergillus fumigatus
D	Pseudomonas aeruginosa
E	Mycobacterium tuberculosis

Explanation

D	Pseudomonas aeruginosa

The answer is Pseudomonas aeruginosa -

This boy has cystic fibrosis. He has had recurrent chest infections secondary to bronchiectasis (confirmed by examination findings and the chest X-ray, also note long line inserted via left antecubital fossa), he is small for his age, has nasal polyps (which occur in one third of patients with CF) and clubbing. Pulmonary function tests show airflow obstruction He has mildly deranged liver function tests – secondary to obstruction of biliary ductules in the liver. This can eventually lead to cirrhosis. He has glucose in his urine – pancreatic islet cells are destroyed as the pancreas becomes fibrotic resulting in CF related diabetes in 30% of patients by adulthood.

By the time patients are in their teenage years, Pseudomonas aeruginosa is the commonest organism to colonise the patient. Patients tend to be infected initially with Staphylococcus aureus but his age now makes this less likely.

Male cystic fibrosis patients are infertile due to failure of the development of the vas deferens and epididymis.

Treatment is with pancreatic supplements, prophylactic inhaled or nebulised antibiotics, strict glucose control, mucolytics/DNAase and regular physiotherapy with postural drainage. Prophylactic Azithromycin is used for its immunomodulatory effects. Non invasive ventilation may be used in patients with chronic type 2 respiratory failure as a bridge to lung transplantation Lung transplantation is considered as a treatment option once there is severe respiratory compromise.

A	Streptococcus pneumoniae

Streptococcus pneumoniae is incorrect, it is not commonly seen in CF.

B	Staphylococcus aureus

Staphylococcus aureus is incorrect, it is more common in early childhood in CF. Infection with P. aeruginosa dominates in later adolescence and adulthood.

C	Aspergillus fumigatus

Aspergillus fumigatus is incorrect, it is commonly found in sputum cultures of individuals with CF but is less likely to be found conisistently than Pseudomonas.

E	Mycobacterium tuberculosis

Isolation of Mycobacterium tuberculosis is incorrect, this is very uncommon in CF.

70087

Rate this question:

Next Question

Previous Question | Tag Question

Feedback | End Session

Difficulty: Average

Peer Responses %

Session Progress

Responses Correct:	0
Responses Incorrect:	203
Responses Total:	203
Responses - % Correct:	0%

© Pastest 2017

A 56-year-old man presented to his GP with a 4-week history of feeling generally unwell. He described nasal congestion, with pain under his left eye, flu-like symptoms and lethargy. His GP made a diagnosis of sinusitis and gave him a course of antibiotics. He did not improve and developed breathlessness, cough and chest pain. He had previously been fit and his only past medical history was of an inguinal hernia repair 10 years previously. He worked in a shop. He smoked 10 cigarettes a day and drank about 10 units of alcohol a week. He was taking no regular medication.

On examination he looked unwell and pale. Observations: respiratory rate 34/min, BP 140/85 mmHg, pulse 120 bpm, temperature 36.6°C. He had crusting of his nasal septum. His JVP was not elevated, and heart sounds were normal. Auscultation of his chest revealed fine crackles bilaterally. His abdominal and neurological examinations were unremarkable.

Urinalysis:

Protein	++
Blood	++
Nitrites	-
Leucocytes	-
Bilirubin	-

Investigations reveal;

Hb	8.1 g/dl
WBC	6.3 x10^9/l
MCV	81 fl
Platelets	510 x10^9/l
ESR	114 mm/1st hour
CRP	45 mg/l
Na^+	142 mmol/l
K^+	5.9 mmol/l
Urea	21 mmol/l
Creatinine	341 micromol/l
Bilirubin	18 micromol/l
AST	31 U/l
ALP	191 U/l
Albumin	34 g/l

Spirometry:

FEV1	72% predicted
FVC	77% predicted
KCO	122% predicted

His CXR is shown below.

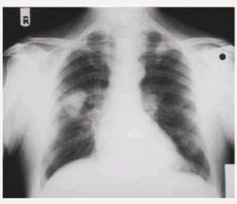

What is the most likely diagnosis?

A	Granulomatosis with polyangiitis
B	Microscopic polyangiitis
C	Goodpasture's syndrome/anti-GBM disease
D	Pulmonary oedema
E	*Legionella pneumophila*

70088

Submit

Previous Question | Skip Question

Calculator

Normal Values

© Pastest 2017

A 56-year-old man presented to his GP with a 4-week history of feeling generally unwell. He described nasal congestion, with pain under his left eye, flu-like symptoms and lethargy. His GP made a diagnosis of sinusitis and gave him a course of antibiotics. He did not improve and developed breathlessness, cough and chest pain. He had previously been fit and his only past medical history was of an inguinal hernia repair 10 years previously. He worked in a shop. He smoked 10 cigarettes a day and drank about 10 units of alcohol a week. He was taking no regular medication.

On examination he looked unwell and pale. Observations: respiratory rate 34/min, BP 140/85 mmHg, pulse 120 bpm, temperature 36.6°C. He had crusting of his nasal septum. His JVP was not elevated, and heart sounds were normal. Auscultation of his chest revealed fine crackles bilaterally. His abdominal and neurological examinations were unremarkable.

Urinalysis:

Protein	++
Blood	++
Nitrites	-
Leucocytes	-
Bilirubin	-

Investigations reveal;

Hb	8.1 g/dl
WBC	6.3 $x10^9$/l
MCV	81 fl
Platelets	510 $x10^9$/l
ESR	114 mm/1st hour
CRP	45 mg/l
Na^+	142 mmol/l
K^+	5.9 mmol/l
Urea	21 mmol/l
Creatinine	341 micromol/l
Bilirubin	18 micromol/l
AST	31 U/l
ALP	191 U/l
Albumin	34 g/l

Spirometry:

FEV1	72% predicted
FVC	77% predicted
KCO	122% predicted

His CXR is shown below.

What is the most likely diagnosis?

A	Granulomatosis with polyangiitis
B	Microscopic polyangiitis
C	Goodpasture's syndrome/anti-GBM disease
D	Pulmonary oedema
E	*Legionella pneumophila*

Explanation

A	Granulomatosis with polyangiitis

This is a question about pulmonary-renal syndromes (for a list see below).
The raised TLCO and the CXR should make one think of pulmonary haemorrhage. This should narrow the diagnosis down to a vasculitis, Goodpasture syndrome and SLE.

This patient has granulomatosis with polyangiitis (previously known as Wegener's granulomatosis). The clinical diagnosis is made by the triad of upper respiratory tract (nasal polyps and sinusitis), lower respiratory tract and renal involvement. It is a small-vessel vasculitis associated with granulomas.

The diagnosis of granulomatosis with polyangiitisis is suggested by a positive c-ANCA with the presence of an antibody to proteinase-3. The chest radiograph usually shows single or multiple nodules, fixed infiltrates or cavities. Pleural effusions and pulmonary infiltrates may also been seen. Diagnosis is usually confirmed with a biopsy. If untreated the median survival is just 5 months. Treatment is with intravenous cyclophosphamide and prednisolone, which reduces mortality to approximately 10%. Plasmapheresis would be first-line treatment if the disease was primarily renal.

Causes of pulmonary-renal syndromes:

- Systemic diseases:
  Granulomatosis with polyangiitis
  Microscopic polyangiitis
  Goodpasture syndrome
  Systemic lupus erythematosus
  Polyarteritis nodosa
  Henoch–Schönlein purpura
  Churg–Strauss syndrome (renal involvement less common)
- Primary pulmonary disease:
  Legionella pneumonia and interstitial nephritis
  Bacterial pneumonia with renal compromise secondary to sepsis
- Others:
  Pulmonary oedema with acute renal failure
  Uraemic pneumonitis
  Right-sided bacterial endocarditis – may cause pulmonary embolic lesions and glomerulonephritis
  Iatrogenic glomerulonephritis with ciprofloxacin, e.g. in patients given ciprofloxacin for cystic fibrosis.

B	Microscopic polyangiitis

Microscopic polyangiitis is characterised by a very similar small-vessel vasculitis, but without granuloma formation and involvement of the upper respiratory tract.

C	Goodpasture's syndrome/anti-GBM disease

Goodpasture syndrome can present with haemoptysis, although it is not associated with midline sinusitis. It's important to differentiate from microscopic polyangiitis with granuloma formation, because only anti-GBM disease responds to plasma exchange.

D	Pulmonary oedema

Pulmonary oedema is the least likely diagnosis, as the JVP is not elevated and the KCO would be reduced.

E	*Legionella pneumophila*

Legionella pneumonia is unlikely as he is afebrile and there is no evidence of foreign travel or exposure. In addition, this does not have a predilection for the upper respiratory tract.

70088

Rate this question:

Next Question

Previous Question | Tag Question

Feedback | End Session

Difficulty: Average

Peer Responses %

Session Progress

Responses Correct:	0
Responses Incorrect:	204
Responses Total:	204
Responses - % Correct:	0%

© Pastest 2017

A 56-year-old man presented to his GP with a 4-week history of feeling generally unwell. He described nasal congestion, with pain under his left eye, flu-like symptoms and lethargy. His GP made a diagnosis of sinusitis and gave him a course of antibiotics. He did not improve and developed breathlessness, cough and chest pain. He had previously been fit and his only past medical history was of an inguinal hernia repair 10 years previously. He worked in a shop. He smoked 10 cigarettes a day and drank about 10 units of alcohol a week. He was taking no regular medication.

On examination he looked unwell and pale. Observations: respiratory rate 34/min, BP 140/85 mmHg, pulse 120 bpm, temperature 36.6°C. He had crusting of his nasal septum. His JVP was not elevated, and heart sounds were normal. Auscultation of his chest revealed fine crackles bilaterally. His abdominal and neurological examinations were unremarkable.

Urinalysis:

Protein	++
Blood	++
Nitrites	-
Leucocytes	-
Bilirubin	-

Haematology:

Hb	8.1 g/dl
WBC	6.3 x10^9/l
MCV	81 fl
Platelets	510 x10^9/l
ESR	114 mm/1st hour
CRP	45 mg/l
Na^+	142 mmol/l
K^+	5.9 mmol/l
Urea	21 mmol/l
Creatinine	341 micromol/l
Bilirubin	18 micromol/l
AST	31 U/l
ALP	191 U/l
Albumin	34 g/l

Spirometry:

FEV1	72% predicted
FVC	77% predicted
KCO	122% predicted

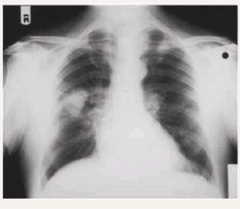

Which investigation would help make a diagnosis?

A	c-ANCA (anti-proteinase 3)
B	Anti-GBM antibodies
C	p-ANCA (anti-myeloperoxidase)
D	*Legionella* antigen
E	Echocardiogram

70089

Submit

Previous Question | Skip Question

Calculator

Normal Values

© Pastest 2017

A 56-year-old man presented to his GP with a 4-week history of feeling generally unwell. He described nasal congestion, with pain under his left eye, flu-like symptoms and lethargy. His GP made a diagnosis of sinusitis and gave him a course of antibiotics. He did not improve and developed breathlessness, cough and chest pain. He had previously been fit and his only past medical history was of an inguinal hernia repair 10 years previously. He worked in a shop. He smoked 10 cigarettes a day and drank about 10 units of alcohol a week. He was taking no regular medication.

On examination he looked unwell and pale. Observations: respiratory rate 34/min, BP 140/85 mmHg, pulse 120 bpm, temperature 36.6°C. He had crusting of his nasal septum. His JVP was not elevated, and heart sounds were normal. Auscultation of his chest revealed fine crackles bilaterally. His abdominal and neurological examinations were unremarkable.

Urinalysis:

Protein	++
Blood	++
Nitrites	-
Leucocytes	-
Bilirubin	-

Haematology:

Hb	8.1 g/dl
WBC	6.3 x10^9/l
MCV	81 fl
Platelets	510 x10^9/l
ESR	114 mm/1st hour
CRP	45 mg/l
Na^+	142 mmol/l
K^+	5.9 mmol/l
Urea	21 mmol/l
Creatinine	341 micromol/l
Bilirubin	18 micromol/l
AST	31 U/l
ALP	191 U/l
Albumin	34 g/l

Spirometry:

FEV1	72% predicted
FVC	77% predicted
KCO	122% predicted



Which investigation would help make a diagnosis?

A	c-ANCA (anti-proteinase 3)
B	Anti-GBM antibodies
C	p-ANCA (anti-myeloperoxidase)
D	*Legionella* antigen
E	Echocardiogram

Explanation

A	c-ANCA (anti-proteinase 3)

This is a question about pulmonary–renal syndromes (for a list see below).
The raised TLCO and the CXR should make one think of pulmonary haemorrhage. This should narrow the diagnosis down to a vasculitis, Goodpasture's syndrome and SLE.

This patient has granulomatosis with polyangiitis (previously known as Wegener's granulomatosis). The clinical diagnosis is made by the triad of upper respiratory tract (nasal polyps and sinusitis), lower respiratory tract and renal involvement. It is a small-vessel vasculitis associated with granulomas.

The diagnosis of granulomatosis with polyangiitisis is suggested by a positive c-ANCA with the presence of an antibody to proteinase-3. The chest radiograph usually shows single or multiple nodules, fixed infiltrates or cavities. Pleural effusions and pulmonary infiltrates may also been seen. Diagnosis is usually confirmed with a biopsy. If untreated the median survival is just 5 months. Treatment is with intravenous cyclophosphamide and prednisolone, which reduces mortality to approximately 10%. Plasmapheresis would be first-line treatment if the disease was primarily renal.

Causes of pulmonary–renal syndromes:

- Systemic diseases:
  Granulomatosis with polyangiitis
  Microscopic polyangiitis
  Goodpasture syndrome
  Systemic lupus erythematosus
  Polyarteritis nodosa
  Henoch–Schönlein purpura
  Churg–Strauss syndrome (renal involvement less common)
- Primary pulmonary disease:
  Legionella pneumonia and interstitial nephritis
  Bacterial pneumonia with renal compromise secondary to sepsis
- Others:
  Pulmonary oedema with acute renal failure
  Uraemic pneumonitis
  Right-sided bacterial endocarditis – may cause pulmonary embolic lesions and glomerulonephritis
  Iatrogenic glomerulonephritis with ciprofloxacin, e.g. in patients given ciprofloxacin for cystic fibrosis.

B	Anti-GBM antibodies

Anti-GBM antibodies are seen in Goodpasture syndrome, which isn't associated with sinusitis; this drives us away from anti-GBM as the cause of this patient's symptoms.

C	p-ANCA (anti-myeloperoxidase)

p-ANCA is associated with microscopic polyangiitis, which isn't associated with respiratory disease. Churg–Strauss can be associated with positive p-ANCA, although it wouldn't fit here as it's associated with eosinophilia and asthma symptoms.

D	*Legionella* antigen

This may be positive in *Legionella* pneumonia, but the subacute course of this patient's symptoms counts against Legionnaire's disease as the underlying diagnosis.

E	Echocardiogram

An echocardiogram would not show diagnostic features to confirm diagnosis of granulomatosis with polyangiitis. It would be of most value if left ventricular failure, rather than pulmonary infiltration, was suspected.

70089

Rate this question:

Next Question

Previous Question | Tag Question
Feedback | End Session

Difficulty: Average

Peer Responses %

Session Progress

Responses Correct:	0
Responses Incorrect:	205
Responses Total:	205
Responses - % Correct:	0%

© Pastest 2017

A 56-year-old man presented to his GP with a 4-week history of feeling generally unwell. He described nasal congestion, with pain under his left eye, flu-like symptoms and lethargy. His GP made a diagnosis of sinusitis and gave him a course of antibiotics. He did not improve and developed breathlessness, cough and chest pain. He had previously been fit and his only past medical history was of an inguinal hernia repair 10 years previously. He worked in a shop. He smoked 10 cigarettes a day and drank about 10 units of alcohol a week. He was taking no regular medication.

On examination he looked unwell and pale. Observations: respiratory rate 34/min, BP 140/85 mmHg, pulse 120 bpm, temperature 36.6°C. He had crusting of his nasal septum. His JVP was not elevated, and heart sounds were normal. Auscultation of his chest revealed fine crackles bilaterally. His abdominal and neurological examinations were unremarkable.

Urinalysis:

Protein	++
Blood	++
Nitrites	-
Leucocytes	-
Bilirubin	-

Haematology:

Hb	8.1 g/dl
WBC	6.3 x10^9/l
MCV	81 fl
Platelets	510 x10^9/l
ESR	114 mm/1st hour
CRP	45 mg/l
Na^+	142 mmol/l
K^+	5.9 mmol/l
Urea	21 mmol/l
Creatinine	341 micromol/l
Bilirubin	18 micromol/l
AST	31 U/l
ALP	191 U/l
Albumin	34 g/l

Spirometry:

FEV1	72% predicted
FVC	77% predicted
KCO	122% predicted

His CXR is shown below:

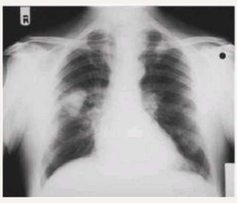

How would you treat this patient?

A	Intravenous antibiotics
B	Intravenous diuretics
C	Cyclophosphamide and prednisolone
D	Methylprednisolone and Methotrexate
E	Plasma exchange

70090

Submit

Previous Question | Skip Question

Calculator

Normal Values

© Pastest 2017

A 56-year-old man presented to his GP with a 4-week history of feeling generally unwell. He described nasal congestion, with pain under his left eye, flu-like symptoms and lethargy. His GP made a diagnosis of sinusitis and gave him a course of antibiotics. He did not improve and developed breathlessness, cough and chest pain. He had previously been fit and his only past medical history was of an inguinal hernia repair 10 years previously. He worked in a shop. He smoked 10 cigarettes a day and drank about 10 units of alcohol a week. He was taking no regular medication.

On examination he looked unwell and pale. Observations: respiratory rate 34/min, BP 140/85 mmHg, pulse 120 bpm, temperature 36.6°C. He had crusting of his nasal septum. His JVP was not elevated, and heart sounds were normal. Auscultation of his chest revealed fine crackles bilaterally. His abdominal and neurological examinations were unremarkable.

Urinalysis:

Protein	++
Blood	++
Nitrites	-
Leucocytes	-
Bilirubin	-

Haematology:

Hb	8.1 g/dl
WBC	6.3 $x10^9$/l
MCV	81 fl
Platelets	510 $x10^9$/l
ESR	114 mm/1st hour
CRP	45 mg/l
Na^+	142 mmol/l
K^+	5.9 mmol/l
Urea	21 mmol/l
Creatinine	341 micromol/l
Bilirubin	18 micromol/l
AST	31 U/l
ALP	191 U/l
Albumin	34 g/l

Spirometry:

FEV1	72% predicted
FVC	77% predicted
KCO	122% predicted

His CXR is shown below:

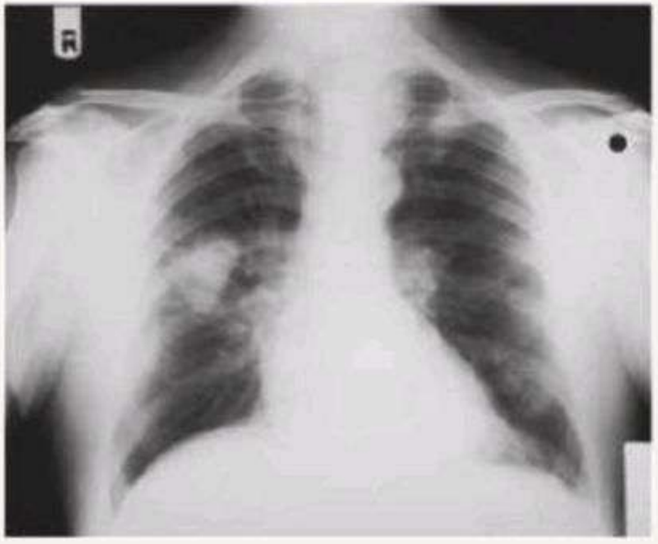

How would you treat this patient?

A	Intravenous antibiotics
B	Intravenous diuretics
C	Cyclophosphamide and prednisolone
D	Methylprednisolone and Methotrexate
E	Plasma exchange

Explanation

C	Cyclophosphamide and prednisolone

This is a question about pulmonary–renal syndromes (for a list see below).

The raised TLCO and the CXR should make one think of pulmonary haemorrhage. This should narrow the diagnosis down to a vasculitis, Goodpasture syndrome and SLE.

This patient has granulomatosis with polyangiitis (previously known as Wegener's granulomatosis). The clinical diagnosis is made by the triad of upper respiratory tract (nasal polyps and sinusitis), lower respiratory tract and renal involvement. It is a small-vessel vasculitis associated with granulomas.

First-line immunosuppressive therapy is with cyclophosphamide and prednisolone.

Causes of pulmonary–renal syndromes:

- Systemic diseases:
  Granulomatosis with polyangiitis
  Microscopic polyangiitis
  Goodpasture syndrome
  Systemic lupus erythematosus
  Polyarteritis nodosa
  Henoch–Schönlein purpura
  Churg–Strauss syndrome (renal involvement less common)
- Primary pulmonary disease:
  Legionella pneumonia and interstitial nephritis
  Bacterial pneumonia with renal compromise secondary to sepsis
- Others:
  Pulmonary oedema with acute renal failure
  Uraemic pneumonitis
  Right-sided bacterial endocarditis – may cause pulmonary embolic lesions and glomerulonephritis
  Iatrogenic glomerulonephritis with ciprofloxacin, e.g. in patients given ciprofloxacin for cystic fibrosis.

A	Intravenous antibiotics

This would be an appropriate treatment for severe pneumonia or sepsis.

B	Intravenous diuretics

This would be appropriate for acute pulmonary oedema.

D	Methylprednisolone and Methotrexate

This combination may be considered as initial treatment for non-organ or life-threatening granulomatosis with polyangiitis. This gentleman is clearly very unwell and has renal involvement.

E	Plasma exchange

This is not of value in treating microscopic polyangiitis with granuloma formation. Studies suggest it only has utility in treating those with anti-GBM disease.

70090

Rate this question:

Next Question

Previous Question | Tag Question

Feedback | End Session

Difficulty: Average

Peer Responses %

Session Progress

Responses Correct:	0
Responses Incorrect:	206
Responses Total:	206
Responses - % Correct:	0%

© Pastest 2017

A 39-year-old man presented to his GP with a 3-month history of fever, rhinitis and weight loss. Two weeks ago he had an exacerbation of asthma and was treated with a course of erythromycin. He also complained of weakness in his hands and legs. He has a past medical history of angina. He is an ex-smoker and stopped 5 years ago.

On examination he has a rash on his shins, shown below.

Auscultation of his chest reveals a mild expiratory wheeze. Examination was otherwise unremarkable. Urinalysis was normal.

Investigations:

Hb	12.1 g/dl
MCV	84 fl
WCC	9.4 $x10^9$/l
Neutrophils	5.3 $x10^9$/l
Lymphocytes	1.8 $x10^9$/l
Monocytes	0.3 $x10^9$/l
Basophils	0.08 $x10^9$/l
PLT	411 $x10^9$/l
ESR	82 mm/1st hour
Na^+	138 mmol/l
K^+	4.2 mmol/l
Urea	4.1 mmol/l
Creatinine	111 micromol/l

What is the diagnosis?

A	Microscopic polyangiitis
B	Granulomatosis with polyangiitis
C	Eosinophilic pneumonia secondary to erythromycin
D	Churg Strauss syndrome
E	Allergic bronchopulmonary aspergillosis

70091

Submit

Previous Question | Skip Question

Calculator

Normal Values

© Pastest 2017

A 39-year-old man presented to his GP with a 3-month history of fever, rhinitis and weight loss. Two weeks ago he had an exacerbation of asthma and was treated with a course of erythromycin. He also complained of weakness in his hands and legs. He has a past medical history of angina. He is an ex-smoker and stopped 5 years ago.

On examination he has a rash on his shins, shown below.

Auscultation of his chest reveals a mild expiratory wheeze. Examination was otherwise unremarkable. Urinalysis was normal.

Investigations:

Hb	12.1 g/dl
MCV	84 fl
WCC	9.4 $x10^9$/l
Neutrophils	5.3 $x10^9$/l
Lymphocytes	1.8 $x10^9$/l
Monocytes	0.3 $x10^9$/l
Basophils	0.08 $x10^9$/l
PLT	411 $x10^9$/l
ESR	82 mm/1st hour
Na^+	138 mmol/l
K^+	4.2 mmol/l
Urea	4.1 mmol/l
Creatinine	111 micromol/l

What is the diagnosis?

A	Microscopic polyangiitis
B	Granulomatosis with polyangiitis
C	Eosinophilic pneumonia secondary to erythromycin
D	Churg Strauss syndrome
E	Allergic bronchopulmonary aspergillosis

Explanation

D	Churg Strauss syndrome

The patient has systemic symptoms, asthma, eosinophils >1.5 × 10^9/l and evidence of vasculitis in two or more non-lung organs (Lanham's criteria):

- Cutaneous vasculitis (see picture)
- Mononeuritis multiplex
- A cardiac history.

The American Criteria of Rheumatology require four out of six of the following to be present for a diagnosis of Churg–Strauss syndrome:

- The presence of asthma
- Eosinophils >10% in the peripheral blood
- Evidence of a neuropathy in a vasculitic pattern, e.g. mononeuritis multiplex
- Transient pulmonary infiltrates
- A history of sinus disease
- Evidence of intravascular eosinophils on biopsy.

Renal involvement in Churg–Strauss syndrome is very rare.

A	Microscopic polyangiitis

Microscopic polyangiitis is associated with renal disease. The absence of any evidence of glomerulonephritis counts against this as the underlying diagnosis.

B	Granulomatosis with polyangiitis

Granulomatosis with polyangiitis is associated with glomerulonephritis, which has not been demonstrated here.

C	Eosinophilic pneumonia secondary to erythromycin

The symptoms preceded erythromycin administration, making eosinophilic pneumonia unlikely.

E	Allergic bronchopulmonary aspergillosis

Allergic bronchopulmonary aspergillosis usually occurs in asthmatics, but would not produce the signs and symptoms of vasculitis as in this patient, including the obvious skin lesions.

70091

Rate this question:

Next Question

Previous Question | Tag Question

Feedback | End Session

Difficulty: Average

Peer Responses %

Session Progress

Responses Correct:	0
Responses Incorrect:	207
Responses Total:	207
Responses - % Correct:	0%

© Pastest 2017

A 39-year-old man presented to his GP with a 3-month history of fever, rhinitis and weight loss. Two weeks ago he had an exacerbation of asthma and was treated with a course of erythromycin. He also complained of weakness in his hands and legs. He has a past medical history of angina. He is an ex-smoker and stopped 5 years ago.

On examination he has a rash on his shins, shown below.

Auscultation of his chest reveals a mild expiratory wheeze. Examination was otherwise unremarkable. Urinalysis was normal.

Investigations:

Hb	12.1 g/dl
WCC	9.4 × 10^9/l
PLT	411 × 10^9/l
Na+	138 mmol/l
K+	4.2 mmol/l
Creatinine	111 mol/l
MCV	84 fl
Neutrophils	5.3 x10^9/l
Lymphocytes	1.8 x10^9/l
Monocytes	0.3 x10^9/l
Basophils	0.08 x10^9/l
ESR	82 mm/1st h
Urea	4.1 mmol/l
Urine	Blood –, protein –

Which investigation would help confirm the diagnosis?

A	c-ANCA, proteinase 3 antibody positive
B	c-ANCA, myeloperoxidase antibody positive
C	p-ANCA, proteinase 3 antibody positive
D	p-ANCA, myeloperoxidase antibody positive
E	*Aspergillus* serology

70092

Submit

Previous Question | Skip Question

Calculator

Normal Values

© Pastest 2017

A 39-year-old man presented to his GP with a 3-month history of fever, rhinitis and weight loss. Two weeks ago he had an exacerbation of asthma and was treated with a course of erythromycin. He also complained of weakness in his hands and legs. He has a past medical history of angina. He is an ex-smoker and stopped 5 years ago.

On examination he has a rash on his shins, shown below.

Auscultation of his chest reveals a mild expiratory wheeze. Examination was otherwise unremarkable. Urinalysis was normal.

Investigations:

Hb	12.1 g/dl
WCC	9.4 × 10^9/l
PLT	411 × 10^9/l
Na+	138 mmol/l
K+	4.2 mmol/l
Creatinine	111 mol/l
MCV	84 fl
Neutrophils	5.3 x10^9/l
Lymphocytes	1.8 x10^9/l
Monocytes	0.3 x10^9/l
Basophils	0.08 x10^9/l
ESR	82 mm/1st h
Urea	4.1 mmol/l
Urine	Blood –, protein –

Which investigation would help confirm the diagnosis?

A	c-ANCA, proteinase 3 antibody positive
B	c-ANCA, myeloperoxidase antibody positive
C	p-ANCA, proteinase 3 antibody positive
D	p-ANCA, myeloperoxidase antibody positive
E	*Aspergillus* serology

Explanation

D p-ANCA, myeloperoxidase antibody positive

This patient has Churg–Strauss syndrome with systemic symptoms: asthma, eosinophils >1.5 × 10^9/l and evidence of vasculitis in two or more non-lung organs (Lanham's criteria):

- Cutaneous vasculitis (see picture)
- Mononeuritis multiplex
- A cardiac history.

The American Criteria of Rheumatology require four out of six of the following to be present for a diagnosis of Churg–Strauss syndrome:

- The presence of asthma
- Eosinophils >10% in the peripheral blood
- Evidence of a neuropathy in a vasculitic pattern, e.g. mononeuritis multiplex
- Transient pulmonary infiltrates
- A history of sinus disease
- Evidence of intravascular eosinophils on biopsy.

Renal involvement in Churg–Strauss syndrome is very rare.

A c-ANCA, proteinase 3 antibody positive

c-ANCA, proteinase 3 antibody positive is associated with granulomatosis with polyangiitis

B c-ANCA, myeloperoxidase antibody positive

c-ANCA, myeloperoxidase antibody positive is not usually seen as a combination of positive tests.

C p-ANCA, proteinase 3 antibody positive

p-ANCA, proteinase 3 antibody positive is not usually seen as a combination of positive tests.

E *Aspergillus* serology

Aspergillus serology is used to diagnose *Aspergillus* lung disease, which would be inconsistent with the features of cutaneous vasculitis seen here.

70092

Rate this question:

Next Question

Previous Question | Tag Question

Feedback | End Session

Difficulty: Average

Peer Responses %

Session Progress

Responses Correct:	0
Responses Incorrect:	208
Responses Total:	208
Responses - % Correct:	0%

© Pastest 2017

A 55-year-old asthmatic patient presented in December with increasing cough and wheeze. She described a cough productive of brown sputum. She had no other past medical history. She was taking a steroid inhaler regularly and increasing doses of beta-agonist with no alleviation of her symptoms. She worked in a bakery for many years. She is an ex-smoker and stopped smoking 20 years ago. She has a dog at home.

On examination she had a temperature of 38°C. She was breathless at rest. She had reduced expansion anteriorly on the left side, with corresponding reduced breath sounds. She had a mild expiratory wheeze.

Investigations:

Hb	14.1 g/dl
WCC	12.7 $x10^9$/l
Neutrophils	7.37 $x10^9$/l
Lymphocytes	2.55 $x10^9$/l
Monocytes	0.6 $x10^9$/l
Basophils	0.05 $x10^9$/l
MCV	87.3 fl
Platelets	314 $x10^9$/l
ESR	28 mm/1st hour
CRP	16 mg/l
Na^+	138 mmol/l
K^+	4.9 mmol/l
Urea	4.8 mmol/l
Creatinine	95 micromol/l
Bilirubin	12 micromol/l
ALT	49 U/l
ALP	61 U/l
Albumin	36 g/l

CXR on presentation is shown below.

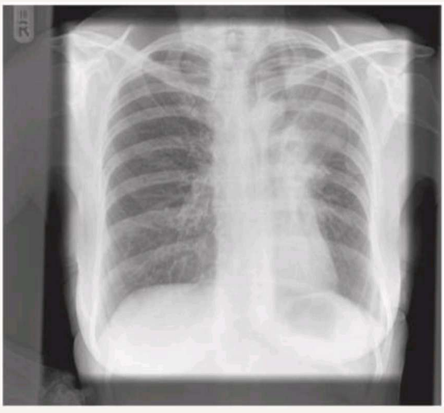

What does the CXR show?

A	Left upper lobe consolidation
B	Left upper lobe collapse
C	Left lower lobe collapse
D	Left lower lobe consolidation
E	Lingular consolidation

70093

Submit

Previous Question | Skip Question

Calculator

Normal Values

© Pastest 2017

A 55-year-old asthmatic patient presented in December with increasing cough and wheeze. She described a cough productive of brown sputum. She had no other past medical history. She was taking a steroid inhaler regularly and increasing doses of beta-agonist with no alleviation of her symptoms. She worked in a bakery for many years. She is an ex-smoker and stopped smoking 20 years ago. She has a dog at home.

On examination she had a temperature of 38°C. She was breathless at rest. She had reduced expansion anteriorly on the left side, with corresponding reduced breath sounds. She had a mild expiratory wheeze.

Investigations:

Hb	14.1 g/dl
WCC	12.7 $x10^9$/l
Neutrophils	7.37 $x10^9$/l
Lymphocytes	2.55 $x10^9$/l
Monocytes	0.6 $x10^9$/l
Basophils	0.05 $x10^9$/l
MCV	87.3 fl
Platelets	314 $x10^9$/l
ESR	28 mm/1st hour
CRP	16 mg/l
Na^+	138 mmol/l
K^+	4.9 mmol/l
Urea	4.8 mmol/l
Creatinine	95 micromol/l
Bilirubin	12 micromol/l
ALT	49 U/l
ALP	61 U/l
Albumin	36 g/l

CXR on presentation is shown below.

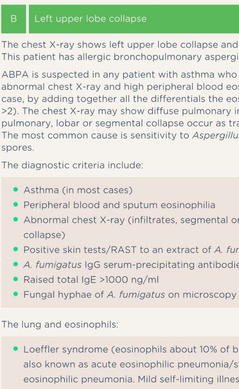

What does the CXR show?

A	Left upper lobe consolidation
B	Left upper lobe collapse
C	Left lower lobe collapse
D	Left lower lobe consolidation
E	Lingular consolidation

Explanation

B	Left upper lobe collapse

The chest X-ray shows left upper lobe collapse and the 'veil sign'. This patient has allergic bronchopulmonary aspergillosis (ABPA).

ABPA is suspected in any patient with asthma who has an abnormal chest X-ray and high peripheral blood eosinophilia (in this case, by adding together all the differentials the eosinophil count is >2). The chest X-ray may show diffuse pulmonary infiltrates, and pulmonary, lobar or segmental collapse occur as transient features. The most common cause is sensitivity to *Aspergillus fumigatus* spores.

The diagnostic criteria include:

- Asthma (in most cases)
- Peripheral blood and sputum eosinophilia
- Abnormal chest X-ray (infiltrates, segmental or lobar collapse)
- Positive skin tests/RAST to an extract of *A. fumigatus*
- *A. fumigatus* IgG serum-precipitating antibodies
- Raised total IgE >1000 ng/ml
- Fungal hyphae of *A. fumigatus* on microscopy of sputum.

The lung and eosinophils:

- Loeffler syndrome (eosinophils about 10% of blood WCC), also known as acute eosinophilic pneumonia/simple eosinophilic pneumonia. Mild self-limiting illness with transient migratory pulmonary shadows. Associated with parasitic infections, drug allergies and exposure to inorganic chemicals
- Tropical pulmonary eosinophilia (eosinophils >20%) – in tropical countries usually due to migrating larvae of the filarial worms *Wucheria bancrofti* and *Brugia malayi*
- Chronic/prolonged pulmonary eosinophilia (eosinophils >20%) – eosinophilic pneumonia persisting for more than one month. Chronic debilitating illness characterised by malaise, weight loss, fever and dyspnoea
- Allergic bronchopulmonary aspergillosis (eosinophils 5–20%) as in this case
- Churg–Strauss syndrome (eosinophils 5–20%) associated with asthma
- Hyper-eosinophilic syndrome (eosinophils >20%; eosinophilic infiltrations of various organs – e.g. lungs, heart, bone marrow. Can be associated with an eosinophilic arteritis
- External agents – drugs, toxins, parasitic infection.

A	Left upper lobe consolidation

There is no left upper lobe consolidation in the chest radiograph. The left lung appears more opaque due to left upper lobe collapse.

C	Left lower lobe collapse

Left lower lobe collapse presents as 'sail sign', a triangular opacification visualised behind the cardiac shadow.

D	Left lower lobe consolidation

There is no evidence of left lower lobe consolidation and the left hemi-diaphragm is clearly visualised.

E	Lingular consolidation

The left cardiac border is clear, making linguar lobe consolidation unlikely.

70093

Rate this question:

Next Question

Previous Question | Tag Question

Feedback | End Session

Difficulty: Average

Peer Responses %

Session Progress

Responses Correct:	0
Responses Incorrect:	209
Responses Total:	209
Responses - % Correct:	0%

Blog About Pastest Contact Us Help

© Pastest 2017

A 55-year-old asthmatic patient presented in December with increasing cough and wheeze. She described a cough productive of brown sputum. She had no other past medical history. She was taking a steroid inhaler regularly and increasing doses of beta-agonist with no alleviation of her symptoms. She worked in a bakery for many years. She is an ex-smoker and stopped smoking 20 years ago. She has a dog at home.

On examination she had a temperature of 38°C. She was breathless at rest. She had reduced expansion anteriorly on the left side, with corresponding reduced breath sounds. She had a mild expiratory wheeze.

Investigations:

Hb	14.1 g/dl
WCC	12.7 $x10^9$/l
Neutrophils	7.37 $x10^9$/l
Lymphocytes	2.55 $x10^9$/l
Monocytes	0.6 $x10^9$/l
Basophils	0.05 $x10^9$/l
MCV	87.3 fl
Platelets	314 $x10^9$/l
ESR	28 mm/1st hour
CRP	16 mg/l
Na^+	138 mmol/l
K^+	4.9 mmol/l
Urea	4.8 mmol/l
Creatinine	95 micromol/l
Bilirubin	12 micromol/l
ALT	49 U/l
ALP	61 U/l
Albumin	36 g/l

CXR on presentation is shown below.

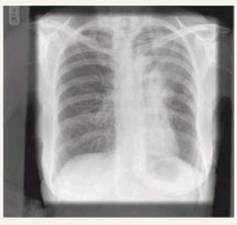

CXR taken one month later.

What is the diagnosis?

A	Occupational asthma
B	Exacerbation of asthma
C	Allergic bronchopulmonary aspergillosis
D	Churg-Strauss syndrome
E	Loeffler syndrome

70094

Submit

Previous Question | Skip Question

Calculator

Normal Values

© Pastest 2017

A 55-year-old asthmatic patient presented in December with increasing cough and wheeze. She described a cough productive of brown sputum. She had no other past medical history. She was taking a steroid inhaler regularly and increasing doses of beta-agonist with no alleviation of her symptoms. She worked in a bakery for many years. She is an ex-smoker and stopped smoking 20 years ago. She has a dog at home.

On examination she had a temperature of 38°C. She was breathless at rest. She had reduced expansion anteriorly on the left side, with corresponding reduced breath sounds. She had a mild expiratory wheeze.

Investigations:

Hb	14.1 g/dl
WCC	12.7 $x10^9$/l
Neutrophils	7.37 $x10^9$/l
Lymphocytes	2.55 $x10^9$/l
Monocytes	0.6 $x10^9$/l
Basophils	0.05 $x10^9$/l
MCV	87.3 fl
Platelets	314 $x10^9$/l
ESR	28 mm/1st hour
CRP	16 mg/l
Na^+	138 mmol/l
K^+	4.9 mmol/l
Urea	4.8 mmol/l
Creatinine	95 micromol/l
Bilirubin	12 micromol/l
ALT	49 U/l
ALP	61 U/l
Albumin	36 g/l

CXR on presentation is shown below.

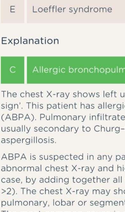

CXR taken one month later.

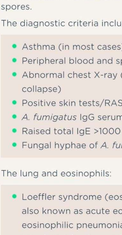

What is the diagnosis?

A	Occupational asthma
B	Exacerbation of asthma
C	Allergic bronchopulmonary aspergillosis
D	Churg-Strauss syndrome
E	Loeffler syndrome

Explanation

C Allergic bronchopulmonary aspergillosis

The chest X-ray shows left upper lobe collapse and also the 'veil sign'. This patient has allergic bronchopulmonary aspergillosis (ABPA). Pulmonary infiltrates, blood eosinophilia and asthma are usually secondary to Churg–Strauss or allergic bronchopulmonary aspergillosis.

ABPA is suspected in any patient with asthma who has an abnormal chest X-ray and high peripheral blood eosinophilia (in this case, by adding together all the differentials the eosinophil count is >2). The chest X-ray may show diffuse pulmonary infiltrates, and pulmonary, lobar or segmental collapse occur as transient features. The most common cause is sensitivity to *Aspergillus fumigatus* spores.

The diagnostic criteria include:

- Asthma (in most cases)
- Peripheral blood and sputum eosinophilia
- Abnormal chest X-ray (infiltrates, segmental or lobar collapse)
- Positive skin tests/RAST to an extract of *A. fumigatus*
- *A. fumigatus* IgG serum-precipitating antibodies
- Raised total IgE >1000 ng/ml
- Fungal hyphae of *A. fumigatus* on microscopy of sputum.

The lung and eosinophils:

- Loeffler syndrome (eosinophils about 10% of blood WCC), also known as acute eosinophilic pneumonia/simple eosinophilic pneumonia. Mild self-limiting illness with transient migratory pulmonary shadows. Associated with parasitic infections, drug allergies and exposure to inorganic chemicals
- Tropical pulmonary eosinophilia (eosinophils >20%) – in tropical countries usually due to migrating larvae of the filarial worms *Wucheria bancrofti* and *Brugia malayi*
- Chronic/prolonged pulmonary eosinophilia (eosinophils >20%) – eosinophilic pneumonia persisting for more than one month. Chronic debilitating illness characterised by malaise, weight loss, fever and dyspnoea
- Allergic bronchopulmonary aspergillosis (eosinophils 5–20%) as in this case
- Churg–Strauss syndrome (eosinophils 5–20%) associated with asthma
- Hyper-eosinophilic syndrome (eosinophils >20%: eosinophilic infiltrations of various organs – e.g. lungs, heart, bone marrow. Can be associated with an eosinophilic arteritis
- External agents – drugs, toxins, parasitic infection.

A Occupational asthma

The patient working as a baker is irrelevant – occupational asthma is unlikely to cause a productive cough or these chest X-ray features. It can be screened for using serial peak flow measurements and comparing those at home to those at work.

B Exacerbation of asthma

The chest radiograph features and clinical examination findings are not in keeping with an exacerbation of asthma.

D Churg-Strauss syndrome

This patient does not have the diagnostic criteria for Churg–Strauss syndrome. His eosinophil count is normal, which counts against this as the underlying cause.

E Loeffler syndrome

Loeffler syndrome is associated with fleeting pulmonary infiltrates but not with intermittent lobar collapse. It is associated with parasitic worm migration to the lungs. We're given no indication that this is a potential cause here.

700194

Rate this question:

Next Question

Previous Question | Tag Question

Feedback | End Session

Difficulty: Average

Peer Responses %

Session Progress

Responses Correct:	0
Responses Incorrect:	210
Responses Total:	210
Responses - % Correct:	0%

© Pastest 2017

A 55-year-old asthmatic patient presented in December with increasing cough and wheeze. She described a cough productive of brown sputum. She had no other past medical history. She was taking a steroid inhaler regularly and increasing doses of beta-agonist with no alleviation of her symptoms. She worked in a bakery for many years. She is an ex-smoker and stopped smoking 20 years ago. She has a dog at home.

On examination she had a temperature of 38°C. She was breathless at rest. She had reduced expansion anteriorly on the left side, with corresponding reduced breath sounds. She had a mild expiratory wheeze.

Investigations;

Hb	14.1 g/dl
WCC	12.7 $x10^9$/l
Neutrophils	7.37 $x10^9$/l
Lymphocytes	2.55 $x10^9$/l
Monocytes	0.6 $x10^9$/l
Basophils	0.05 $x10^9$/l
MCV	87.3 fl
Platelets	314 $x10^9$/l
ESR	28 mm/1st hour
CRP	16 mg/l
Na^+	138 mmol/l
K^+	4.9 mmol/l
Urea	4.8 mmol/l
Creatinine	95 micromol/l
Bilirubin	12 micromol/l
ALT	49 U/l
ALP	61 U/l
Albumin	36 g/l

CXR on presentation;

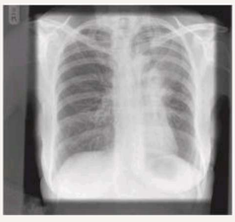

CXR taken one month later;

What investigation would help make a diagnosis?

A	p-ANCA
B	c-ANCA
C	Positive skin test/radioallergosorbent test for Aspergillus fumigatus
D	Metacholine challenge test
E	Lung function tests

70095

Submit

Previous Question | Skip Question

Calculator

Normal Values

© Pastest 2017

A 55-year-old asthmatic patient presented in December with increasing cough and wheeze. She described a cough productive of brown sputum. She had no other past medical history. She was taking a steroid inhaler regularly and increasing doses of beta-agonist with no alleviation of her symptoms. She worked in a bakery for many years. She is an ex-smoker and stopped smoking 20 years ago. She has a dog at home.

On examination she had a temperature of 38°C. She was breathless at rest. She had reduced expansion anteriorly on the left side, with corresponding reduced breath sounds. She had a mild expiratory wheeze.

Investigations;

Hb	14.1 g/dl
WCC	12.7 x10^9/l
Neutrophils	7.37 x10^9/l
Lymphocytes	2.55 x10^9/l
Monocytes	0.6 x10^9/l
Basophils	0.05 x10^9/l
MCV	87.3 fl
Platelets	314 x10^9/l
ESR	28 mm/1st hour
CRP	16 mg/l
Na$^+$	138 mmol/l
K$^+$	4.9 mmol/l
Urea	4.8 mmol/l
Creatinine	95 micromol/l
Bilirubin	12 micromol/l
ALT	49 U/l
ALP	61 U/l
Albumin	36 g/l

CXR on presentation;

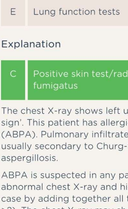

CXR taken one month later;

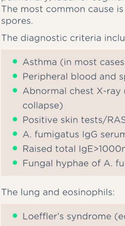

What investigation would help make a diagnosis?

A	p-ANCA
B	c-ANCA
C	Positive skin test/radioallergosorbent test for Aspergillus fumigatus
D	Metacholine challenge test
E	Lung function tests

Explanation

C Positive skin test/radioallergosorbent test for Aspergillus fumigatus

The chest X-ray shows left upper lobe collapse and shows the 'veil sign'. This patient has allergic bronchopulmonary aspergillosis (ABPA). Pulmonary infiltrates, blood eosinophilia and asthma is usually secondary to Churg-Strauss or allergic bronchopulmonary aspergillosis.

ABPA is suspected in any patient with asthma who has an abnormal chest X-ray and high peripheral blood eosinophilia (in this case by adding together all the differentials the eosinophil count is >2). The chest X-ray may show diffuse pulmonary infiltrates, and pulmonary, lobar or segmental collapse occur as transient features. The most common cause is sensitivity to Aspergillus fumigatus spores.

The diagnostic criteria include:

- Asthma (in most cases)
- Peripheral blood and sputum eosinophilia
- Abnormal chest X-ray (infiltrates, segmental or lobar collapse)
- Positive skin tests/RAST to an extract of A. fumigatus
- A. fumigatus IgG serum-precipitating antibodies
- Raised total IgE>1000ng/ml
- Fungal hyphae of A. fumigatus on microscopy of sputum

The lung and eosinophils:

- Loeffler's syndrome (eosinophils about 10% of blood WCC), also known as acute eosinophilic pneumonia/simple eosinophilic pneumonia. Mild self-limiting illness with transient migratory pulmonary shadows. Associated with parasitic infections, drug allergies and exposure to inorganic chemicals
- Tropical pulmonary eosinophilia (eosinophils more than 20%) – in tropical countries usually due to migrating larvae of the filarial worms Wucheria bancrofti and Brugia malayi
- Chronic/prolonged pulmonary eosinophilia (eosinophils>20%) – eosinophilic pneumonia persisting for more than one month. Chronic debilitating illness characterised by malaise, weight loss, fever and dyspnoea
- Allergic bronchopulmonary aspergillosis (eosinophils 5-20%) as in this case
- Churg-Strauss syndrome (eosinophils 5-20%) associated with asthma
- Hypereosinophilic syndrome (eosinophils>20% - eosinophilic infiltrations of various organs – e.g. lungs, heart, bone marrow. Can be associated with an eosinophilic arteritis
- External agents – drugs, toxins, parasitic infection

A p-ANCA

This is an appropriate test for vasculitis.

B c-ANCA

This is an appropriate tests for vasculitis.

D Metacholine challenge test

Metacholine challenge test is used to disgnose asthma.

E Lung function tests

Lung functions tests would not be discriminatory enough to diagnose allergic bronchopulmonary aspergillosis.

70099

Rate this question:

Next Question

Previous Question | Tag Question

Feedback | End Session

Difficulty: Average

Peer Responses %

Session Progress

Responses Correct:	0
Responses Incorrect:	211
Responses Total:	211
Responses - % Correct:	0%

© Pastest 2017

A 67-year-old non-smoker was referred to the Respiratory Consultant with a 3-month history of progressive shortness of breath. She was also complaining of a right-sided chest pain, which she described as a constant severe ache. She had lost about 5 kg in the last month and felt lethargic. She had initially put the symptoms down to the stress of recently being widowed. Her husband, who used to work as a plumber, died of a 'lung problem'. She has never worked outside the home, and has two daughters who are fit and well. On examination she looked unwell and was breathless at rest. Examination of her chest revealed reduced expansion, percussion note, vocal fremitus and breath sounds throughout the right hemithorax.

Investigations;

Hb	10.2 g/dl
WCC	10.8 x10^9/l
Platelets	471 x10^9/l
MCV	81 fl
ESR	69 mm/1st hour
CRP	44 mg/l
Na^+	136 mmol/l
K^+	3.7 mmol/l
Urea	6.6 mmol/l
Creatinine	77 micromol/l
Bilirubin	34 micromol/l
AST	21 U/l
ALP	97 U/l
Albumin	37 g/l

Her CXR is shown below;

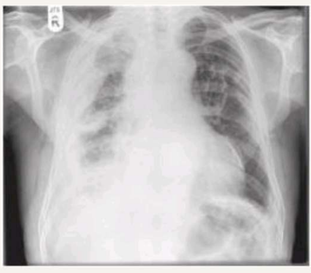

What is the most likely diagnosis?

A	Asbestosis
B	Squamous-cell carcinoma
C	Pleural adenocarcinoma
D	Mesothelioma
E	Metastatic adenocarcinoma

70096

Submit

Previous Question | Skip Question

Calculator

Normal Values

© Pastest 2017

A 67-year-old non-smoker was referred to the Respiratory Consultant with a 3-month history of progressive shortness of breath. She was also complaining of a right-sided chest pain, which she described as a constant severe ache. She had lost about 5 kg in the last month and felt lethargic. She had initially put the symptoms down to the stress of recently being widowed. Her husband, who used to work as a plumber, died of a 'lung problem'. She has never worked outside the home, and has two daughters who are fit and well. On examination she looked unwell and was breathless at rest. Examination of her chest revealed reduced expansion, percussion note, vocal fremitus and breath sounds throughout the right hemithorax.

Investigations;

Hb	10.2 g/dl
WCC	10.8 $x10^9$/l
Platelets	471 $x10^9$/l
MCV	81 fl
ESR	69 mm/1st hour
CRP	44 mg/l
Na^+	136 mmol/l
K^+	3.7 mmol/l
Urea	6.6 mmol/l
Creatinine	77 micromol/l
Bilirubin	34 micromol/l
AST	21 U/l
ALP	97 U/l
Albumin	37 g/l

Her CXR is shown below;

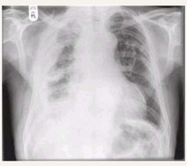

What is the most likely diagnosis?

A	Asbestosis
B	Squamous-cell carcinoma
C	Pleural adenocarcinoma
D	Mesothelioma
E	Metastatic adenocarcinoma

Explanation

D	Mesothelioma

The clue is in the question – her husband who has died worked as a plumber. She is a housewife (she has never worked outside the home), so it is assumed she washed her husband's overalls and was therefore exposed to asbestos. She has systemic symptoms as well as a pleural effusion, making the most likely diagnosis malignant mesothelioma.

Video-assisted thoracoscopy surgery is the investigation of choice as it has the highest diagnostic yield. Prophylactic radiotherapy should be given to the operation site.

The chest X-ray shows pleural thickening and an effusion on the right. There is a holly-leaf pleural plaque on the left (directly above the heart to the left of the aortic knuckle), consistent with previous asbestos exposure. Incidentally, there is pericardial calcification.

A	Asbestosis

Whilst the history is suggestive of an asbestos related pathology the history of right chest pain with radiographic evidence of significant pleural thickening is suggestive of mesothelioma with chest wall invasion.

B	Squamous-cell carcinoma

The lady is a non-smoker with a history to suggestive of asbestos exposure and the chest radiograph shows significantpleural thickening. All these factors make mesothelioma more likely than small cell lung cancer.

C	Pleural adenocarcinoma

This would be the main differential diagnosis but the probable history of asbestos exposure makes mesothelioma more likely.

E	Metastatic adenocarcinoma

Again, the history is suggestive of asbestos exposure and with the significant unilateral pleural thickening mesothelioma is the most likely diagnosis.

70096

Rate this question:

Next Question

Previous Question | Tag Question

Feedback | End Session

Difficulty: Average

Peer Responses %

Session Progress

Responses Correct:	0
Responses Incorrect:	212
Responses Total:	212
Responses - % Correct:	0%

© Pastest 2017

A 67-year-old non-smoker was referred to the Respiratory Consultant with a 3-month history of progressive shortness of breath. She was also complaining of a right-sided chest pain, which she described as a constant severe ache. She had lost about 5 kg in the last month and felt lethargic. She had initially put the symptoms down to the stress of recently being widowed. Her husband, who used to work as a plumber, died of a 'lung problem'. She has never worked outside the home, and has two daughters who are fit and well. On examination she looked unwell and was breathless at rest. Examination of her chest revealed reduced expansion, percussion note, vocal fremitus and breath sounds throughout the right hemithorax.

Investigations;

Hb	10.2 g/dl
WCC	10.8 $x10^9$/l
Platelets	471 $x10^9$/l
MCV	81 fl
ESR	69 mm/1st hour
CRP	44 mg/l
Na^+	136 mmol/l
K^+	3.7 mmol/l
Urea	6.6 mmol/l
Creatinine	77 micromol/l
Bilirubin	34 micromol/l
AST	21 U/l
ALP	97 U/l
Albumin	37 g/l

Her CXR is shown below;

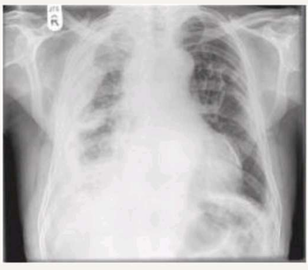

Which of the investigations is most likely to lead to a definitive diagnosis?

A	Video-assisted thoracoscopic surgery biopsy
B	CT chest
C	Chest drain and fluid sent for cytology
D	CT-guided percutaneous needle biopsy
E	Blind pleural biopsy with an Abraham's needle

70097

Submit

Previous Question | Skip Question

Calculator

Normal Values

© Pastest 2017

A 67-year-old non-smoker was referred to the Respiratory Consultant with a 3-month history of progressive shortness of breath. She was also complaining of a right-sided chest pain, which she described as a constant severe ache. She had lost about 5 kg in the last month and felt lethargic. She had initially put the symptoms down to the stress of recently being widowed. Her husband, who used to work as a plumber, died of a 'lung problem'. She has never worked outside the home, and has two daughters who are fit and well. On examination she looked unwell and was breathless at rest. Examination of her chest revealed reduced expansion, percussion note, vocal fremitus and breath sounds throughout the right hemithorax.

Investigations;

Hb	10.2 g/dl
WCC	10.8 $x10^9$/l
Platelets	471 $x10^9$/l
MCV	81 fl
ESR	69 mm/1st hour
CRP	44 mg/l
Na^+	136 mmol/l
K^+	3.7 mmol/l
Urea	6.6 mmol/l
Creatinine	77 micromol/l
Bilirubin	34 micromol/l
AST	21 U/l
ALP	97 U/l
Albumin	37 g/l

Her CXR is shown below;

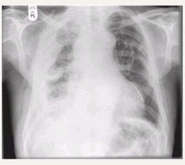

Which of the investigations is most likely to lead to a definitive diagnosis?

A Video-assisted thoracoscopic surgery biopsy

B CT chest

C Chest drain and fluid sent for cytology

D CT-guided percutaneous needle biopsy

E Blind pleural biopsy with an Abraham's needle

Explanation

A Video-assisted thoracoscopic surgery biopsy

The clue is in the question – her husband who has died worked as a plumber. She is a housewife (she has never worked outside the home), so it is assumed she washed her husband's overalls and was therefore exposed to asbestos. She has systemic symptoms as well as a pleural effusion, making the most likely diagnosis malignant mesothelioma.

Video-assisted thoracoscopy surgery is the investigation of choice as it has the highest diagnostic yield. Prophylactic radiotherapy should be given to the operation site.

The chest X-ray shows pleural thickening and an effusion on the right. There is a holly-leaf pleural plaque on the left (directly above the heart, to the left of the aortic knuckle), consistent with previous asbestos exposure. Incidentally, there is pericardial calcification.

B CT chest

A CT may show featrues in keeping a high likelihood of mesothelioma but histology is required for a definitive diagnosis.

C Chest drain and fluid sent for cytology

It is unclear on chest radiograph alone whether this lady has a pleural effusion. The shadowing seen may just be due to pleural thickening. A thoracic ultrasound should be performed prior to any pleural fluid aspiration and certainlybefore a chest drain insertion for pleural effusion (as per BTS guidelines). Additionally, pleural fluid cytology is often non diagnostic in mesothelioma.

D CT-guided percutaneous needle biopsy

In practice, radiologically guided pleural biopsies are used more in diagnosis of mesothelioma than VATS biopsy however the questionasks which investigation is most likely to lead to a definitive diagnosis and the answere to this is VATS biopsy.

E Blind pleural biopsy with an Abraham's needle

Blind pleural biopsy will give a lower diagnostic yield than CT guided or VATS biopsy.

70097

Rate this question:

Next Question

Previous Question | Tag Question

Feedback | End Session

Difficulty: Average

Peer Responses %

Session Progress

Responses Correct:	0
Responses Incorrect:	213
Responses Total:	213
Responses - % Correct:	0%

© Pastest 2017

A 39-year-old lady from Zimbabwe presented to the Emergency Department with a 5-day history of increasing shortness of breath and dry cough. She had a 1-day history of sudden onset of sharp chest pain which was worse on coughing, movement and deep inspiration. She described having night sweats and a poor appetite for 2 months. Her weight had decreased by about 5 kg. She has a past medical history of genital herpes and depression. She is married and has two children who live in Zimbabwe. She moved to England 2 years ago and has not travelled since. She is a smoker of 20/day and drinks little alcohol.

On examination she looked unwell. Observations: Temperature 38.3°C, BP 108/72 mmHg, pulse 120/min, regular, respiratory rate 30/min. Auscultation of her chest revealed inspiratory crackles bibasally.

Investigations:

Hb	10.2 g/dl
WCC	9.4 $x10^9$/l
Neutrophils	8.6 $x10^9$/l
PLT	439 $x10^9$/l
MCV	79 fl
CRP	73 mg/l
Na^+	141 mmol/l
K^+	4.2 mmol/l
Urea	5.0 mmol/l
Creatinine	75 micromol/l
Glucose	5.7 mmol/l
Blood gases on 80% oxygen:	
pH	7.46
PCO_2	3.44 kPa
PO_2	10.77 kPa
Bicarbonate	17.6 mmol/l
Base excess	-3.5

Her CXR is shown:

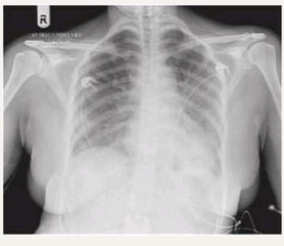

What is the most likely diagnosis?

A	Legionella pneumonia
B	Pneumocystis jirovecii pneumonia
C	Pulmonary embolus
D	Nocardiosis
E	CMV pneumonitis

70098

Submit

Previous Question | Skip Question

Calculator

Normal Values

© Pastest 2017

A 39-year-old lady from Zimbabwe presented to the Emergency Department with a 5-day history of increasing shortness of breath and dry cough. She had a 1-day history of sudden onset of sharp chest pain which was worse on coughing, movement and deep inspiration. She described having night sweats and a poor appetite for 2 months. Her weight had decreased by about 5 kg. She has a past medical history of genital herpes and depression. She is a non-smoker and has two children who live in Zimbabwe. She moved to England 2 years ago and has not travelled since. She is a smoker of 20/day and drinks little alcohol.

On examination she looked unwell. Observations: Temperature 38.3°C, BP 108/72 mmHg, pulse 120/min, regular, respiratory rate 30/min. Auscultation of her chest revealed inspiratory crackles bibasally.

Investigations:

Hb	10.2 g/dl
WCC	9.4 $x10^9$/l
Neutrophils	8.6 $x10^9$/l
PLT	439 $x10^9$/l
MCV	79 fl
CRP	73 mg/l
Na^+	141 mmol/l
K^+	4.2 mmol/l
Urea	5.0 mmol/l
Creatinine	75 micromol/l
Glucose	5.7 mmol/l
Blood gases on 80% oxygen:	
pH	7.46
PCO_2	3.44 kPa
PO_2	10.77 kPa
Bicarbonate	17.6 mmol/l
Base excess	-3.5

Her CXR is shown:

What is the most likely diagnosis?

A	Legionella pneumonia
B	Pneumocystis jirovecii pneumonia
C	Pulmonary embolus
D	Nocardiosis
E	CMV pneumonitis

Explanation

B Pneumocystis jirovecii pneumonia

For the purpose of the exam – people who have lived abroad (especially Africa and South America), businessmen who work abroad, homosexuals and intravenous drug users are more likely to have HIV.

This lady has HIV – the history of living in Zimbabwe and the low lymphocyte count are the clues. Pneumocystis jirovecii is the most common opportunistic infection to cause pneumonia in AIDS – especially when the CD4 count is below 200/mm^3. It accounts for about 50% of cases of pneumonia in AIDS and 40% of all AIDS-defining illnesses.

Patients usually present with a fever, dry cough and breathlessness. They are usually hypoxic and desaturate on exercise.

In PJP the chest X-ray usually shows bilateral interstitial shadowing and cysts in the mid and lower zones. However, the CXR may be normal. Pneumothorax (because the cysts rupture) may be present in up to 10%.

Diagnosis is now usually made by PCR of sputum or BAL fluid. Other diagnostic methods include staining induced sputum or BAL with indirect immunofluorescence with monoclonal antibodies.

Treatment is with high-flow oxygen and high dose co-trimoxazole. Prednisolone should be added in severe cases (PO_2< 9.5 kPa).

Other respiratory diseases associated with immunosuppression, in particular with HIV and AIDS, include:

- Tuberculosis
- Other bacterial pneumonias, including Mycobacterium avium intracellulare
- Cryptococcus (other fungi include – Candida, Histoplasma, Nocardia, and Aspergillus fumigatus
- CMV pneumonitis (other viruses include herpes simplex, Epstein-Barr virus)
- Toxoplasmosis
- Kaposi's sarcoma
- Lymphoma

A Legionella pneumonia

The history is clearly suggestive of underlying HIV (patient from Zimbabwe, 2 month history of being unwell and night sweats, weight loss). The chest radiograph shows widespread changes in keeping with Pneumocystis pneumonia. There is very little in the history or investigation results to suggest Legionella pneumonia.

C Pulmonary embolus

The pleuritic chest pain in this case is most likely due to pleurisy although clinicians must be aware that there is a risk of pneumothorax in Pneumocystis pneumonia.

D Nocardiosis

HIV positive individuals are at risk of nocardiosis but you would expect a productive cough, history of abscess formation (eg skin abscesses, neurological symptoms to suggest brain abscess or lung abscess and cavitation). Diffuse pulmonary shadowing can occur but the overall history is more in keeping with Pneumocystis.

E CMV pneumonitis

HIV positive individuals are at risk of CMV pneumonitis and this is the main differential here. One might expect GI or visual symptoms suggestive of systemic CMV disease. The lack of these symptoms with the history of pleuritic chest pain make Pneumocystis pneumonia more likely.

70098

Rate this question:

Next Question

Previous Question | Tag Question

Feedback | End Session

Difficulty: Average

Peer Responses %

Session Progress

Responses Correct:	0
Responses Incorrect:	214
Responses Total:	214
Responses - % Correct:	0%

Blog About Pastest Contact Us Help

© Pastest 2017

A 39-year-old lady from Zimbabwe presented to the Emergency Department with a 5-day history of increasing shortness of breath and dry cough. She had a 1-day history of sudden onset of sharp chest pain which was worse on coughing, movement and deep inspiration. She described having night sweats and a poor appetite for 2 months. Her weight had decreased by about 5 kg. She has a past medical history of genital herpes and depression. She is married and has two children who live in Zimbabwe. She moved to England 2 years ago and has not travelled since. She is a smoker of 20/day and drinks little alcohol.

On examination she looked unwell. Observations: Temperature 38.3°C, BP 108/72 mmHg, pulse 120/min, regular, respiratory rate 30/min. Auscultation of her chest revealed inspiratory crackles bibasally.

Investigations:

Hb	10.2 g/dl
WCC	9.4 $x10^9$/l
Neutrophils	8.6 $x10^9$/l
PLT	439 $x10^9$/l
MCV	79 fl
CRP	73 mg/l
Na^+	141 mmol/l
K^+	4.2 mmol/l
Urea	5.0 mmol/l
Creatinine	75 micromol/l
Glucose	5.7 mmol/l
Blood gases on 80% oxygen:	
pH	7.46
PCO_2	3.44 kPa
PO_2	10.77 kPa
Bicarbonate	17.6 mmol/l
Base excess	-3.5

Her CXR is shown:

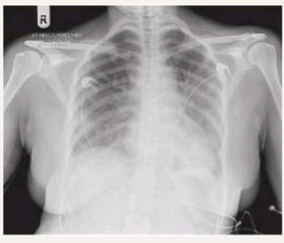

Which investigation would be most helpful in establishing a diagnosis?

A	Bronchoscopy and transbronchial biopsy
B	CT pulmonary angiogram
C	Lung function tests and transfer factor
D	Indirect immunofluorescence of the bronchoalveolar lavage
E	Blood cultures

70099

Submit

Previous Question | Skip Question

Calculator

Normal Values

© Pastest 2017

A 39-year-old lady from Zimbabwe presented to the Emergency Department with a 5-day history of increasing shortness of breath and dry cough. She had a 1-day history of sudden onset of sharp chest pain which was worse on coughing, movement and deep inspiration. She described having night sweats and a poor appetite for 2 months. Her weight had decreased by about 5 kg. She has a past medical history of genital herpes and depression. She is married and has two children who live in Zimbabwe. She moved to England 2 years ago and has not travelled since. She is a smoker of 20/day and drinks little alcohol.

On examination she looked unwell. Observations: Temperature 38.3°C, BP 108/72 mmHg, pulse 120/min, regular, respiratory rate 30/min. Auscultation of her chest revealed inspiratory crackles bibasally.

Investigations:

Hb	10.2 g/dl
WCC	9.4 $x10^9$/l
Neutrophils	8.6 $x10^9$/l
PLT	439 $x10^9$/l
MCV	79 fl
CRP	73 mg/l
Na^+	141 mmol/l
K^+	4.2 mmol/l
Urea	5.0 mmol/l
Creatinine	75 micromol/l
Glucose	5.7 mmol/l
Blood gases on 80% oxygen:	
pH	7.46
PCO_2	3.44 kPa
PO_2	10.77 kPa
Bicarbonate	17.6 mmol/l
Base excess	-3.5

Her CXR is shown:

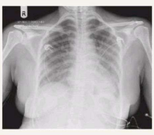

Which investigation would be most helpful in establishing a diagnosis?

A	Bronchoscopy and transbronchial biopsy
B	CT pulmonary angiogram
C	Lung function tests and transfer factor
D	Indirect immunofluorescence of the bronchoalveolar lavage
E	Blood cultures

Explanation

D	Indirect immunofluorescence of the bronchoalveolar lavage

Diagnosis is now usually made by PCR of sputum or BAL fluid. Other diagnostic methods include staining induced sputum or BAL with indirect immunofluorescence with monoclonal antibodies.

For the purpose of the exam – people who have lived abroad (especially Africa and South America), businessmen who work abroad, homosexuals and intravenous drug users are more likely to have HIV.

This lady has HIV – the history of living in Zimbabwe and the low lymphocyte count are the clues. Pneumocystis jirovecii is the most common opportunistic infection to cause pneumonia in AIDS – especially when the CD4 count is below 200/mm^3. It accounts for about 50% of cases of pneumonia in AIDS and 40% of all AIDS-defining illnesses.

Patients usually present with a fever, dry cough and breathlessness. They are usually hypoxic and desaturate on exercise.

In PJP the chest X-ray usually shows bilateral interstitial shadowing and cysts in the mid and lower zones. However, the CXR may be normal. Pneumothorax (because the cysts rupture) may be present in up to 10%.

Diagnosis is now usually made by PCR of sputum or BAL fluid. Other diagnostic methods include staining induced sputum or BAL with indirect immunofluorescence with monoclonal antibodies.

Treatment is with high-flow oxygen and high dose co-trimoxazole. Prednisolone should be added in severe cases (PO_2< 9.5 kPa).

Other respiratory diseases associated with immunosuppression, in particular with HIV and AIDS, include:

- Tuberculosis
- Other bacterial pneumonias, including Mycobacterium avium intracellulare
- Cryptococcus (other fungi include – Candida, Histoplasma, Nocardia, and Aspergillus fumigatus
- CMV pneumonitis (other viruses include herpes simplex, Epstein-Barr virus)
- Toxoplasmosis
- Kaposi's sarcoma
- Lymphoma

A	Bronchoscopy and transbronchial biopsy

Transbronchial biopsy would cause undue risk of pneumothorax in a patient already at risk of pneumothorax due to Pneumocystis pneumonia. Also, it is likely that this patient will end up invasively ventilated further adding to risk of pneumothorax.

B	CT pulmonary angiogram

CTPA is an appropriate investigation for PE.

C	Lung function tests and transfer factor

These tests would not be the most likely tests to give a definitive diagnosis, they would simply show degree of lung function impairment.

E	Blood cultures

Blood cultures are likely to be negative in Pneumocystis pneumonia.

© Pastest 2017

A 39-year-old lady from Zimbabwe presented to the Emergency Department with a 5-day history of increasing shortness of breath and dry cough. She had a 1-day history of sudden onset of sharp chest pain which was worse on coughing, movement and deep inspiration. She described having night sweats and a poor appetite for 2 months. Her weight had decreased by about 5 kg. She has a past medical history of genital herpes and depression. She is married and has two children who live in Zimbabwe. She moved to England 2 years ago and has not travelled since. She is a smoker of 20/day and drinks little alcohol.

On examination she looked unwell. Observations: Temperature 38.3°C, BP 108/72 mmHg, pulse 120/min, regular, respiratory rate 30/min. Auscultation of her chest revealed inspiratory crackles bibasally.

Investigations:

Hb	10.2 g/dl
WCC	9.4 $x10^9$/l
Neutrophils	8.6 $x10^9$/l
PLT	439 $x10^9$/l
MCV	79 fl
CRP	73 mg/l
Na^+	141 mmol/l
K^+	4.2 mmol/l
Urea	5.0 mmol/l
Creatinine	75 micromol/l
Glucose	5.7 mmol/l
Blood gases on 80% oxygen:	
pH	7.46
PCO_2	3.44 kPa
PO_2	10.77 kPa
Bicarbonate	17.6 mmol/l
Base excess	-3.5

Her CXR is shown:

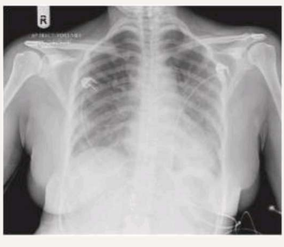

What is the most likely underlying cause?

A	Lymphoma
B	HIV
C	Bronchiectasis
D	Sarcoid
E	Common variable immune deficiency

70100

Submit

Previous Question | Skip Question

Calculator

Normal Values

© Pastest 2017

A 39-year-old lady from Zimbabwe presented to the Emergency Department with a 5-day history of increasing shortness of breath and dry cough. She had a 1-day history of sudden onset of sharp chest pain which was worse on coughing, movement and deep inspiration. She described having night sweats and a poor appetite for 2 months. Her weight had decreased by about 5 kg. She has a past medical history of genital herpes and depression. She is married and has two children who live in Zimbabwe. She moved to England 2 years ago and has not travelled since. She is a smoker of 20/day and drinks little alcohol.

On examination she looked unwell. Observations: Temperature 38.3°C, BP 108/72 mmHg, pulse 120/min, regular, respiratory rate 30/min. Auscultation of her chest revealed inspiratory crackles bibasally.

Investigations:

Hb	10.2 g/dl
WCC	9.4 $x10^9$/l
Neutrophils	8.6 $x10^9$/l
PLT	439 $x10^9$/l
MCV	79 fl
CRP	73 mg/l
Na^+	141 mmol/l
K^+	4.2 mmol/l
Urea	5.0 mmol/l
Creatinine	75 micromol/l
Glucose	5.7 mmol/l
Blood gases on 80% oxygen:	
pH	7.46
PCO_2	3.44 kPa
PO_2	10.77 kPa
Bicarbonate	17.6 mmol/l
Base excess	-3.5

Her CXR is shown:

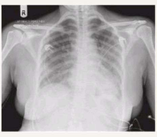

What is the most likely underlying cause?

A	Lymphoma
B	HIV
C	Bronchiectasis
D	Sarcoid
E	Common variable immune deficiency

Explanation

B	HIV

For the purpose of the exam – people who have lived abroad (especially Africa and South America), businessmen who work abroad, homosexuals and intravenous drug users are more likely to have HIV.

This lady has HIV – the history of living in Zimbabwe and the low lymphocyte count are the clues. Pneumocystis jirovecii is the most common opportunistic infection to cause pneumonia in AIDS – especially when the CD4 count is below 200/mm^3. It accounts for about 50% of cases of pneumonia in AIDS and 40% of all AIDS-defining illnesses.

Patients usually present with a fever, dry cough and breathlessness. They are usually hypoxic and desaturate on exercise.

In PJP the chest X-ray usually shows bilateral interstitial shadowing and cysts in the mid and lower zones. However, the CXR may be normal. Pneumothorax (because the cysts rupture) may be present in up to 10%.

Diagnosis is now usually made by PCR of sputum or BAL fluid. Other diagnostic methods include staining induced sputum or BAL with indirect immunofluorescence with monoclonal antibodies.

Treatment is with high-flow oxygen and high dose co-trimoxazole. Prednisolone should be added in severe cases (PO_2< 9.5 kPa).

Other respiratory diseases associated with immunosuppression, in particular with HIV and AIDS, include:

- Tuberculosis
- Other bacterial pneumonias, including Mycobacterium avium intracellulare
- Cryptococcus (other fungi include – Candida, Histoplasma, Nocardia, and Aspergillus fumigatus
- CMV pneumonitis (other viruses include herpes simplex, Epstein-Barr virus)
- Toxoplasmosis
- Kaposi's sarcoma
- Lymphoma

A	Lymphoma

Given the patient is from sub-Saharan Africa and is presenting with a history suggestive of disseminated lung infection HIV is more a likely cause than lymphoma for the night sweats and weight loss.

C	Bronchiectasis

The patient has a non productive cough and gives an acute history of pulmonary infection making bronchiectasis unlikely.

D	Sarcoid

This is a history of pulmonary infection with fever, sweats, raised CRP.

E	Common variable immune deficiency

This condition is present from birth and there would be a history of previous recurrent infections since childhood.

70100

Rate this question:

Next Question

Previous Question | Tag Question

Feedback | End Session

Difficulty: Average

Peer Responses %

Session Progress

Responses Correct:	0
Responses Incorrect:	216
Responses Total:	216
Responses - % Correct:	0%

Blog About Pastest Contact Us Help

© Pastest 2017

A 39-year-old lady from Zimbabwe presented to the Emergency Department with a 5-day history of increasing shortness of breath and dry cough. She had a 1-day history of sudden onset of sharp chest pain which was worse on coughing, movement and deep inspiration. She described having night sweats and a poor appetite for 2 months. Her weight had decreased by about 5 kg. She has a past medical history of genital herpes and depression. She is married and has two children who live in Zimbabwe. She moved to England 2 years ago and has not travelled since. She is a smoker of 20/day and drinks little alcohol.

On examination she looked unwell. Observations: Temperature 38.3°C, BP 108/72 mmHg, pulse 120/min, regular, respiratory rate 30/min. Auscultation of her chest revealed inspiratory crackles bibasally.

Investigations:

Hb	10.2 g/dl
WCC	9.4 $x10^9$/l
Neutrophils	8.6 $x10^9$/l
PLT	439 $x10^9$/l
MCV	79 fl
CRP	73 mg/l
Na^+	141 mmol/l
K^+	4.2 mmol/l
Urea	5.0 mmol/l
Creatinine	75 micromol/l
Glucose	5.7 mmol/l
Blood gases on 80% oxygen:	
pH	7.46
PCO_2	3.44 kPa
PO_2	10.77 kPa
Bicarbonate	17.6 mmol/l
Base excess	-3.5

Her CXR is shown:

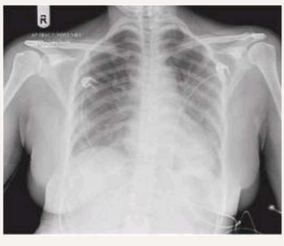

What treatment should be started?

A	Intravenous Cephalosporin and Clarithromycin
B	Anticoagulation with warfarin
C	Prednisolone
D	Intravenous Ganciclovir
E	Intravenous high-dose Co-trimoxazole ± steroids

70101

Submit

Previous Question | Skip Question

Calculator

Normal Values

© Pastest 2017

A 39-year-old lady from Zimbabwe presented to the Emergency Department with a 5-day history of increasing shortness of breath and dry cough. She had a 1-day history of sudden onset of sharp chest pain which was worse on coughing, movement and deep inspiration. She described having night sweats and a poor appetite for 2 months. Her weight had decreased by about 5 kg. She has a past medical history of genital herpes and depression. She is married and has two children who live in Zimbabwe. She moved to England 2 years ago and has not travelled since. She is a smoker of 20/day and drinks little alcohol.

On examination she looked unwell. Observations: Temperature 38.3°C, BP 108/72 mmHg, pulse 120/min, regular, respiratory rate 30/min. Auscultation of her chest revealed inspiratory crackles bibasally.

Investigations:

Hb	10.2 g/dl
WCC	9.4 $x10^9$/l
Neutrophils	8.6 $x10^9$/l
PLT	439 $x10^9$/l
MCV	79 fl
CRP	73 mg/l
Na^+	141 mmol/l
K^+	4.2 mmol/l
Urea	5.0 mmol/l
Creatinine	75 micromol/l
Glucose	5.7 mmol/l
Blood gases on 80% oxygen:	
pH	7.46
PCO_2	3.44 kPa
PO_2	10.77 kPa
Bicarbonate	17.6 mmol/l
Base excess	-3.5

Her CXR is shown:

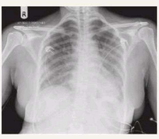

What treatment should be started?

A	Intravenous Cephalosporin and Clarithromycin
B	Anticoagulation with warfarin
C	Prednisolone
D	Intravenous Ganciclovir
E	Intravenous high-dose Co-trimoxazole ± steroids

Explanation

E	Intravenous high-dose Co-trimoxazole ± steroids

For the purpose of the exam – people who have lived abroad (especially Africa and South America), businessmen who work abroad, homosexuals and intravenous drug users are more likely to have HIV.

This lady has HIV – the history of living in Zimbabwe and the low lymphocyte count are the clues. Pneumocystis jirovecii is the most common opportunistic infection to cause pneumonia in AIDS – especially when the CD4 count is below 200/mm^3. It accounts for about 50% of cases of pneumonia in AIDS and 40% of all AIDS-defining illnesses.

Patients usually present with a fever, dry cough and breathlessness. They are usually hypoxic and desaturate on exercise.

In PJP the chest X-ray usually shows bilateral interstitial shadowing and cysts in the mid and lower zones. However, the CXR may be normal. Pneumothorax (because the cysts rupture) may be present in up to 10%.

Diagnosis is now usually made by PCR of sputum or BAL fluid. Other diagnostic methods include staining induced sputum or BAL with indirect immunofluorescence with monoclonal antibodies.

Treatment is with high-flow oxygen and high dose co-trimoxazole. Prednisolone should be added in severe cases (PO_2< 9.5 kPa).

Other respiratory diseases associated with immunosuppression, in particular with HIV and AIDS, include:

- Tuberculosis
- Other bacterial pneumonias, including Mycobacterium avium intracellulare
- Cryptococcus (other fungi include – Candida, Histoplasma, Nocardia, and Aspergillus fumigatus
- CMV pneumonitis (other viruses include herpes simplex, Epstein-Barr virus)
- Toxoplasmosis
- Kaposi's sarcoma
- Lymphoma

A	Intravenous Cephalosporin and Clarithromycin

This is appropriate treatment for severe community acquired pneumonia.

B	Anticoagulation with warfarin

This is appropriate treatment for PE.

C	Prednisolone

Prednisolone may be appropriate in combination with Co-trimoxazole in significantly hypoxic patients with Pneumocystis but should not be given alone.

D	Intravenous Ganciclovir

This is an appropriate treatment for CMV pneumonitis.

70101

Rate this question:

Next Question

Previous Question | Tag Question

Feedback | End Session

Difficulty: Average

Peer Responses %

Session Progress

Responses Correct:	0
Responses Incorrect:	217
Responses Total:	217
Responses - % Correct:	0%

© Pastest 2017

A 55-year-old woman presented with a 6-month history of recurrent chest infections. She had had a few episodes of wheeze and haemoptysis in the last few weeks. She also noticed intermittent hot flushes, which her GP had put down to the menopause. These could occur at any time but on occasions were precipitated by alcohol. She had no significant past medical history and she had never smoked. On examination she was anxious, examination of her chest revealed reduced expansion of the upper right zone. Cardiovascular examination revealed a pansystolic murmr. Blood results were unremarkable. Her CXR is shown;

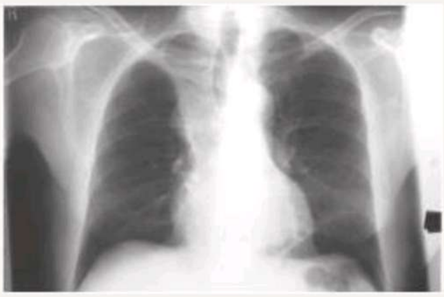

What investigation is most likely to reveal the diagnosis?

A	CT thorax
B	Metacholine challenge test
C	Urinary 5-hydroxyindoleacetic acid
D	Urinary catecholamines
E	Sputum culture

70102

Submit

Previous Question | Skip Question

Calculator

Normal Values

© Pastest 2017

A 55-year-old woman presented with a 6-month history of recurrent chest infections. She had had a few episodes of wheeze and haemoptysis in the last few weeks. She also noticed intermittent hot flushes, which her GP had put down to the menopause. These could occur at any time but on occasions were precipitated by alcohol. She had no significant past medical history and she had never smoked. On examination she was anxious, examination of her chest revealed reduced expansion of the upper right zone. Cardiovascular examination revealed a pansystolic murmr. Blood results were unremarkable. Her CXR is shown;

What investigation is most likely to reveal the diagnosis?

A	CT thorax
B	Metacholine challenge test
C	Urinary 5-hydroxyindoleacetic acid
D	Urinary catecholamines
E	Sputum culture

Explanation

C	Urinary 5-hydroxyindoleacetic acid

This patient has bronchial carcinoid. It commonly presents between the ages of 50 and 70 and is unrelated to smoking. Bronchial carcinoid tumours are the most indolent form of a spectrum of neuroendocrine tumours of the lung that include small-cell lung cancer as the most malignant. They are thought to arise from Kulchitsky's cells in the bronchial mucosa. They usually secrete serotonin and arise from the large bronchi. Patients may present with a mass, which is usually centrally located (as in this case – CXR shows right upper lobe collapse), or with recurrent chest infections, haemoptysis, chest pain and wheeze. Flushing (which may be precipitated by alcohol, food ingestion, stress or emotion) and diarrhoea may occur. However, patients are commonly asymptomatic and the tumour is found incidentally.

Carcinoid syndrome occurs when there are secondaries in the liver which release serotonin into the systemic circulation. However, symptoms of carcinoid syndrome may rarely occur in bronchial carcinoid in the absence of metastases as the bronchial tree drains straight into the systemic circulation.

Diagnosis is by detection of 5-hydroxyindoleacetic acid (the metabolite of serotonin) in the urine and bronchial carcinoid is usually seen and diagnosed by bronchoscopy and biopsy.

The treatment of choice of bronchial carcinoid is surgical resection. Flushing may be controlled with somatostatin analogues.

Pellagra may occur due to tumour uptake of tryptophan, the precursor of nicotinic acid.

A	CT thorax

CT may confirm upper lobe collapse an visualise any obstructing lesion but would not give definitive diagnosis.

B	Metacholine challenge test

This is a test for asthma which is an unikely diagnosis based on the history and CXR.

D	Urinary catecholamines

This is a test for phaeochromocytoma.

E	Sputum culture

Sputum culture may reveal pulmonary infection due to an obstructed right upper lobe bronchus but will not confirm the underlying diagnosis.

70102

Rate this question:

Next Question

Previous Question	Tag Question
Feedback	End Session

Difficulty: Average

Peer Responses %

Session Progress

Responses Correct:	0
Responses Incorrect:	218
Responses Total:	218
Responses - % Correct:	0%

© Pastest 2017

A 55-year-old woman presented with a 6-month history of recurrent chest infections. She had had a few episodes of wheeze and haemoptysis in the last few weeks. She also noticed intermittent hot flushes, which her GP had put down to the menopause. These could occur at any time but on occasions were precipitated by alcohol. She had no significant past medical history and she had never smoked. On examination she was anxious, examination of her chest revealed reduced expansion of the upper right zone. Cardiovascular examination revealed a pansystolic murmr. Blood results were unremarkable. Her CXR is shown;

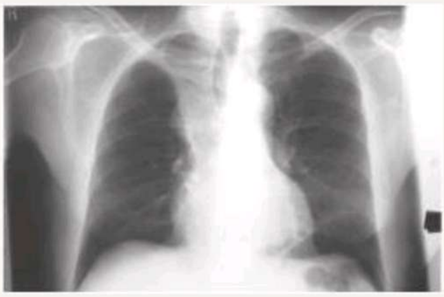

What is the most likely diagnosis?

A	Lymphoma
B	Phaeochromocytoma
C	Bronchial carcinoid
D	Late-onset asthma
E	Bronchiectasis

70103

Submit

Previous Question | Skip Question

Calculator

Normal Values

© Pastest 2017

A 55-year-old woman presented with a 6-month history of recurrent chest infections. She had had a few episodes of wheeze and haemoptysis in the last few weeks. She also noticed intermittent hot flushes, which her GP had put down to the menopause. These could occur at any time but on occasions were precipitated by alcohol. She had no significant past medical history and she had never smoked. On examination she was anxious, examination of her chest revealed reduced expansion of the upper right zone. Cardiovascular examination revealed a pansystolic murmr. Blood results were unremarkable. Her CXR is shown;

What is the most likely diagnosis?

A	Lymphoma
B	Phaeochromocytoma
C	Bronchial carcinoid
D	Late-onset asthma
E	Bronchiectasis

Explanation

C Bronchial carcinoid

This patient has bronchial carcinoid. It commonly presents between the ages of 50 and 70 and is unrelated to smoking. Bronchial carcinoid tumours are the most indolent form of a spectrum of neuroendocrine tumours of the lung that include small-cell lung cancer as the most malignant. They are thought to arise from Kulchitsky's cells in the bronchial mucosa. They usually secrete serotonin and arise from the large bronchi. Patients may present with a mass, which is usually centrally located (as in this case – CXR shows right upper lobe collapse), or with recurrent chest infections, haemoptysis, chest pain and wheeze. Flushing (which may be precipitated by alcohol, food ingestion, stress or emotion) and diarrhoea may occur. However, patients are commonly asymptomatic and the tumour is found incidentally.

Carcinoid syndrome occurs when there are secondaries in the liver which release serotonin into the systemic circulation. However, symptoms of carcinoid syndrome may rarely occur in bronchial carcinoid in the absence of metastases as the bronchial tree drains straight into the systemic circulation.

Diagnosis is by detection of 5-hydroxyindoleacetic acid (the metabolite of serotonin) in the urine and bronchial carcinoid is usually seen and diagnosed by bronchoscopy and biopsy.

The treatment of choice of bronchial carcinoid is surgical resection. Flushing may be controlled with somatostatin analogues.

Pellagra may occur due to tumour uptake of tryptophan, the precursor of nicotinic acid.

A Lymphoma

The chest radiograph does not show mediastinal lymphadenopathy, it shows right upper lobe collapse. There is no history of weight loss or night sweats.

B Phaeochromocytoma

Phaeochromocytoma presents as a triad of palpitations, sweating and tachycardia. CXR would likely be normal.

D Late-onset asthma

Wheeze here is not due to asthma.

E Bronchiectasis

With right upper lobe collapse an obstructive airway lesion is most likely for her recurrent infections, not bronchiectasis.

70103

Rate this question:

Next Question

Previous Question | Tag Question

Feedback | End Session

Difficulty: Average

Peer Responses %

Session Progress

Responses Correct:	0
Responses Incorrect:	219
Responses Total:	219
Responses - % Correct:	0%

© Pastest 2017

A 55-year-old woman presented with a 6-month history of recurrent chest infections. She had had a few episodes of wheeze and haemoptysis in the last few weeks. She also noticed intermittent hot flushes, which her GP had put down to the menopause. These could occur at any time but on occasions were precipitated by alcohol. She had no significant past medical history and she had never smoked. On examination she was anxious, examination of her chest revealed reduced expansion of the upper right zone. Cardiovascular examination revealed a pansystolic murmr.

Blood results were unremarkable. Her CXR is shown:

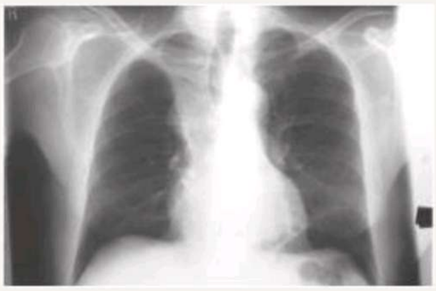

What is the treatment of choice?

A	Surgery
B	Steroid inhaler
C	Intravenous antibiotics
D	CHOP chemotherapy
E	Alpha-adrenergic blockade, e.g. Phenoxybenzamine

70104

Submit

Previous Question | Skip Question

Calculator

Normal Values

© Pastest 2017

A 55-year-old woman presented with a 6-month history of recurrent chest infections. She had had a few episodes of wheeze and haemoptysis in the last few weeks. She also noticed intermittent hot flushes, which her GP had put down to the menopause. These could occur at any time but on occasions were precipitated by alcohol. She had no significant past medical history and she had never smoked. On examination she was anxious, examination of her chest revealed reduced expansion of the upper right zone. Cardiovascular examination revealed a pansystolic murmr.

Blood results were unremarkable. Her CXR is shown:

What is the treatment of choice?

A	Surgery
B	Steroid inhaler
C	Intravenous antibiotics
D	CHOP chemotherapy
E	Alpha-adrenergic blockade, e.g. Phenoxybenzamine

Explanation

A	Surgery

The treatment of choice of bronchial carcinoid is surgical resection. Flushing may be controlled with stomatostatin analogues.

This patient has bronchial carcinoid. It commonly presents between the ages of 50 and 70 and is unrelated to smoking. Bronchial carcinoid tumours are the most indolent form of a spectrum of neuroendocrine tumours of the lung that include small-cell lung cancer as the most malignant. They are thought to arise from Kulchitsky's cells in the bronchial mucosa. They usually secrete serotonin and arise from the large bronchi. Patients may present with a mass, which is usually centrally located (as in this case – CXR shows right upper lobe collapse), or with recurrent chest infections, haemoptysis, chest pain and wheeze. Flushing (which may be precipitated by alcohol, food ingestion, stress or emotion) and diarrhoea may occur. However, patients are commonly asymptomatic and the tumour is found incidentally.

Carcinoid syndrome occurs when there are secondaries in the liver which release serotonin into the systemic circulation. However, symptoms of carcinoid syndrome may rarely occur in bronchial carcinoid in the absence of metastases as the bronchial tree drains straight into the systemic circulation.

Diagnosis is by detection of 5-hydroxyindoleacetic acid (the metabolite of serotonin) in the urine and bronchial carcinoid is usually seen and diagnosed by bronchoscopy and biopsy.

The treatment of choice of bronchial carcinoid is surgical resection. Flushing may be controlled with somatostatin analogues.

Pellagra may occur due to tumour uptake of tryptophan, the precursor of nicotinic acid.

B	Steroid inhaler

This is an appropriate treatment for asthma.

C	Intravenous antibiotics

This is an appropriate treatment for pulmonary infection.

D	CHOP chemotherapy

This is an appropriate treatment for lymphoma.

E	Alpha-adrenergic blockade, e.g. Phenoxybenzamine

This is an appropriate treatment for phaemochromocytoma

70104

Rate this question:

Next Question

Previous Question | Tag Question

Feedback | End Session

Difficulty: Average

Peer Responses %

Session Progress

Responses Correct:	0
Responses Incorrect:	220
Responses Total:	220
Responses - % Correct:	0%

© Pastest 2017

A 30-year-old man from London with no significant past medical history went on holiday to Peru to climb the Inca Trail. He is a non-smoker. After climbing above 3500 m he developed a headache, associated with nausea and vomiting. He also felt tired and complained of insomnia.

His respiratory rate was 22/min and his pulse was 90/min. Physical examination was unremarkable. No investigations are available as the nearest hospital is over 100 km away.

What is the most likely diagnosis?

A	Exhaustion
B	Hangover
C	Migraine
D	Acute mountain sickness
E	Hypothermia

70106

Submit

Previous Question | Skip Question

Calculator

Normal Values

© Pastest 2017

A 30-year-old man from London with no significant past medical history went on holiday to Peru to climb the Inca Trail. He is a non-smoker. After climbing above 3500 m he developed a headache, associated with nausea and vomiting. He also felt tired and complained of insomnia.

His respiratory rate was 22/min and his pulse was 90/min. Physical examination was unremarkable. No investigations are available as the nearest hospital is over 100 km away.

What is the most likely diagnosis?

A	Exhaustion
B	Hangover
C	Migraine
D	Acute mountain sickness
E	Hypothermia

Explanation

D	Acute mountain sickness

There are three types of altitude illness. Acute mountain sickness (AMS), high-altitude cerebral oedema (HACE) and high-altitude pulmonary oedema (HAPE). This man has acute mountain sickness with some evidence of cerebral oedema. The exact cause is unknown but it is thought to be secondary to cerebral oedema and raised intracranial pressure. It is more common in people who live at low altitude.

Symptoms and signs of AMS are non-specific; however, diagnosis can be made using the criteria named in 'The Lake Louise Score', namely, the setting of recent gain in altitude, the presence of headache and at least one of the following symptoms:

- Gastrointestinal – anorexia, nausea and vomiting
- Fatigue and weakness
- Dizziness or light-headedness
- Difficulty sleeping

He does not improve and progresses to develop ataxia and drowsiness. This is the development of high-altitude cerebral oedema, which can be considered as end-stage AMS.

Treatment is immediate descent, oxygen and intravenous dexamethasone.

Acetazolamide may be used for prevention and treatment of AMS. It is a carbonic anhydrase inhibitor which causes intracellular acidosis. It has a diuretic effect which can be useful in AMS/HACE and HAPE. It is also beneficial as it shifts the oxygen-dissociation curve to the right and therefore at lower partial pressures, more oxygen is released to the tissues.

A	Exhaustion

This is more than exhaustion, he has symptoms suggestive of altitude sickness.

B	Hangover

There is no history of or to suggest alcohol consumption.

C	Migraine

This would be a likely differential diagnosis if he was not at altitude.

E	Hypothermia

He has classical symptoms of mountain sickness, hypothermiais not the most likely diagnosis here.

70106

Rate this question:

Next Question

Previous Question | Tag Question

Feedback | End Session

Difficulty: Average

Peer Responses %

Session Progress

Responses Correct:	0
Responses Incorrect:	221
Responses Total:	221
Responses - % Correct:	0%

© Pastest 2017

A 30-year-old man from London with no significant past medical history went on holiday to Peru to climb the Inca Trail. He is a non-smoker. After climbing above 3500 m he developed a headache, associated with nausea and vomiting. He also felt tired and complained of insomnia. His respiratory rate was 22/min and his pulse was 90/min. The rest of the physical examination was unremarkable.

Investigations:

WCC	10.1×10^9/l
PLT	223×10^9/l
Urea	10 mmol/l
Creatinine	70 mol/l
Na^+	135 mmol/l
K^+	4.3 mmol/l

Which drug may have helped to prevent his symptoms?

A	Aspirin
B	Diazepam
C	Furosemide
D	Acetazolamide
E	Propranolol

70107

Submit

Previous Question | Skip Question

Calculator

Normal Values

© Pastest 2017

A 30-year-old man from London with no significant past medical history went on holiday to Peru to climb the Inca Trail. He is a non-smoker. After climbing above 3500 m he developed a headache, associated with nausea and vomiting. He also felt tired and complained of insomnia. His respiratory rate was 22/min and his pulse was 90/min. The rest of the physical examination was unremarkable.

Investigations:

WCC	10.1×10^9/l
PLT	223×10^9/l
Urea	10 mmol/l
Creatinine	70 mol/l
Na^+	135 mmol/l
K^+	4.3 mmol/l

Which drug may have helped to prevent his symptoms?

A Aspirin

B Diazepam

C Furosemide

D Acetazolamide

E Propranolol

Explanation

D Acetazolamide

There are three types of altitude illness: acute mountain sickness (AMS), high-altitude cerebral oedema (HACE) and high-altitude pulmonary oedema (HAPE). This man has acute mountain sickness with some evidence of cerebral oedema. The exact cause is unknown but it is thought to be secondary to cerebral oedema and raised intracranial pressure. It is more common in people who live at low altitude.

Symptoms and signs of AMS are non-specific; however, diagnosis can be made using the criteria named in 'The Lake Louise Score', namely, the setting of recent gain in altitude, the presence of headache and at least one of the following symptoms:

- Gastrointestinal – anorexia, nausea and vomiting
- Fatigue and weakness
- Dizziness or light-headedness
- Difficulty sleeping.

Acetazolamide may be used for prevention and treatment of acute mountain sickness (AMS). It is a carbonic anhydrase inhibitor that causes intracellular acidosis. It has a diuretic effect which can be useful in AMS/HACE and HAPE. It is also beneficial as it shifts the oxygen-dissociation curve to the right and therefore, at lower partial pressures, more oxygen is released to the tissues.

If he does not improve and progresses to develop ataxia and drowsiness, this is the development of high-altitude cerebral oedema, which can be considered as end-stage AMS. Treatment is immediate descent, oxygen and intravenous dexamethasone.

A Aspirin

Aspirin, acetylsalicylic acid, may be used in the treatment of pain, fever and inflammation. It is commonly used in the treatment of coronary artery disease. However, it does not have any role in AMS.

B Diazepam

Diazepam can be used for the treatment of anxiety disorders, alcohol withdrawal symptoms or muscle spasms. It is part of the benzodiazepine family, which produces a calming effect. It does not have any role in the treatment of AMS.

C Furosemide

Previously, frusemide was claimed to prevent acute mountain sickness and pulmonary oedema of high altitude. However, results in treating experimental animals showed that death rate was higher among the frusemide-treated groups for both mild and severe dehydration. Therefore there is no role for frusemide in AMS.

E Propranolol

One of the physiological adjustments to high altitude to compensate for hypoxia is activation of the sympathetic nervous system. Therefore, it could be hypothesised that hindering the sympathetic nervous system with propranolol may hinder altitude acclimatization and exacerbate AMS, compromising well-being. However, studies have shown that this is not the case and that it did not result in any change. Nevertheless, there was no improvement in symptoms either.

© Pastest 2017

A 30-year-old man from London, with no significant past medical history, went on holiday to Peru to climb the Inca Trail. He is a non-smoker. After climbing above 3500 m he developed a headache, associated with nausea and vomiting. He also felt tired and complained of insomnia. His respiratory rate was 22/min and his pulse was 90/min. The remainder of physical examination was unremarkable.

Investigations reveal:

Urea	10 mmol/l
Creatinine	70 mol/l
Na^+	135 mmol/l
K^+	4.3 mmol/l

That night it was noticed that he was disorientated and walking with a broad-based gait, and by the following morning he was drowsy and incoherent.

What is the most likely cause?

A	Cerebellar infarction
B	Cerebral haemorrhage
C	High-altitude pulmonary oedema
D	Meningococcal septicaemia
E	High-altitude cerebral oedema

70108

Submit

Previous Question | Skip Question

Calculator

Normal Values

© Pastest 2017

A 30-year-old man from London, with no significant past medical history, went on holiday to Peru to climb the Inca Trail. He is a non-smoker. After climbing above 3500 m he developed a headache, associated with nausea and vomiting. He also felt tired and complained of insomnia. His respiratory rate was 22/min and his pulse was 90/min. The remainder of physical examination was unremarkable.

Investigations reveal:

Urea	10 mmol/l
Creatinine	70 mol/l
Na^+	135 mmol/l
K^+	4.3 mmol/l

That night it was noticed that he was disorientated and walking with a broad-based gait, and by the following morning he was drowsy and incoherent.

What is the most likely cause?

A Cerebellar infarction

B Cerebral haemorrhage

C High-altitude pulmonary oedema

D Meningococcal septicaemia

E High-altitude cerebral oedema

Explanation

E High-altitude cerebral oedema

There are three types of altitude illness: acute mountain sickness (AMS), high-altitude cerebral oedema (HACE) and high-altitude pulmonary oedema (HAPE). This man has acute mountain sickness with some evidence of cerebral oedema. The exact cause is unknown, but it is thought to be secondary to cerebral oedema and raised intracranial pressure. It is more common in people who live at low altitude.

Symptoms and signs of AMS are non-specific; however, diagnosis can be made using the criteria named in 'The Lake Louise Score', namely, the setting of recent gain in altitude, the presence of headache and at least one of the following symptoms:

- Gastrointestinal – anorexia, nausea and vomiting
- Fatigue and weakness
- Dizziness or light-headedness
- Difficulty sleeping.

He does not improve and progresses to develop ataxia and drowsiness. This is the development of high-altitude cerebral oedema, which can be considered as end-stage AMS.

Treatment is immediate descent, oxygen and intravenous dexamethasone.

Acetazolamide may be used for prevention and treatment of AMS. This is a carbonic anhydrase inhibitor which causes intracellular acidosis. It has a diuretic effect which can be useful in AMS/HACE and HAPE. It is also beneficial as it shifts the oxygen-dissociation curve to the right and therefore at lower partial pressures, more oxygen is released to the tissues.

A Cerebellar infarction

There is no history of unsteady gait and, given that the patient is at altitude, mountain sickness is more likely. Cerebellar infarction presents with non-specific symptoms such as dizziness, nausea and vomiting, unsteady gait and headache.

B Cerebral haemorrhage

There are other more likely diagnoses here. He has no neurological symptoms other than headache. Cerebral haemorrhage will present with neurological symptoms and signs depending on where the haemorrhage is located. For example, a cerebellar infarct will present with unsteady gait.

C High-altitude pulmonary oedema

There is nothing in the history to suggest pulmonary oedema. There is no history of breathlessness.

D Meningococcal septicaemia

There is no suggestion of fever, meningism or rash. Meningococcal infection is the most common cause of bacterial meningitis in the UK. There are several strains of meningococcal bacteria, such as A, B and C.

© Pastest 2017

A 30-year-old man from London, with no significant past medical history, went on holiday to Peru to climb the Inca Trail. He is a non-smoker. After climbing above 3500 m he developed a headache, associated with nausea and vomiting. He also felt tired and complained of insomnia. His respiratory rate was 22/min and his pulse was 90/min. The rest of the physical examination was unremarkable. No investigations are available as the nearest hospital is over 100 km away. That night it was noticed that he was disorientated and walking with a broad-based gait, and by the following morning he was drowsy and incoherent.

How would you treat this man?

A	Immediate transfer down the mountain
B	Acetazolamide and continue ascent
C	Aspirin
D	Dexamethasone and continue ascent
E	Immediate antibiotics

70109

Submit

Previous Question Skip Question

Calculator

Normal Values

Blog About Pastest Contact Us Help

© Pastest 2017

A 30-year-old man from London, with no significant past medical history, went on holiday to Peru to climb the Inca Trail. He is a non-smoker. After climbing above 3500 m he developed a headache, associated with nausea and vomiting. He also felt tired and complained of insomnia. His respiratory rate was 22/min and his pulse was 90/min. The rest of the physical examination was unremarkable. No investigations are available as the nearest hospital is over 100 km away. That night it was noticed that he was disorientated and walking with a broad-based gait, and by the following morning he was drowsy and incoherent.

How would you treat this man?

A	Immediate transfer down the mountain
B	Acetazolamide and continue ascent
C	Aspirin
D	Dexamethasone and continue ascent
E	Immediate antibiotics

Explanation

A Immediate transfer down the mountain

There are three types of altitude illness: acute mountain sickness (AMS), high-altitude cerebral oedema (HACE) and high-altitude pulmonary oedema (HAPE). This man has acute mountain sickness with some evidence of cerebral oedema. The exact cause is unknown, but it is thought to be secondary to cerebral oedema and raised intracranial pressure. It is more common in people who live at low altitude.

Symptoms and signs of AMS are non-specific; however, diagnosis can be made using the criteria named in 'The Lake Louise Score', namely, the setting of recent gain in altitude, the presence of headache and at least one of the following symptoms:

- Gastrointestinal – anorexia, nausea and vomiting
- Fatigue and weakness
- Dizziness or light-headedness
- Difficulty sleeping.

If he does not improve and progresses to develop ataxia and drowsiness, this is the development of high-altitude cerebral oedema, which can be considered as end-stage AMS. This is the presentation of this case.

B Acetazolamide and continue ascent

Acetazolamide may be used for the prevention and treatment of AMS. This is a carbonic anhydrase inhibitor which causes intracellular acidosis. It has a diuretic effect which can be useful in AMS/HACE and HAPE. It is also beneficial as it shifts the oxygen-dissociation curve to the right and therefore, at lower partial pressures, more oxygen is released to the tissues. In this scenario, this patient has full house symptoms of altitude sickness and is at high risk of further deterioration. Further ascent, even with acetazolamide, would be dangerous.

C Aspirin

This would not help symptoms of mountain sickness. This is a treatment for acute MI or non-haemorrhagic CVA. Aspirin, acetylsalicylic acid, may also be used in the treatment of pain, fever and inflammation.

D Dexamethasone and continue ascent

This patient has full house symptoms of altitude sickness and is at high risk of further deterioration. Further ascent even with acetazolamide would be dangerous.

E Immediate antibiotics

This is an appropriate treatment for severe infection. However, it has no role in AMS. There is no indication that this patient is suffering from infection: there are no fever, chills, rigors or skin rash.

70109

Rate this question:

Next Question

Previous Question	Tag Question
Feedback	End Session

Difficulty: Average

Peer Responses %

Session Progress

Responses Correct:	0
Responses Incorrect:	224
Responses Total:	224
Responses - % Correct:	0%

© Pastest 2017

A 32-year-old man presents with recurrent chest infections productive of copious amounts of green purulent sputum. He had recurrent ear infections as a child. He is a smoker of 20/day and is married with no children. On examination he is clubbed. Auscultation of his chest reveals coarse bi-basal crackles and an expiratory wheeze. Heart sounds are normal. Abdominal examination is unremarkable except for a scar in the left iliac fossa. His CXR is shown below.

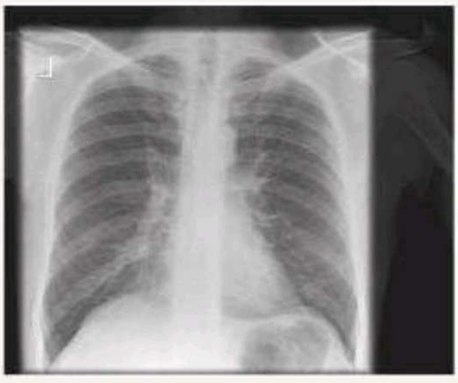

What is the cause of his recurrent chest infections?

A	Allergic bronchopulmonary aspergillosis
B	Asthma
C	Bronchial obstruction
D	Tuberculosis
E	Bronchiectasis

70110

Submit

Previous Question | Skip Question

Calculator

Normal Values

© Pastest 2017

A 32-year-old man presents with recurrent chest infections productive of copious amounts of green purulent sputum. He had recurrent ear infections as a child. He is a smoker of 20/day and is married with no children. On examination he is clubbed. Auscultation of his chest reveals coarse bi-basal crackles and an expiratory wheeze. Heart sounds are normal. Abdominal examination is unremarkable except for a scar in the left iliac fossa. His CXR is shown below.

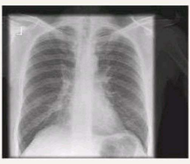

What is the cause of his recurrent chest infections?

A	Allergic bronchopulmonary aspergillosis
B	Asthma
C	Bronchial obstruction
D	Tuberculosis
E	Bronchiectasis

Explanation

E	Bronchiectasis

The clinical features include recurrent chest infections with the production of copious amounts of mucopurulent sputum. Other symptoms include dyspnoea, wheeze and pleuritic chest pain. Patients are usually clubbed and course crackles are heard in affected areas.

Bronchiectasis is idiopathic in around 60% of cases, but there are many potential causes:

- Congenital (e.g. Marfans, Williams–Campbell syndrome
- Post-infective (e.g. after measles, TB, pneumonia or pertussis)
- Immunodeficiency (e.g. HIV, haematological malignancy, post-transplanatation)
- Allergic bronchopulmonary aspergillosis (bronchiectasisis, usually proximal)
- Cystic fibrosis
- Distal to an obstructed bronchus, e.g. from a tumour
- Complication sarcoidosis or pulmonary fibrosis (traction bronchiectasis)
- Mucociliary clearance defects: primary ciliary dyskinesia, Kartagner's
- Alpha-1 anti-trypsin deficiency.

The investigation of choice is a high-resolution CT and is diagnostic in >90% of cases, demonstrating bronchial dilatation and wall thickening. Patients should have blood taken for immunoglobulin levels, functional antibodies and aspergillus serology. Based on clinical history, patients may require tests of ciliary function, cystic fibrosis genotyping or sweat testing, alpha-1 antitrypsin levels or neutrophil function testing.

The unifying diagnosis is Kartagener syndrome – situs inversus, sinusitis and bronchiectasis. The clues are the appendicectomy scar in the left iliac fossa and the chest X-ray showing dextrocardia (note the 'L' in reverse in the top right-hand corner of the radiograph). Diagnosis is confirmed with an epithelial (nasal or bronchial) brush or biopsy. These are examined to determine whether cilia demonstrate normal coordination, beat frequency and beat pattern. Cross-sections of the cilia are also examined by electron microscopy and specific defects of structure visualised, e.g. absence of dynein arms. Young' syndrome is bronchiectasis associated with azoospermia and sinusitis in males.

A	Allergic bronchopulmonary aspergillosis

There is no history suggestive of *Aspergillus* exposure. Sputum often comes up as 'plugs' in ABPA rather than being copious.

B	Asthma

The expiratory wheeze heard in this gentleman does not mean he has a diagnosis of asthma. Wheeze may be a feature of many respiratory diseases.

C	Bronchial obstruction

The chest radiograph shows widespread changes that are not consistent with a localised obstruction.

D	Tuberculosis

This is not a history of TB. The patient has recurrent chest infections and clearly has a long-standing condition. Chest radiography appearances are not consistent with TB.

70110

Rate this question:

Next Question

Previous Question | Tag Question

Feedback | End Session

Difficulty: Average

Peer Responses %

Session Progress

Responses Correct:	0
Responses Incorrect:	225
Responses Total:	225
Responses - % Correct:	0%

© Pastest 2017

A 30-year-old man presents with recurrent chest infections productive of copious amounts of green purulent sputum. He had recurrent ear infections as a child. He is a smoker of 30/day and is married with no children. On examination he is clubbed. Auscultation of his chest reveals coarse bi-basal crackles and an expiratory wheeze. Heart sounds are normal. Abdominal examination is unremarkable except for a scar in the left iliac fossa. His CXR is shown below.

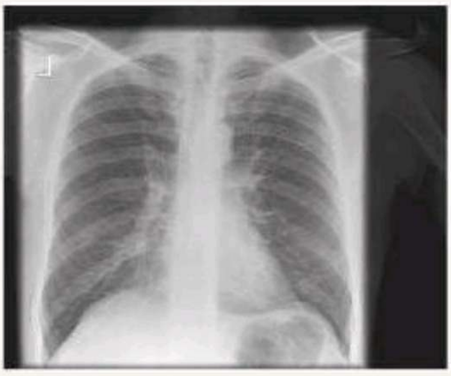

Which investigation would you do to confirm the suspected diagnosis?

A	*Aspergillus* precipitins
B	CT chest
C	High-resolution CT chest
D	Histamine challenge test
E	Sputum culture

70111

Submit

Previous Question | Skip Question

Calculator

Normal Values

© Pastest 2017

A 30-year-old man presents with recurrent chest infections productive of copious amounts of green purulent sputum. He had recurrent ear infections as a child. He is a smoker of 30/day and is married with no children. On examination he is clubbed. Auscultation of his chest reveals coarse bi-basal crackles and an expiratory wheeze. Heart sounds are normal. Abdominal examination is unremarkable except for a scar in the left iliac fossa. His CXR is shown below.

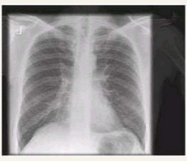

Which investigation would you do to confirm the suspected diagnosis?

A	*Aspergillus* precipitins
B	CT chest
C	High-resolution CT chest
D	Histamine challenge test
E	Sputum culture

Explanation

C	High-resolution CT chest

This man has bronchiectasis. Clinical features include recurrent chest infections with the production of copious amounts of mucopurulent sputum. Other symptoms include dyspnoea, wheeze and pleuritic chest pain. Patients are usually clubbed and course crackles are heard in affected areas.

Bronchiectasis is idiopathic in around 60% of cases, but there are many potential causes:

- Congenital (e.g. Marfans, Williams–Campbell syndrome
- Post infective (e.g. after measles, TB, pneumonia or pertussis)
- Immunodeficiency (e.g. HIV, haematological malignancy, post-transplantation)
- Allergic bronchopulmonary aspergillosis (bronchiectasisis, usually proximal)
- Cystic fibrosis
- Distal to an obstructed bronchus, e.g. from a tumour
- Complication sarcoidosis or pulmonary fibrosis (traction bronchiectasis)
- Mucociliary clearance defects: primary ciliary dyskinesia, Kartagner
- Alpha-1 anti-trypsin deficiency.

The investigation of choice is a high-resolution CT and is diagnostic in >90% of cases, demonstrating bronchial dilatation and wall thickening. Patients should have blood taken for immunoglobulin levels, functional antibodies and aspergillus serology. Based on clinical history, patients may require tests of ciliary function, cystic fibrosis genotyping or sweat testing, alpha-1 anti-trypsin levels or neutrophil function testing.

The unifying diagnosis is Kartagener syndrome – situs inversus, sinusitis and bronchiectasis. The clues are the appendicectomy scar in the left iliac fossa and the chest X-ray showing dextrocardia (note the 'L in reverse in the top right-hand corner of the radiograph). Diagnosis is confirmed with an epithelial (nasal or bronchial) brush or biopsy. These are examined to determine whether cilia demonstrate normal coordination, beat frequency and beat pattern. Cross-sections of the cilia are also examined by electron microscopy and specific defects of structure visualised, e.g. absence of dynein arms. Young syndrome is bronchiectasis associated with azoospermia and sinusitis in males.

A	*Aspergillus* precipitins

This would be an appropriate investigation as part of a work-up for bronchiectasis, but is not the most likely test to give the diagnosis here.

B	CT chest

A standard CT chest may not be of sufficiently high resolution to detect milder bronchiectasis – a HRCT is preferable.

D	Histamine challenge test

This is a test for asthma. The patient breathes in nebulised methacholine or histamine, which provokes bronchoconstriction. The degree of narrowing is then quantified by spirometry. People with asthma will have a greater degree of pre-existing airway hyper-reactivity and therefore require a lower dose of the drug.

E	Sputum culture

Sputum culture would be helpful in targeting any appropriate treatment for infection, but is not a specific test used to diagnose bronchiectasis.

70111

Rate this question:

Next Question

Previous Question | Tag Question

Feedback | End Session

Difficulty: Average

Peer Responses %

Session Progress

Responses Correct:	0
Responses Incorrect:	226
Responses Total:	226
Responses - % Correct:	0%

© Pastest 2017

A 32-year-old man presents with recurrent chest infections productive of copious amounts of green purulent sputum. He had recurrent ear infections as a child. He is a smoker of 20/day and is married with no children. On examination he is clubbed. Auscultation of his chest reveals coarse bi-basal crackles and an expiratory wheeze. Heart sounds are normal. Abdominal examination is unremarkable except for a scar in the left iliac fossa. His CXR is shown below.

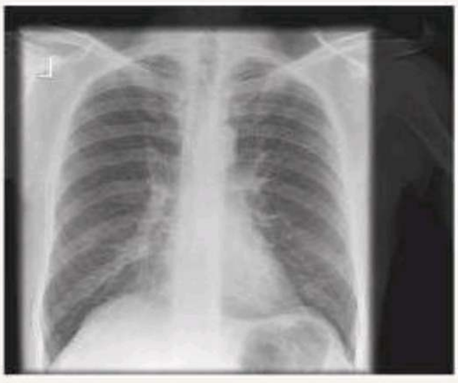

How would you confirm the suspected diagnosis?

A	Alpha-1-antitrypsin level
B	Serum immunoglobulins
C	Ciliary electron microscopy
D	Sweat test
E	Testing nasal potential differences

70113

Submit

Previous Question | Skip Question

Calculator

Normal Values

© Pastest 2017

A 32-year-old man presents with recurrent chest infections productive of copious amounts of green purulent sputum. He had recurrent ear infections as a child. He is a smoker of 20/day and is married with no children. On examination he is clubbed. Auscultation of his chest reveals coarse bi-basal crackles and an expiratory wheeze. Heart sounds are normal. Abdominal examination is unremarkable except for a scar in the left iliac fossa. His CXR is shown below.

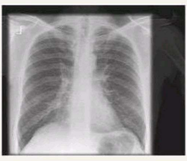

How would you confirm the suspected diagnosis?

A	Alpha-1-antitrypsin level
B	Serum immunoglobulins
C	Ciliary electron microscopy
D	Sweat test
E	Testing nasal potential differences

Explanation

C Ciliary electron microscopy

This man has bronchiectasis. Clinical features include recurrent chest infections with the production of copious amounts of mucopurulent sputum. Other symptoms include dyspnoea, wheeze and pleuritic chest pain. Patients are usually clubbed and course crackles are heard in affected areas.

Bronchiectasis is idiopathic in around 60% of cases but there are many potential causes:

- Congenital (e.g. Marfan, Williams–Campbell syndrome
- Post infective (e.g. after measles, TB, pneumonia or pertussis)
- Immunodeficiency (e.g. HIV, haematological malignancy, post-transplantation)
- Allergic bronchopulmonaryaspergillosis (bronchiectasisis usually proximal)
- Cystic fibrosis
- Distal to an obstructed bronchus, e.g. from a tumour
- Complicated sarcoidosis or pulmonary fibrosis (traction bronchiectasis)
- Mucociliary clearance defects: primary ciliary dyskinesia, Kartagner
- Alpha-1 anti-trypsin deficiency.

The investigation of choice is a high-resolution CT and is diagnostic in >90% of cases, demonstrating bronchial dilatation and wall thickening. Patients should have blood taken for immunoglobulin levels, functional antibodies and aspergillus serology. Based on clinical history, patients may require tests of ciliary function, cystic fibrosis genotyping or sweat testing, alpha-1 antitrypsin levels or neutrophil function testing.

The unifying diagnosis is Kartagener' syndrome – situs inversus, sinusitis and bronchiectasis. The clues are the appendicectomy scar in the left iliac fossa and the chest X-ray showing dextrocardia (note the 'L' in reverse in the top right-hand corner of the radiograph). Diagnosis is confirmed with an epithelial (nasal or bronchial) brush or biopsy. These are examined to determine whether cilia demonstrate normal c-ordination, beat frequency and beat pattern. Cross-sections of the cilia are also examined by electron microscopy and specific defects of structure visualised, e.g. absence of dynein arms. Young syndrome is bronchiectasis associated with azoospermia and sinusitis in males.

A Alpha-1-antitrypsin level

This would be an appropriate test to confirm alpha-1 antitrypsin deficiency. Patients with severe alpha-1 antitrypsin deficiency will have pan-acinar emphysema or COPD in adult life, especially if they are smokers.

B Serum immunoglobulins

These would be appropriate diagnostic tests to confirm hypogammoglobulinaemia. This is an immune disorder with a reduction in all types of gamma-globulins.

D Sweat test

This would be a test to confirm a diagnosis of cystic fibrosis. In the sweat test, this measures the amount of salt in sweat. Patients with cystic fibrosis have 2–5 times the amount of salt in sweat compared with normal people.

E Testing nasal potential differences

This is a test for cystic fibrosis. In nasal potential difference, the voltage across the nasal epithelium is measured, which results from transepithelial ion transport; this is affected in cystic fibrosis.

70113

Rate this question:

Next Question

Previous Question | Tag Question

Feedback | End Session

Difficulty: Average

Peer Responses %

Session Progress

Responses Correct:	0
Responses Incorrect:	227
Responses Total:	227
Responses - % Correct:	0%

© Pastest 2017

A 56-year-old man is referred to the outpatients department with a 2-year history of increasing breathlessness and deteriorating exercise tolerance. He has a non-productive cough and always feels tired, so much so that he has needed to ask his wife to help him look after his pigeons, which he has been racing for many years. Over the last year he has lost about 1 stone in weight. He has a past medical history of asthma as a child. In his social history, he has had no history of recent foreign travel, except to France. He has always worked in a bank and is an ex-smoker who drinks minimal amounts of alcohol. On examination he is not clubbed. On auscultation of his chest, he has fine inspiratory crackles.

ABGs on air reveal:

pH	7.36
PO_2	7.4 kPa
PCO_2	4.7 kPa

Lung function tests:

FEV_1	70% predicted
FVC	64% predicted
KCO	53% predicted
TLCO	55% predicted

His CXR is shown below;

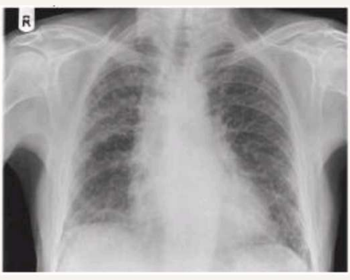

What is the most likely diagnosis?

A	Bronchopulmonary aspergillosis
B	Extrinsic allergic alveolitis
C	Idiopathic pulmonary fibrosis
D	Psittacosis
E	Sarcoidosis

70114

Submit

Previous Question | Skip Question

Calculator

Normal Values

© Pastest 2017

A 56-year-old man is referred to the outpatients department with a 2-year history of increasing breathlessness and deteriorating exercise tolerance. He has a non-productive cough and always feels tired, so much so that he has needed to ask his wife to help him look after his pigeons, which he has been racing for many years. Over the last year he has lost about 1 stone in weight. He has a past medical history of asthma as a child. In his social history, he has had no history of recent foreign travel, except to France. He has always worked in a bank and is an ex-smoker who drinks minimal amounts of alcohol. On examination he is not clubbed. On auscultation of his chest, he has fine inspiratory crackles.

ABGs on air reveal:

pH	7.36
PO_2	7.4 kPa
PCO_2	4.7 kPa

Lung function tests:

FEV_1	70% predicted
FVC	64% predicted
KCO	53% predicted
TLCO	55% predicted

His CXR is shown below;

What is the most likely diagnosis?

A	Bronchopulmonary aspergillosis
B	Extrinsic allergic alveolitis
C	Idiopathic pulmonary fibrosis
D	Psittacosis
E	Sarcoidosis

Explanation

B Extrinsic allergic alveolitis

The patient has interstitial lung disease, demonstrated by the slowly progressive shortness of breath, type I hypoxia and restrictive lung function tests with reduced TLCO and KCO. In the chest radiograph there is reticular nodular shadowing. The diagnosis is extrinsic allergic alveolitis secondary to pigeons – bird fancier's lung. This is caused by inhaled avian serum proteins (usually IgA) present in the pigeon's feathers and excreta. It is a hypersensitivity pneumonitis caused by a specific immunological response to inhaled organic dusts. EAA may present either as an acute or a chronic disease. Acute disease develops several hours after exposure to high concentrations of the allergen. Breathlessness and flu-like symptoms occur sometimes with headaches, fever and myalgia. Symptoms usually resolve within 48 h. The patient has chronic disease, as it has progressed to interstitial lung disease with fibrosis.

The diagnosis of extrinsic allergic alveolitis is made by:

- Identifying a potential source of antigen
- Characteristic clinical features: this patient has chronic EAA and presents with similar features to pulmonary fibrosis – clubbing tends to occur later (idiopathic pulmonary fibrosis would typically be associated with clubbing)
- Characteristic radiology (usually upper lobe fibrosis)
- Lung function tests – showing a restrictive defect with reduced carbon monoxide gas transfer
- Demonstrating precipitating antibodies (precipitins) in the patient's serum
- Resolution or improvement of symptoms following avoidance of exposure to the cause
- Histology of lung tissue biopsy showing a mononuclear cell infiltrate with the formation of non-caseating granulomas
- Fluid obtained from bronchoalveloar lavage has a high lymphocyte count (typically >40%).

Treatment is avoidance of the antigen. Corticosteroids may improve recovery in acute attacks but do not seem to provide long-term benefit. They are not usually helpful once fibrosis has occurred.

Other causes of EAA include:

- Farmer's lung, due to *Micropolyspora faeni* and *Thermactinomyces* in mouldy hay, straw and grain
- Bagassosis due to *Thermactinomyces sacchari* in sugar cane processing
- Malt worker's lung due to *Aspergillus clavatus*
- Mushroom worker's lung due to thermophilic actinomycetes
- Ventilation and water-related contamination, e.g. due to thermophilic actinomycetes contaminating air-conditioning systems
- Veterinary workers and animal handlers
- Workers in milling and construction, e.g. wood dust pneumonitis due to *Alternaria* spp.

Causes of upper-zone fibrosis:

- Progressive massive fibrosis/coal worker's pneumoconiosis
- Ankylosing spondylitis
- Sarcoid/silicosis
- Tuberculosis
- Extrinsic allergic alveolitis
- Radiation (depending on site).

A Bronchopulmonary aspergillosis

The chest radiograph shows diffuse infiltrates. CXR findings in ABPA are more likely to include proximal bronchiectasis, lobar collapse or discrete pulmonary infiltates.

C Idiopathic pulmonary fibrosis

There is a clear precipitant to interstitial lung disease here.

D Psittacosis

Psittacosis is an infection caused by *Chlamydia psittacosis*. It usually presents with a sudden onset of fever, dry cough and headache following a recent exposure to birds. Psittacosis is typically linked to parrots. The duration of symptoms is too long for psittacosis, and the chest X-ray changes are too widespread.

E Sarcoidosis

Exposure to pigeons and weight loss make EAA more likely than sarcoidosis.

7014

Rate this question:

Next Question

Previous Question | Tag Question

Feedback | End Session

Difficulty: Average

Peer Responses %

Session Progress

Responses Correct:	0
Responses Incorrect:	228
Responses Total:	228
Responses - % Correct:	0%

Blog About Pastest Contact Us Help

© Pastest 2017

A 56-year-old man is referred to the outpatients department with a 2-year history of increasing breathlessness and deteriorating exercise tolerance. He has a non-productive cough and always feels tired, so much so that he has needed to ask his wife to help him look after his pigeons, which he has been racing for many years. Over the last year he has lost about 1 stone in weight. He has a past medical history of asthma as a child. In his social history, he has had no history of recent foreign travel, except to France. He has always worked in a bank and is an ex-smoker who drinks minimal amounts of alcohol. On examination he is not clubbed. On auscultation of his chest, he has fine inspiratory crackles.

ABGs on air reveal:

pH	7.36
PO_2	7.4 kPa
PCO_2	4.7 kPa

Lung function tests:

FEV_1	70% predicted
FVC	64% predicted
KCO	53% predicted
TLCO	55% predicted

His CXR is shown below;

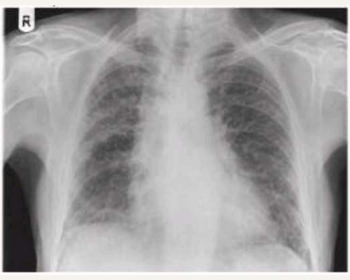

Which of the following would help make a diagnosis?

A	*Aspergillus fumigatus* precipitins
B	Avian serum precipitins
C	Blood cultures
D	Bronchoscopy
E	Serum ACE

70115

Submit

Previous Question | Skip Question

Calculator

Normal Values

© Pastest 2017

A 56-year-old man is referred to the outpatients department with a 2-year history of increasing breathlessness and deteriorating exercise tolerance. He has a non-productive cough and always feels tired, so much so that he has needed to ask his wife to help him look after his pigeons, which he has been racing for many years. Over the last year he has lost about 1 stone in weight. He has a past medical history of asthma as a child. In his social history, he has had no history of recent foreign travel, except to France. He has always worked in a bank and is an ex-smoker who drinks minimal amounts of alcohol. On examination he is not clubbed. On auscultation of his chest, he has fine inspiratory crackles.

ABGs on air reveal:

pH	7.36
PO_2	7.4 kPa
PCO_2	4.7 kPa

Lung function tests:

FEV_1	70% predicted
FVC	64% predicted
KCO	53% predicted
TLCO	55% predicted

His CXR is shown below;

Which of the following would help make a diagnosis?

A	*Aspergillus fumigatus* precipitins
B	Avian serum precipitins
C	Blood cultures
D	Bronchoscopy
E	Serum ACE

Explanation

B Avian serum precipitins

The patient has interstitial lung disease, demonstrated by the slowly progressive shortness of breath, type I hypoxia and restrictive lung function tests with reduced TLCO and KCO. The chest radiograph shows reticular nodular shadowing. The diagnosis is extrinsic allergic alveolitis secondary to pigeons – bird fancier's lung. This is caused by inhaled avian serum proteins (usually IgA) present in the pigeon's feathers and excreta. It is a hypersensitivity pneumonitis caused by a specific immunological response to inhaled organic dusts.

EAA may present either as an acute or a chronic disease. Acute disease develops several hours after exposure to high concentrations of the allergen. Breathlessness and flu-like symptoms occur sometimes with headaches, fever and myalgia. Symptoms usually resolve within 48 h. The patient has chronic disease as it has progressed to interstitial lung disease with fibrosis.

The diagnosis of extrinsic allergic alveolitis is made by:

- Identifying a potential source of antigen
- Characteristic clinical features: this patient has chronic EAA and presents with similar features to pulmonary fibrosis – clubbing tends to occur later (idiopathic pulmonary fibrosis would typically be associated with clubbing)
- Characteristic radiology (usually upper lobe fibrosis)
- Lung function tests – showing a restrictive defect with reduced carbon monoxide gas transfer
- Demonstrating precipitating antibodies (precipitins) in the patient's serum
- Resolution or improvement of symptoms following avoidance of exposure to the cause
- Histology of lung tissue biopsy showing a mononuclear cell infiltrate with the formation of non-caseating granulomas
- Fluid obtained from bronchoalveloar lavage has a high lymphocyte count (typically >40%).

Treatment is avoidance of the antigen. Corticosteroids may improve recovery in acute attacks but do not seem to provide long-term benefit. They are not usually helpful once fibrosis has occurred.

Other causes of EAA include:

- Farmer's lung, due to *Micropolyspora faeni* and *Thermactinomyces* in mouldy hay, straw and grain
- Bagassosis due to *Thermactinomyces sacchari* in sugar cane processing
- Malt worker's lung due to *Aspergillus clavatus*
- Mushroom worker's lung due to thermophilic actinomycetes
- Ventilation and water-related contamination, e.g. due to thermophilic actinomycetes contaminating air-conditioning systems
- Veterinary workers and animal handlers
- Workers in milling and construction, e.g. wood dust pneumonitis due to *Alternaria* spp.

Causes of upper-zone fibrosis:

- Progressive massive fibrosis/coal worker's pneumoconiosis
- Ankylosing spondylitis
- Sarcoid/silicosis
- Tuberculosis
- Extrinsic allergic alveolitis
- Radiation (depending on site).

A *Aspergillus fumigatus* precipitins

This is a test for *Aspergillus* lung disease.

C Blood cultures

There is nothing to suggest sepsis here.

D Bronchoscopy

Bronchoscopy may be helpful as part of the work-up here, but is not the test most likely to give the correct diagnosis.

E Serum ACE

This is not a specific test for any condition, but may be raised in sarcoidosis and TB.

70115

Rate this question:

Next Question

Previous Question | Tag Question

Feedback | End Session

Difficulty: Average

Peer Responses %

Session Progress

Responses Correct:	0
Responses Incorrect:	229
Responses Total:	229
Responses - % Correct:	0%

Blog About Pastest Contact Us Help

© Pastest 2017

A 90-year-old man was referred to the clinic with a history of progressive shortness of breath and dry cough. Eighteen months ago he was able to complete a full round of golf. He has now stopped playing as he is breathless after walking 200 m. He had been a heavy smoker all his life. He has no known asbestos exposure. On examination he is breathless at rest. He has a photosensitive rash on his face and neck. He is clubbed. His pulse is irregularly irregular. Auscultation of his chest reveals fine inspiratory crackles bi-basally.

Investigations:

Hb	12.1 g/dl
WCC	9.2×10^9/l
Neutrophils	6.1×10^9/l
PLT	203×10^9/l
TSH	7.1 mU/l

Blood gases on 30% oxygen:

pH	7.46
PCO_2	4.68 kPa
PO_2	8.8 kPa
Bicarbonate	25.4 mmol/l

His CXR is shown below:

Spirometry:

FEV_1	1.1 L (predicted 2.0 – 2.4 L)
FVC	2.0 L (predicted 3.2 – 3.8 L)
KCO	74% predicted

What is the likely cause of his breathlessness?

A	Bronchial alveolar carcinoma
B	Interstitial lung disease
C	COPD
D	Lymphangioleiomyomatosis
E	Pulmonary oedema

70116

Submit

Previous Question | Skip Question

Calculator

Normal Values

© Pastest 2017

A 90-year-old man was referred to the clinic with a history of progressive shortness of breath and dry cough. Eighteen months ago he was able to complete a full round of golf. He has now stopped playing as he is breathless after walking 200 m. He had been a heavy smoker all his life. He has no known asbestos exposure. On examination he is breathless at rest. He has a photosensitive rash on his face and neck. He is clubbed. His pulse is irregularly irregular. Auscultation of his chest reveals fine inspiratory crackles bi-basally.

Investigations:

Hb	12.1 g/dl
WCC	9.2×10^9/l
Neutrophils	6.1×10^9/l
PLT	203×10^9/l
TSH	7.1 mU/l

Blood gases on 30% oxygen:

pH	7.46
PCO_2	4.68 kPa
PO_2	8.8 kPa

Bicarbonate	25.4 mmol/l

His CXR is shown below:

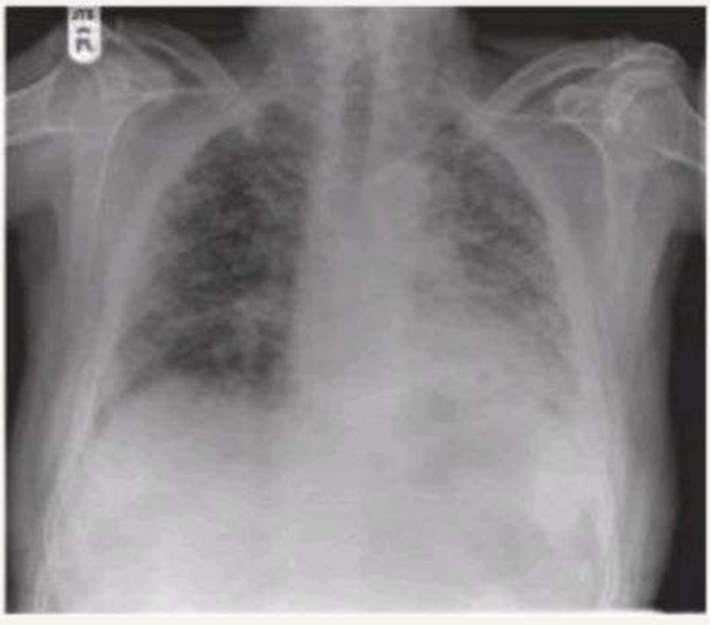

Spirometry:

FEV_1	1.1 L (predicted 2.0 – 2.4 L)
FVC	2.0 L (predicted 3.2 – 3.8 L)
KCO	74% predicted

What is the likely cause of his breathlessness?

A	Bronchial alveolar carcinoma
B	Interstitial lung disease
C	COPD
D	Lymphangioleiomyomatosis
E	Pulmonary oedema

Explanation

B	Interstitial lung disease

This man has interstitial lung disease – gradual onset of shortness breath and dry cough. He is clubbed and has fine inspiratory crackles. Lung function tests are restrictive and he has type I respiratory failure. Chest radiograph shows small lung fields and reticular nodular shadowing.

The patient has a photosensitive rash on his face, atrial fibrillation and abnormal thyroid function, suggesting that he is on amiodarone. Interstitial lung disease is an important side effect of long-term amiodarone administration. Pulmonary fibrosis is a known side effect of several other drugs, including beta blockers, nirofurantoin and methotrexate.

Diagnosis is made by a combination of clinical findings, lung function tests, CXR, BAL and high-resolution CT. It is confirmed with a VATS or an open lung biopsy in patients fit to undergo the procedure.

If there was no obvious cause for the interstitial lung disease and radiology and biopsy histology were consistent with usual interstitial pneumonia, then idiopathic pulmonary fibrosis would be the most likely diagnosis.

Interstitial lung disease is an important side effect of long-term amiodarone administration.

Other side effects of amiodarone include:

- Hyper- and hypothyroidism
- Peripheral sensory neuropathy
- Hepatitis
- Photosensitivity
- Ataxia
- Corneal microdeposits (reversible)
- Metallic taste

- Arrhythmias (torsade de pointes).

Drugs causing interstitial lung disease:

- Antibiotics – nitrofurantoin
- Cardiovascular – amiodarone, beta-blockers
- Chemotherapeutic – bleomycin, busulfan, cyclophosphamide, carmustine, lomustine, methotrexate, melphalan, mitomycin C, nitrosureas, sulfasalazine, 5-fluorouracil (5FU)
- Drugs used to treat rheumatoid arthritis – sulfasalazine, penicillamine, cyclophosphamide, methotrexate, gold
- Drugs used to treat migraine – ergotamine, ergots, methysergide
- Others:
  bromocriptine
  radiation
  dothiepin
  pesticides
  high-flow oxygen.

Causes of lower interstitial lung disease:

- Drugs
- Connective tissue disease
- Asbestosis
- Idiopathic pulmonary fibrosis.

A	Bronchial alveolar carcinoma

The duration of symptoms is too long for bronchoalveolar cell carcinoma, and this is usually associated with a productive cough with frothy sputum. The chest radiograph shows interstitial lung disease.

C	COPD

His CXR clearly shows there is more going on than COPD.

D	Lymphangioleiomyomatosis

This condition usually affects women in their childbearing years and is associated with cystic destruction of the lungs.

E	Pulmonary oedema

This is a reasonable differential diagnosis based on the history, but the chest radiograph shows interstitial lung disease, not pulmonary oedema.

70116

Rate this question:

Next Question

Previous Question | Tag Question

Feedback | End Session

Difficulty: Average

Peer Responses %

Session Progress

Responses Correct:	0
Responses Incorrect:	230
Responses Total:	230
Responses - % Correct:	0%

© Pastest 2017

A 90-year-old man was referred to the clinic with a history of progressive shortness of breath and dry cough. Eighteen months ago he was able to complete a full round of golf. He has now stopped playing as he is breathless after walking 200 m. He had been a heavy smoker all his life. He has no known asbestos exposure. On examination he is breathless at rest. He has a photosensitive rash on his face and neck. He is clubbed. His pulse is irregularly irregular. Auscultation of his chest reveals fine inspiratory crackles bi-basally.

Investigations:

Hb	12.1 g/dl
WCC	9.2×10^9/l
Neutrophils	6.1×10^9/l
PLT	203×10^9/l
TSH	7.1 mU/l

Blood gases on 30% oxygen:

pH	7.48
pCO_2	4.68 kPa
pO_2	8.8 kPa
Bicarbonate	25.4 mmol/l

His CXR is shown below:

Spirometry:

FEV_1	1.1 l (predicted 2.0 – 2.4 l)
FVC	2.0 l (predicted 3.2 – 3.8 l)
KCO	74% predicted

What is the likely cause of the suspected diagnosis?

A	Rheumatoid arthritis
B	Amiodarone
C	Pesticides
D	Sarcoidosis
E	Smoking

70117

Submit

Previous Question | Skip Question

Calculator

Normal Values

© Pastest 2017

A 90-year-old man was referred to the clinic with a history of progressive shortness of breath and dry cough. Eighteen months ago he was able to complete a full round of golf. He has now stopped playing as he is breathless after walking 200 m. He had been a heavy smoker all his life. He has no known asbestos exposure. On examination he is breathless at rest. He has a photosensitive rash on his face and neck. He is clubbed. His pulse is irregularly irregular. Auscultation of his chest reveals fine inspiratory crackles bi-basally.

Investigations:

Hb	12.1 g/dl
WCC	9.2 × 10^9/l
Neutrophils	6.1 × 10^9/l
PLT	203 × 10^9/l
TSH	7.1 mU/l

Blood gases on 30% oxygen:

pH	7.48
pCO_2	4.68 kPa
pO_2	8.8 kPa
Bicarbonate	25.4 mmol/l

His CXR is shown below:

Spirometry:

FEV_1	1.1 l (predicted 2.0 – 2.4 l)
FVC	2.0 l (predicted 3.2 – 3.8 l)
KCO	74% predicted

What is the likely cause of the suspected diagnosis?

A Rheumatoid arthritis

B Amiodarone

C Pesticides

D Sarcoidosis

E Smoking

Explanation

B Amiodarone

This man has interstitial lung disease – gradual onset of shortness breath and dry cough. He is clubbed and has fine inspiratory crackles. Lung function tests are restrictive and he has type I respiratory failure. The chest radiograph shows small lung fields and reticular nodular shadowing.

Next you have to look for a cause. He has a photosensitive rash on his face, atrial fibrillation and abnormal thyroid function, suggesting that he is on amiodarone. Interstitial lung disease is an important side effect of long-term amiodarone administration.

Other side effects of amiodarone include:

- Hyper- and hypothyroidism
- Peripheral sensory neuropathy
- Hepatitis
- Photosensitivity
- Ataxia
- Corneal micro-deposits (reversible)
- Metallic taste
- Arrhythmias (torsade de pointes): a number of drugs cause pulmonary fibrosis – see below.

Diagnosis is made by a combination of clinical findings, lung function tests, CXR, BAL and high-resolution CT. It is confirmed with a VATS or an open lung biopsy in patients fit to undergo the procedure.

If there was no obvious cause for the interstitial lung disease and radiology and biopsy histology were consistent with usual interstitial pneumonia, then idiopathic pulmonary fibrosis would be the most likely diagnosis.

Drugs causing interstitial lung disease:

- Antibiotics – nitrofurantoin
- Cardiovascular – amiodarone, beta-blockers
- Chemotherapeutic – bleomycin, busulfan, cyclophosphamide, carmustine, lomustine, methotrexate, melphalan, mitomycin C, nitrosureas, sulfasalazine, 5-fluorouracil (5FU)
- Drugs used to treat rheumatoid arthritis – sulfasalazine, penicillamine, cyclophosphamide, methotrexate, gold
- Drugs used to treat migraine – ergotamine, ergots, methysergide
- Others:
  bromocriptine
  radiation
  dothiepin
  pesticides
  high-flow oxygen.

Causes of lower interstitial lung disease:

- Drugs
- Connective tissue disease
- Asbestosis
- Idiopathic pulmonary fibrosis.

A Rheumatoid arthritis

There is nothing in the history to suggest RA. Rheumatoid arthritis resulting in interstitial lung disease can cause shortness of breath, chronic dry cough, fatigue and weakness. There may be lung nodules.

C Pesticides

It is more likely that the ILD has been caused by amiodarone, given the patient's sun-exposed rash.

D Sarcoidosis

This is not sarcoidosis, the presentation of which would be very unusual at this age. When sarcoidosis affects the lungs there is a collection of inflammatory cells forming lumps known as granulomas. This may present with wheezing, cough, shortness of breath or chest pain. Lofgren syndrome is where there is fever, lymphadenopathy, arthritis and erythema nodosum.

E Smoking

Amiodarone is more likely to cause ILD than smoking. Smoking is associated with desquamative interstitial pneumonia, but the history and age of the patient are against this.

2017

Rate this question:

Next Question

Previous Question | Tag Question

Feedback | End Session

Difficulty: Average

Peer Responses %

Session Progress

Responses Correct:	0
Responses Incorrect:	231
Responses Total:	231
Responses - % Correct:	0%

Blog About Pastest Contact Us Help

© Pastest 2017

A 25-year-old man presents with left-sided pleuritic chest pain that come on suddenly 3 days previously. Initially he thought it was secondary to his workout in the gym. However, since it did not improve and he noticed that he was slightly more breathless than usual, he went to the Emergency Department. He has no significant past medical history. He is a smoker of 20/day. On examination he looked well. He was a tall, thin man and was not short of breath at rest. Examination was unremarkable except for a clicking sound which was synchronous with the heart sounds. CXR was unremarkable.

What is the diagnosis?

A	Mitral valve prolapse
B	Pericarditis
C	Primary pneumothorax
D	Pleurisy
E	Secondary pneumothorax

70118

Submit

Previous Question | Skip Question

Calculator

Normal Values

Blog About Pastest Contact Us Help

© Pastest 2017

A 25-year-old man presents with left-sided pleuritic chest pain that come on suddenly 3 days previously. Initially he thought it was secondary to his workout in the gym. However, since it did not improve and he noticed that he was slightly more breathless than usual, he went to the Emergency Department. He has no significant past medical history. He is a smoker of 20/day. On examination he looked well. He was a tall, thin man and was not short of breath at rest. Examination was unremarkable except for a clicking sound which was synchronous with the heart sounds. CXR was unremarkable.

What is the diagnosis?

A	Mitral valve prolapse
B	Pericarditis
C	Primary pneumothorax
D	Pleurisy
E	Secondary pneumothorax

Explanation

C	Primary pneumothorax

A click synchronous with the heart sounds is a recognised sign of a small left apical pneumothorax. He is a tall, thin man and a smoker, which are both risk factors for developing a pneumothorax. There is a strong association between pneumothoraces and smoking. The most recent British Thoracic Society (BTS) guidelines suggest that if the postero-anterior (PA) chest X-ray is normal and a small pneumothorax is suspected, a lateral decubitus chest X-ray provides added information in up to 14% of cases (see weblink below). Expiratory films add little and are not recommended.

The treatment of a primary pneumothorax in a non-smoker, <50 years old, with no evidence of underlying lung disease, with a rim of air of <2 cm and no breathlessness is to discharge and follow up as an outpatient. Although this patient is a smoker there is nothing to suggest underlying lung disease, and it is likely that his apical pneumothorax is too small to safely aspirate. Patients should be given analgesia if required and clear instructions to return if their symptoms get any worse.

A	Mitral valve prolapse

This is associated with a mid- to late systolic click. It occurs when there is an abnormally thickened mitral valve leaflet that displaces into the left atrium during systole.

B	Pericarditis

The patient has pleuritic, not pericarditic, chest pain. Pericarditis typically causes symptoms that include sudden onset of sharp chest pain. The pain may be felt in the shoulders, neck or back. It is typically relieved by sitting up and worse when lying down or deep inspiration. Other symptoms include fever, weakness, palpitations or dyspnoea.

D	Pleurisy

Onset was sudden and not associated with infective symptoms. Pleurisy results in a sharp chest pain on breathing. Other symptoms include breathlessness, cough, fever and weight loss.

E	Secondary pneumothorax

There is no history of underlying lung disease. Secondary pneumothorax is defined as pneumothorax that occurs in the presence of underlying lung disease. This is in contrast to primary pneumothorax, where there is no lung disease.

70118

Rate this question:

Next Question

Previous Question | Tag Question

Feedback | End Session

Difficulty: Average

Peer Responses %

Session Progress

Responses Correct:	0
Responses Incorrect:	232
Responses Total:	232
Responses - % Correct:	0%

External Links

BTS Pleural Disease Guideline 2010
brit-thoracic.org.uk/document-library/clinical-information/pleural-disease/pleural-dis...

© Pastest 2017

A 25-year-old man presents with left-sided pleuritic chest pain. It had come on suddenly 3 days previously. Initially he thought it was secondary to his workout in the gym. However, since it did not improve and he noticed that he was slightly more breathless than usual, he went to the Emergency Department. He has no significant past medical history. He is a smoker of 20/day. On examination he looked well. He was a tall, thin man and was not short of breath at rest. Examination was unremarkable except for a clicking sound which was synchronous with the heart sounds. CXR was unremarkable.

Which of the following investigations may help with the diagnosis?

A	ECG
B	Echocardiogram
C	Expiratory CXR
D	Lateral decubitus CXR
E	Repeat CXR

70119

Submit

Previous Question | Skip Question

Calculator

Normal Values

Blog About Pastest Contact Us Help

© Pastest 2017

A 25-year-old man presents with left-sided pleuritic chest pain. It had come on suddenly 3 days previously. Initially he thought it was secondary to his workout in the gym. However, since it did not improve and he noticed that he was slightly more breathless than usual, he went to the Emergency Department. He has no significant past medical history. He is a smoker of 20/day. On examination he looked well. He was a tall, thin man and was not short of breath at rest. Examination was unremarkable except for a clicking sound which was synchronous with the heart sounds. CXR was unremarkable.

Which of the following investigations may help with the diagnosis?

A	ECG
B	Echocardiogram
C	Expiratory CXR
D	Lateral decubitus CXR
E	Repeat CXR

Explanation

D	Lateral decubitus CXR

A click synchronous with the heart sounds is a recognised sign of a small left apical pneumothorax. He is a tall, thin man and a smoker, which are both risk factors for developing a pneumothorax. There is a strong association between pneumothoraces and smoking. The most recent British Thoracic Society (BTS) guidelines suggest that if the postero-anterior (PA) chest X-ray is normal and a small pneumothorax is suspected, a lateral decubitus chest X-ray provides added information in up to 14% of cases (see weblink below). Expiratory films add little and are not recommended.

The treatment of a primary pneumothorax in a non-smoker, <50 years old, with no evidence of underlying lung disease, with a rim of air of <2 cm and no breathlessness is to discharge and follow up as an outpatient. Although this patient is a smoker there is nothing to suggest underlying lung disease, and it is likely that his apical pneumothorax is too small to safely aspirate. Patients should be given analgesia if required and clear instructions to return if their symptoms get any worse.

A	ECG

BTS guidelines recommend the use of lateral decubitus CXR. ECG may be abnormal in pneumothorax, which may include abnormal left axis deviation and right axis deviation. There may be QRS abnormalities as well.

B	Echocardiogram

BTS guidelines recommend the use of lateral decubitus CXR. Ultrasound may be useful in diagnosing traumatic pneumothorax, and the cardiac function may be affected by expanding pneumothorax.

C	Expiratory CXR

BTS guidelines recommend the use of lateral decubitus CXR. Expiration results in the lung reducing in volume, becoming more dense and making pneumothorax easier to identify.

E	Repeat CXR

BTS guidelines recommend the use of lateral decubitus CXR. Repeating a CXR will not help as the CXR may look the same.

70119

Rate this question:

Next Question

Previous Question | Tag Question

Feedback | End Session

Difficulty: Average

Peer Responses %

Session Progress

Responses Correct:	0
Responses Incorrect:	233
Responses Total:	233
Responses - % Correct:	0%

External Links

BTS Pleural Disease Guideline 2010
brit-thoracic.org.uk/document-library/clinical-information/pleural-disease/pleural-dis...

© Pastest 2017

A 25-year-old man presents with left-sided pleuritic chest pain. It had come on suddenly 3 days previously. Initially he thought it was secondary to his workout in the gym. However, since it did not improve and he noticed that he was slightly more breathless than usual, he went to the Emergency Department. He has no significant past medical history. He is a smoker of 20/day. On examination he looked well. He was a tall, thin man and was not short of breath at rest. Examination was unremarkable except for a clicking sound which was synchronous with the heart sounds. CXR was unremarkable.

How would you best manage this patient?

A	Analgesia and discharge with follow-up in the clinic
B	Aspiration of chest
C	Chest drain insertion
D	Non-steroidal anti-inflammatory drugs and admit patient
E	Refer to Cardiology Department

70120

Submit

Previous Question | Skip Question

Calculator

Normal Values

© Pastest 2017

A 25-year-old man presents with left-sided pleuritic chest pain. It had come on suddenly 3 days previously. Initially he thought it was secondary to his workout in the gym. However, since it did not improve and he noticed that he was slightly more breathless than usual, he went to the Emergency Department. He has no significant past medical history. He is a smoker of 20/day. On examination he looked well. He was a tall, thin man and was not short of breath at rest. Examination was unremarkable except for a clicking sound which was synchronous with the heart sounds. CXR was unremarkable.

How would you best manage this patient?

A	Analgesia and discharge with follow-up in the clinic
B	Aspiration of chest
C	Chest drain insertion
D	Non-steroidal anti-inflammatory drugs and admit patient
E	Refer to Cardiology Department

Explanation

A Analgesia and discharge with follow-up in the clinic

A synchronous click with the heart sounds is a recognised sign of a small left apical pneumothorax. He is a tall thin man and a smoker, which are both risk factors for developing a pneumothorax. There is a strong association between pneumothoraces and smoking. The most recent British Thoracic Society (BTS) guidelines[1], suggest that if the postero-anterior (PA) chest X-ray is normal and a small pneumothorax is suspected, a lateral decubitus chest X-ray provides added information in up to 14% of cases. Expiratory films add little and are not recommended. The treatment of a primary pneumothorax in a non smoker with no evidence of underlying lung disease <50yrs old with a rim of air of <2 cm and no breathlessness is to discharge and follow up as an outpatient. Although this patient is a smoker there is nothing to suggest underlying lung disease and it is like that his apical pneumothorax is too small to safely aspirate. Patients should be given analgesia if required and clear instructions to return if their symptoms get any worse.

[1]https://www.brit-thoracic.org.uk/document-library/clinical-information/pleural-disease/pleural-disease-guidelines-2010/appendix-3-spontaneous-pneumothorax-poster-pleural-disease-guideline/

B Aspiration of chest

There is no clinical indication to admit this patient, although he should be followed up as an outpatient.

C Chest drain insertion

There is no indication to aspirate a small pneumothorax in a young patient with no lung disease who is not breathless when reviewed.

D Non-steroidal anti-inflammatory drugs and admit patient

There is no indication insert a chest drain in a small pneumothorax in a young patient with no lung disease who is not breathless when reviewed.

E Refer to Cardiology Department

This would not be helpful in diagnosing pneumothorax.

70120

Rate this question:

Next Question

Previous Question | Tag Question

Feedback | End Session

Difficulty: Average

Peer Responses %

Session Progress

Responses Correct:	0
Responses Incorrect:	234
Responses Total:	234
Responses - % Correct:	0%

External Links

BTS Pleural Disease Guideline 2010
brit-thoracic.org.uk/document-library/clinical-information/pleural-disease/pleural-dis...

© Pastest 2017

A 60-year-old man with known emphysema presented to the Emergency Department with sudden onset of severe left-sided pleuritic chest pain and shortness of breath. He is a smoker of 20/day. On examination he looks unwell. He is pale and sweaty. BP 140/85 mmHg, pulse 120/min, respiratory rate 30/min, SaO_2 88% on air. He has reduced expansion and reduced breath sounds on the left side. Heart sounds were normal and abdominal examination unremarkable.

ABGs on air:

pH	7.41
PO_2	7.5 kPa
PCO_2	6.5 kPa

His CXR is shown below;

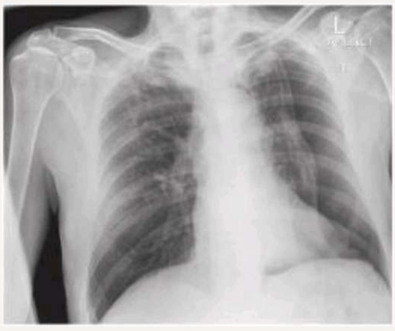

He is given 28% oxygen and analgesia and his saturations improve.

What would your immediate management of this patient be?

A	Chest aspiration
B	Insertion of an intercostal chest drain
C	Arrange an urgent CT scan of the chest
D	Refer to the thoracic surgeons
E	Insertion of an intercostal tube and apply suction

70121

Submit

Previous Question | Skip Question

Calculator

Normal Values

© Pastest 2017

A 60-year-old man with known emphysema presented to the Emergency Department with sudden onset of severe left-sided pleuritic chest pain and shortness of breath. He is a smoker of 20/day. On examination he looks unwell. He is pale and sweaty. BP 140/85 mmHg, pulse 120/min, respiratory rate 30/min, SaO_2 88% on air. He has reduced expansion and reduced breath sounds on the left side. Heart sounds were normal and abdominal examination unremarkable.

ABGs on air:

pH	7.41
PO_2	7.5 kPa
PCO_2	6.5 kPa

His CXR is shown below;

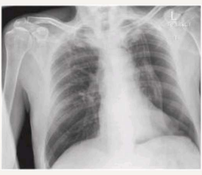

He is given 28% oxygen and analgesia and his saturations improve.

What would your immediate management of this patient be?

A	Chest aspiration
B	Insertion of an intercostal chest drain
C	Arrange an urgent CT scan of the chest
D	Refer to the thoracic surgeons
E	Insertion of an intercostal tube and apply suction

Explanation

B Insertion of an intercostal chest drain

This man has a secondary pneumothorax as he has underlying lung disease. The management is different for primary (no underlying pulmonary disease) and secondary (underlying pulmonary disease) pneumothoraces. Current guidelines[1] suggest that an intercostal drain should be inserted if the patient is breathless, over 50 years old with a significant smoking history and there is a rim of air of > 2 cm from the chest wall on a standard size chest X-ray. This patient fits all the above criteria.

Suction should not be applied immediately and it is recommended that it should not be routinely employed. It maybe considered after 48 hours whilst awaiting surgical review if the lung is not fully re-expanded or if there is a persistent air leak. Suction should be low-pressure (-10 to -20 cmH_2O), high-volume.

Because this patient has a persistent air leak at 4 days, despite suction, they should be referred to the thoracic surgeons. The exact timing of referral remains contentious but it is suggested that in cases of persistent air leak or failure of the lung to re-expand, an early (3-5 days) thoracic surgical opinion should be sought.

For secondary pneumothoraces, an early thoracic surgical referral is recommended.

[1]http:www.brit-thoracic.org.uk
https://www.brit-thoracic.org.uk/document-library/clinical-information/pleural-disease/pleural-disease-guidelines-2010/pleural-disease-guideline-quick-reference-guide/

A Chest aspiration

Chest aspiration should only be considered for a secondary pneumothorax <2cm if the patient is clinically stable.

C Arrange an urgent CT scan of the chest

A CT is not required here, the diagnosis of pneumothorax is clearly visible on CXR.

D Refer to the thoracic surgeons

It would be appropriate to try and resolve pneumothorax with an intercostal drain before assessing whether a surgical referral is required.

E Insertion of an intercostal tube and apply suction

Suction should be applied with caution due to risk of re-expansion pulmonary oedema. It should only be applied after consideration and specialist advice and monitoring.

7.0.12.1

Rate this question:

Next Question

Previous Question | Tag Question

Feedback | End Session

Difficulty: Average

Peer Responses %

Session Progress

Responses Correct:	0
Responses Incorrect:	235
Responses Total:	235
Responses - % Correct:	0%

© Pastest 2017

A 60-year-old man with known emphysema presented to the Emergency Department with sudden onset of severe left-sided pleuritic chest pain and shortness of breath. He is a smoker of 20/day. On examination he looks unwell. He is pale and sweaty. BP 140/85 mmHg, pulse 120/min, respiratory rate 30/min, SaO_2 88% on air. He has reduced expansion and reduced breath sounds on the left side. Heart sounds were normal and abdominal examination unremarkable.

ABGs on air:

pH	7.41
PO_2	7.5 kPa
PCO_2	6.5 kPa

His CXR is shown below;

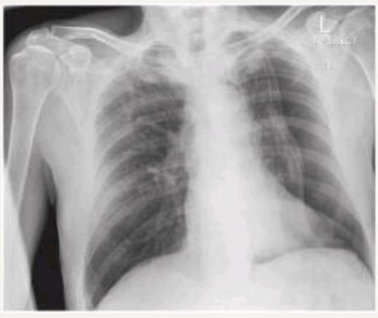

He is given 28% oxygen and analgesia and his saturations improve.

Following appropriate treatment, after 4 days the lung is fully re-expanded. A chest drain has been inserted and is swinging and there is a persistent air leak despite suction (pressure -20 cm H_2O).

What would you do next?

A	Insert another chest drain
B	Increase suction pressure to -30 cm H_2O
C	Refer to thoracic surgeons
D	Arrange a CT scan of the chest
E	Wait another 4 days

70122

Submit

Previous Question | Skip Question

Calculator

Normal Values

© Pastest 2017

A 60-year-old man with known emphysema presented to the Emergency Department with sudden onset of severe left-sided pleuritic chest pain and shortness of breath. He is a smoker of 20/day. On examination he looks unwell. He is pale and sweaty. BP 140/85 mmHg, pulse 120/min, respiratory rate 30/min, SaO_2 88% on air. He has reduced expansion and reduced breath sounds on the left side. Heart sounds were normal and abdominal examination unremarkable.

ABGs on air:

pH	7.41
PO_2	7.5 kPa
PCO_2	6.5 kPa

His CXR is shown below;

He is given 28% oxygen and analgesia and his saturations improve.

Following appropriate treatment, after 4 days the lung is fully re-expanded. A chest drain has been inserted and is swinging and there is a persistent air leak despite suction (pressure -20 cm H_2O).

What would you do next?

A	Insert another chest drain
B	Increase suction pressure to -30 cm H_2O
C	Refer to thoracic surgeons
D	Arrange a CT scan of the chest
E	Wait another 4 days

Explanation

C	Refer to thoracic surgeons

The answer is Refer to thoracic surgeons -

This man has a secondary pneumothorax as he has underlying lung disease. The management is different for primary (no underlying pulmonary disease) and secondary (underlying pulmonary disease) pneumothoraces. Current guidelines[1] suggest that an intercostal drain should be inserted if the patient is breathless, over 50 years old with a significant smoking history and there is a rim of air of > 2 cm from the chest wall on a standard size chest X-ray. This patient fits all the above criteria.
Suction should not be applied immediately and it is recommended that it should not be routinely employed. It maybe considered after 48 hours whilst awaiting surgical review if the lung is not fully re-expanded or if there is a persistent air leak. Suction should be low-pressure (-10 to -20 cmH_2O), high-volume.
Because this patient has a persistent air leak at 4 days, despite suction, they should be referred to the thoracic surgeons. The exact timing of referral remains contentious but it is suggested that in cases of persistent air leak or failure of the lung to re-expand, an early (3-5 days) thoracic surgical opinion should be sought.
For secondary pneumothoraces, an early thoracic surgical referral is recommended.

A	Insert another chest drain

Insert another chest drain is incorrect. The placement of a further intercostal drain is not recommended in a patient with a persistent air leak. A surgical review is warranted here.

B	Increase suction pressure to -30 cm H_2O

Increase suction pressure to -30 cm H_2O is incorrect. Suction pressure should not be increased over -20cm H_2O.

D	Arrange a CT scan of the chest

Arrange a CT scan of the chest is incorrect. A CT scan may be helpful to look for bullae which may have triggered the pneumothorax and is usually required prior to surgical intervention. Apical bullectomies are often performed at the time of surgical pleurectomy to help minimise risk of recurrence. However the most appropriate next step in this case prior to CT is referring to the surgical team.

E	Wait another 4 days

Wait another 4 days is incorrect. Guidelines suggest involvement of thoracic surgeons should be earlier.

70122

Rate this question:

Next Question

Previous Question | Tag Question

Feedback | End Session

Difficulty: Average

Peer Responses %

Session Progress

Responses Correct:	0
Responses Incorrect:	236
Responses Total:	236
Responses - % Correct:	0%

External Links

BTS Pleural Disease Guideline 2010
brit-thoracic.org.uk/document-library/clinical-information/pleural-disease/pleural-dis...

© Pastest 2017

A 31-year-old asthmatic woman was seen in the Respiratory Outpatient Clinic. She said she had been generally well although she had not been sleeping well at night due to coughing. She had also noticed that when playing tennis she was getting wheezy and requiring her salbutamol inhaler more frequently – at least 4 times a week. She was taking budesonide 200 micrograms two puffs twice a day. She had no significant past medical history. She smoked 10 cigarettes/day and had done so for 2 years.

Auscultation of her chest revealed a mild expiratory wheeze. Examination was otherwise remarkable.

PEF	80% predicted
FEV_1	85% predicted
FVC	90% predicted

How would you treat this patient?

A	Increase Budesonide
B	Add an inhaled long-acting beta-2-agonist
C	Give a course of oral Prednisolone
D	Add Aminophylline
E	Start a regular Salbutamol inhaler

70123

Submit

Previous Question Skip Question

Calculator

Normal Values

Blog About Pastest Contact Us Help

© Pastest 2017

A 31-year-old asthmatic woman was seen in the Respiratory Outpatient Clinic. She said she had been generally well although she had not been sleeping well at night due to coughing. She had also noticed that when playing tennis she was getting wheezy and requiring her salbutamol inhaler more frequently – at least 4 times a week. She was taking budesonide 200 micrograms two puffs twice a day. She had no significant past medical history. She smoked 10 cigarettes/day and had done so for 2 years.

Auscultation of her chest revealed a mild expiratory wheeze. Examination was otherwise remarkable.

PEF	80% predicted
FEV_1	85% predicted
FVC	90% predicted

How would you treat this patient?

A	Increase Budesonide
B	Add an inhaled long-acting beta-2-agonist
C	Give a course of oral Prednisolone
D	Add Aminophylline
E	Start a regular Salbutamol inhaler

Explanation

B Add an inhaled long-acting beta-2-agonist

This woman is on step 2 of the asthma treatment ladder – she is on a low/moderate dose inhaled steroids (800 mg/day). A trial of an alternative agent should be added prior to increasing inhaled steroids. The first choice of additional therapy would be a long-acting β2-agonist as this improves lung function and symptoms and decreases exacerbations. If this did not improve her symptoms, she should stop the long-acting β2-agonist and try a leukotriene receptor antagonist or Theophylline.

https://www.brit-thoracic.org.uk/document-library/clinical-information/asthma/btssign-asthma-guideline-quick-reference-guide-2014/
'The BTS/SIGN British Guideline on the Management of Asthma', 2003. Thorax: 58 (Suppl. 1)

A Increase Budesonide

She is already on a moderate dose of inhaled corticosteroid. The next most appropriate step is to add in a long acting bronchodilator. If this were to have no effect then the dose of inhaled corticosteroid should be increased.

C Give a course of oral Prednisolone

This is not an acute asthma exacerbation requiring oral steroid therapy, this lady has poor asthma control and needs her maintenancetreatment increased.

D Add Aminophylline

Aminophylline is reserved for patients who have not responded to high dose inhaled corticosteroids in combination with a long acting inhaled beta 2 agonist.

E Start a regular Salbutamol inhaler

Salbutamol is a short acting beta 2 agonist and would need to be taken multiple times per day to relieve symptoms. It is more appropriate to give a long acting beta 2 agonist. Short acting beta 2 agonists like Salbutamol are reserved for acute relief of symptoms rather than prevention.

70123

Rate this question:

Next Question

Previous Question | Tag Question

Feedback | End Session

Difficulty: Average

Peer Responses %

Session Progress

Responses Correct:	0
Responses Incorrect:	237
Responses Total:	237
Responses - % Correct:	0%

© Pastest 2017

A 31-year-old asthmatic woman was seen in the Respiratory Outpatient Clinic. She said she had been generally well although she had not been sleeping well at night due to coughing. She had also noticed that when playing tennis she was getting wheezy and requiring her salbutamol inhaler more frequently – at least 4 times a week. She was taking budesonide 200 micrograms two puffs twice a day. She had no significant past medical history. She smoked 10 cigarettes/day and had done so for 2 years. Auscultation of her chest revealed a mild expiratory wheeze. Examination was otherwise remarkable.

Auscultation of her chest revealed a mild expiratory wheeze. Examination was otherwise remarkable.

Investigations:

PEF	80% predicted
FEV1	85% predicted
FVC	90% predicted

She is treated successfully and goes home.

Her symptoms improve and she goes back to playing regular tennis without a problem. Three months later she was feeling so much better she decided not to renew her prescription for her inhalers.

Two weeks following this she developed a chest infection and became acutely short of breath. On examination she is unable to speak full sentences. Respiratory rate is 30/min, pulse 115/min, BP 100/60 mmHg.

Auscultation of her chest reveals an expiratory wheeze throughout.

PEFR	50 l/min
ABGs on air:	
pH	7.47
pCO_2	4.06 kPa
pO_2	12 kPa
Bicarbonate	21.5 mmol/l

Which of the following would be the best initial management for this patient?

A	High-flow oxygen, oral/intravenous steroid, salbutamol and ipratropium bromide nebulisers
B	60% oxygen, oral/intravenous steroid, salbutamol and ipratropium bromide nebulisers and leukotriene receptor antagonist
C	60% oxygen, oral/intravenous steroid, salbutamol and ipratropium bromide nebulisers and intravenous magnesium
D	High-flow oxygen, salbutamol and ipratropium bromide nebulisers and intravenous magnesium
E	High-flow oxygen, intravenous/oral steroids, ipratropium bromide nebuliser and intravenous aminophylline

70124

Submit

Previous Question | Skip Question

Calculator

Normal Values

© Pastest 2017

A 31-year-old asthmatic woman was seen in the Respiratory Outpatient Clinic. She said she had been generally well although she had not been sleeping well at night due to coughing. She had also noticed that when playing tennis she was getting wheezy and requiring her salbutamol inhaler more frequently – at least 4 times a week. She was taking budesonide 200 micrograms two puffs twice a day. She had no significant past medical history. She smoked 10 cigarettes/day and had done so for 2 years. Auscultation of her chest revealed a mild expiratory wheeze. Examination was otherwise remarkable.

Auscultation of her chest revealed a mild expiratory wheeze. Examination was otherwise remarkable.

Investigations:

PEF	80% predicted
FEV1	85% predicted
FVC	90% predicted

She is treated successfully and goes home.

Her symptoms improve and she goes back to playing regular tennis without a problem. Three months later she was feeling so much better she decided not to renew her prescription for her inhalers.

Two weeks following this she developed a chest infection and became acutely short of breath. On examination she is unable to speak full sentences. Respiratory rate is 30/min, pulse 115/min, BP 100/60 mmHg.

Auscultation of her chest reveals an expiratory wheeze throughout.

PEFR	50 l/min
ABGs on air:	
pH	7.47
pCO_2	4.06 kPa
pO_2	12 kPa
Bicarbonate	21.5 mmol/l

Which of the following would be the best initial management for this patient?

A. High-flow oxygen, oral/intravenous steroid, salbutamol and ipratropium bromide nebulisers

B. 60% oxygen, oral/intravenous steroid, salbutamol and ipratropium bromide nebulisers and leukotriene receptor antagonist

C. 60% oxygen, oral/intravenous steroid, salbutamol and ipratropium bromide nebulisers and intravenous magnesium

D. High-flow oxygen, salbutamol and ipratropium bromide nebulisers and intravenous magnesium

E. High-flow oxygen, intravenous/oral steroids, ipratropium bromide nebuliser and intravenous aminophylline

Explanation

A. High-flow oxygen, oral/intravenous steroid, salbutamol and ipratropium bromide nebulisers

After stopping her inhalers she is no longer on any medication to control her asthma. She presents to the Emergency Department with symptoms and signs of a severe asthma exacerbation – inability to complete a sentence in one breath, respiratory rate >25/min, tachycardia >110 bpm and PEFR <50%. The correct management is high-flow oxygen as patients with pure asthma do not retain carbon dioxide; salbutamol and ipratropium bromide nebulisers driven by oxygen; steroid therapy – prednisolone 40 mg orally if the patient is able to take oral medication, or 100 mg intravenous hydrocortisone. Intravenous magnesium should be given in life-threatening asthma or if there is no response to initial therapy. Intravenous aminophylline can also be used.

B. 60% oxygen, oral/intravenous steroid, salbutamol and ipratropium bromide nebulisers and leukotriene receptor antagonist

Leukotriene receptor antagonists are used in the management of asthma, but are not appropriate as an acute treatment for an exacerbation.

C. 60% oxygen, oral/intravenous steroid, salbutamol and ipratropium bromide nebulisers and intravenous magnesium

Intravenous magnesium is reserved for patients with a PEFR <50% predicted and who have not had a good response to inhaled bronchodilator therapies.

D. High-flow oxygen, salbutamol and ipratropium bromide nebulisers and intravenous magnesium

Intravenous magnesium is reserved for patients with a PEFR <50% predicted and who have not had a good response to inhaled bronchodilator therapies.

E. High-flow oxygen, intravenous/oral steroids, ipratropium bromide nebuliser and intravenous aminophylline

Salbutamol nebulisers are needed.

70124

Rate this question:

Next Question

Previous Question | Tag Question

Feedback | End Session

Difficulty: Average

Peer Responses %

Session Progress

Responses Correct:	0
Responses Incorrect:	238
Responses Total:	238
Responses - % Correct:	0%

External Links

British guideline on the management of asthma
brit-thoracic.org.uk/document-library/clinical-information/asthma/btssign-asthma-g...

© Pastest 2017

A 31-year-old asthmatic woman was seen in the Respiratory Outpatient Clinic. She said she had been generally well although she had not been sleeping well at night due to coughing. She had also noticed that when playing tennis she was getting wheezy and requiring her salbutamol inhaler more frequently – at least 4 times a week. She was taking budesonide 200 micrograms two puffs twice a day. She had no significant past medical history. She smoked 10 cigarettes/day and had done so for 2 years. Auscultation of her chest revealed a mild expiratory wheeze. Examination was otherwise remarkable.

PEF	80% predicted
FEV_1	85% predicted
FVC	90% predicted

She is treated successfully and goes home.

Her symptoms improve and she goes back to playing regular tennis without a problem. Three months later she was feeling so much better she decided not to renew her prescription for her inhalers.

Two weeks following this she developed a chest infection and became acutely short of breath. On examination she is unable to speak full sentences. Respiratory rate is 30/min, pulse 115/min, BP 100/60 mmHg.

Auscultation of her chest reveals an expiratory wheeze throughout.

PEFR	50 l/min
ABGs on air:	
pH	7.45
pCO_2	4.06 kPa
pO_2	12 kPa
Bicarbonate	21.5 mmol/l

She does not improve with treatment. Her chest examination now reveals quiet breath sounds. Repeat arterial blood gases on oxygen show:

pH	7.33
pCO_2	6.5 kPa
pO_2	12 kPa
Bicarbonate	25.1 kPa

What would you do next?

A	Give intravenous antibiotics
B	Give more regular nebulisers
C	Refer to ICU for intubation
D	Start non-invasive ventilation
E	Trial of helium/oxygen

70125

Submit

Previous Question | Skip Question

Calculator

Normal Values

© Pastest 2017

A 31-year-old asthmatic woman was seen in the Respiratory Outpatient Clinic. She said she had been generally well although she had not been sleeping well at night due to coughing. She had also noticed that when playing tennis she was getting wheezy and requiring her salbutamol inhaler more frequently – at least 4 times a week. She was taking budesonide 200 micrograms two puffs twice a day. She had no significant past medical history. She smoked 10 cigarettes/day and had done so for 2 years. Auscultation of her chest revealed a mild expiratory wheeze. Examination was otherwise remarkable.

PEF	80% predicted
FEV_1	85% predicted
FVC	90% predicted

She is treated successfully and goes home.

Her symptoms improve and she goes back to playing regular tennis without a problem. Three months later she was feeling so much better she decided not to renew her prescription for her inhalers.

Two weeks following this she developed a chest infection and became acutely short of breath. On examination she is unable to speak full sentences. Respiratory rate is 30/min, pulse 115/min, BP 100/60 mmHg.

Auscultation of her chest reveals an expiratory wheeze throughout.

PEFR	50 l/min
ABGs on air:	
pH	7.45
pCO_2	4.06 kPa
pO_2	12 kPa
Bicarbonate	21.5 mmol/l

She does not improve with treatment. Her chest examination now reveals quiet breath sounds. Repeat arterial blood gases on oxygen show:

pH	7.33
pCO_2	6.5 kPa
pO_2	12 kPa
Bicarbonate	25.1 kPa

What would you do next?

A	Give intravenous antibiotics
B	Give more regular nebulisers
C	Refer to ICU for intubation
D	Start non-invasive ventilation
E	Trial of helium/oxygen

Explanation

C Refer to ICU for intubation

The patient deteriorates and develops signs of life-threatening asthma – a silent chest, a pCO_2 >6kPa and a fall in pH. Other signs of life-threatening asthma include: confusion, exhaustion or coma, bradycardia, hypotension, PEFR <30% predicted or best, and severe hypoxaemia (PaO_2 <8 kPa) despite oxygen therapy. This patient now needs intubation and transfer to the ICU. Non-invasive ventilation is not used in asthma at present and it is unlikely ever to replace intubation in life-threatening asthma.

A Give intravenous antibiotics

The priority here is to ensure the patient is receiving adequate respiratory support. This lady's exacerbation is likely to have been triggered by a virus in conjunction with non-adherence to her asthma medication.

B Give more regular nebulisers

This lady is now in acute type 2 respiratory failure with respiratory acidosis. This is near-fatal asthma and she requires immediate intensive care assessment for intubation and ventilation.

D Start non-invasive ventilation

Non-invasive ventilation is not an appropriate treatment for asthma. Invasive ventilation should be used in patients with acute respiratory failure secondary to as asthma exacerbation.

E Trial of helium/oxygen

Helium/oxygen is a treatment for vocal cord dysfunction – this lady is having a near-fatal asthma exacerbation

70125

Rate this question:

Next Question

Previous Question | Tag Question

Feedback | End Session

Difficulty: Average

Peer Responses %

Session Progress

Responses Correct:	0
Responses Incorrect:	239
Responses Total:	239
Responses - % Correct:	0%

External Links

British guideline on the management of asthma
brit-thoracic.org.uk/document-library/clinical-information/asthma/btssign-asthma-g...

© Pastest 2017

A 77-year-old lady was referred to the Respiratory Outpatient Clinic with increasing shortness of breath. Her CXR is shown below.

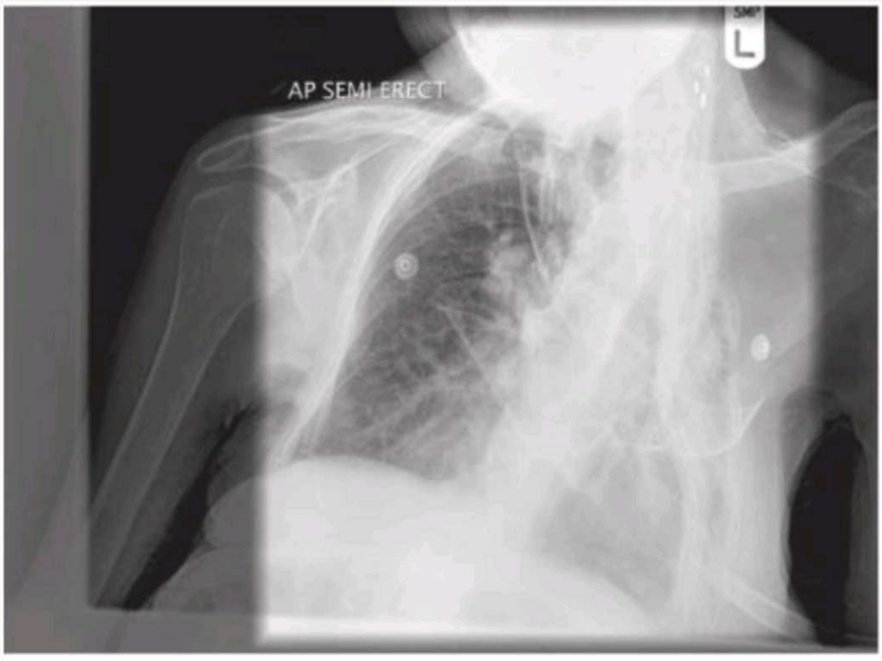

What operation has she had?

A	Left upper lobectomy
B	Left pneumonectomy
C	Thoracoplasty
D	Phrenic crush
E	Plombage

70126

Submit

Previous Question | Skip Question

Calculator

Normal Values

© Pastest 2017

A 77-year-old lady was referred to the Respiratory Outpatient Clinic with increasing shortness of breath. Her CXR is shown below.

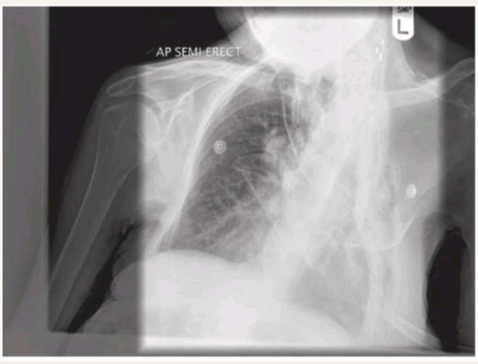

What operation has she had?

A	Left upper lobectomy
B	Left pneumonectomy
C	Thoracoplasty
D	Phrenic crush
E	Plombage

Explanation

C Thoracoplasty

This question is a 'spot diagnosis'. Clues that this is a thoracoplasty and not any of the alternative options are that there is evidence of rib resection in conjunction with loss of lung volume. The CXR shows a thoracoplasty. This lady had tuberculosis in the 1940s, prior to the use of anti-tuberculosis chemotherapy. She had a thoracoplasty, which was one of the main surgical treatments for tuberculosis between 1930 and 1955. Several ribs were resected, which reduced the thoracic volume and collapsed the underlying lung. The aim was to close the tuberculous cavity and 'rest the lung'. Control of pulmonary tuberculosis and survival was good. However, patients were left with severe chest deformity and the associated respiratory compromise, a restrictive defect.

A Left upper lobectomy

Upper lobectomy would only be associated with loss of upper lung volume.

B Left pneumonectomy

This would not be associated with the bony changes seen here.

D Phrenic crush

Phrenic crush is associated with elevated hemidiaphragm rather than the extensive bony resection seen here.

E Plombage

The CXR would show material inserted into the chest cavity to promote lung collapse.

70126

Rate this question:

Next Question

Previous Question | Tag Question

Feedback | End Session

Difficulty: Average

Peer Responses %

Session Progress

Responses Correct:	0
Responses Incorrect:	240
Responses Total:	240
Responses - % Correct:	0%

© Pastest 2017

A 77-year-old lady was referred to the Respiratory Outpatient Clinic with increasing shortness of breath. Her CXR is shown below.

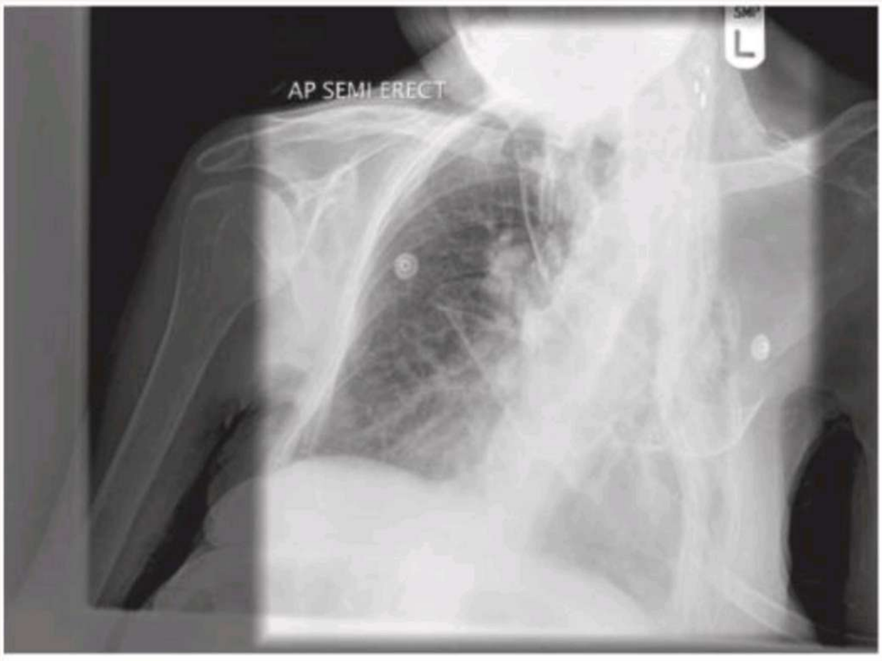

What was her underlying diagnosis?

A	Small-cell lung cancer
B	Squamous-cell lung cancer
C	Adenocarcinoma
D	Tuberculosis
E	Squamous cell lung cancer

70127

Submit

Previous Question | Skip Question

Calculator

Normal Values

© Pastest 2017

A 77-year-old lady was referred to the Respiratory Outpatient Clinic with increasing shortness of breath. Her CXR is shown below.

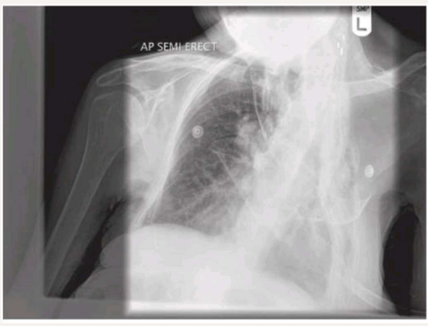

What was her underlying diagnosis?

A	Small-cell lung cancer
B	Squamous-cell lung cancer
C	Adenocarcinoma
D	Tuberculosis
E	Squamous cell lung cancer

Explanation

D Tuberculosis

This question is a 'spot diagnosis'. Clues that this is a thoracoplasty are that there is evidence of rib resection in conjunction with loss of lung volume. The CXR shows a thoracoplasty. This lady had tuberculosis in the 1940s, prior to the use of anti-tuberculosis chemotherapy. She had a thoracoplasty, which was one of the main surgical treatments for tuberculosis between 1930 and 1955. Several ribs were resected, which reduced the thoracic volume and collapsed the underlying lung. The aim was to close the tuberculous cavity and 'rest the lung'. Control of pulmonary tuberculosis and survival was good. However, patients were left with severe chest deformity and the associated respiratory compromise, a restrictive defect.

A Small-cell lung cancer

Adenocarcinoma would present as a mass on the chest X-ray. There would not be rib resection and loss of lung volume. Other symptoms and signs may include anaemia and weight loss.

B Squamous-cell lung cancer

Symptoms of pneumothorax would include sudden onset of sharp, unilateral chest pain with shortness of breath. On a chest X-ray there would be an air rim and collapse of lung. However, there would not be rib resection as in this case.

C Adenocarcinoma

As with adenocarcinoma, chest X-ray would show a mass rather than loss of lung volume. Small cell lung cancer is a fast-growing type of lung cancer, spreading more quickly than non-small cell lung cancer and therefore it is the most aggressive form of lung cancer. Two types of small cell lung cancer exists – oat cell carcinoma and combined small cell carcinoma. Small cell lung cancer is more common in men than women. Almost all cases of small cell lung cancer are due to cigarette smoking. It is very rare in people who have never smoked.

E Squamous cell lung cancer

As with adenocarcinoma and small cell lung cancer, chest X-ray would show a mass rather than loss of lung volume. Squamous cell lung cancer, otherwise known as epidermoid carcinoma, is a type of non-small cell lung cancer. The prognosis for squamous cell carcinoma is poorer than that for adenocarcinoma. It accounts for about 30% of all lung cancers.

70127

Rate this question:

Next Question

Previous Question | Tag Question

Feedback | End Session

Difficulty: Average

Peer Responses %

Session Progress

Responses Correct:	0
Responses Incorrect:	241
Responses Total:	241
Responses - % Correct:	0%

© Pastest 2017

A 69-year-old gentleman was taken to the Emergency Department with a reduced GCS score; no history was available from A&E for the patient in A&E. The ambulance crew said that the call was put out by his wife as he had become increasingly short of breath. When they arrived he looked breathless and cyanosed. He denied any chest pain at that time.

On examination he had a GCS score of 10 (M5, V2, E3), respiratory rate 10/min, BP 130/70 mmHg, pulse 120/min, temperature 36.9°C, SaO_2 94% on 15 l oxygen. Auscultation of the chest revealed an expiratory wheeze throughout.

Heart sounds were normal and abdominal examination unremarkable. There was no obvious focal neurological abnormality and both plantars showed a flexor response.

Investigations:

Hb	17.3 g/dl
WCC	8.2 x10^9/l
PLT	400 x10^9/l
MCV	84 fl
CRP	21 mg/l
ECG	Sinus tachycardia
CXR	Hyperinflated lung fields with low, flattened diaphragm; no evidence of a pneumothorax

In his notes you find a flow-volume curve from 1 year ago shown below.

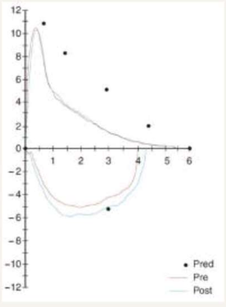

ABGs on high-flow oxygen on this admission:	
pH	7.29
PCO_2	10.91 kPa
PO_2	12.39 kPa
Bicarbonate	40.6 mmol/l
Base excess	10.4

What does the arterial blood gas analysis show?

A	Mixed respiratory and metabolic acidosis
B	Acute respiratory acidosis
C	Metabolic acidosis
D	Acute on chronic respiratory acidosis
E	Metabolic alkalosis

70128

Submit

Previous Question | Skip Question

Calculator

Normal Values

© Pastest 2017

A 69-year-old gentleman was taken to the Emergency Department with a reduced GCS score; no history was available from A&E for the patient in A&E. The ambulance crew said that the call was put out by his wife as he had become increasingly short of breath. When they arrived he looked breathless and cyanosed. He denied any chest pain at that time.

On examination he had a GCS score of 10 (M5, V2, E3), respiratory rate 10/min, BP 130/70 mmHg, pulse 120/min, temperature 36.9°C, SaO_2 94% on 15 l oxygen. Auscultation of the chest revealed an expiratory wheeze throughout.

Heart sounds were normal and abdominal examination unremarkable. There was no obvious focal neurological abnormality and both plantars showed a flexor response.

Investigations:

Hb	17.3 g/dl
WCC	8.2 $x10^9$/l
PLT	400 $x10^9$/l
MCV	84 fl
CRP	21 mg/l
ECG	Sinus tachycardia
CXR	Hyperinflated lung fields with low, flattened diaphragm; no evidence of a pneumothorax

In his notes you find a flow-volume curve from 1 year ago shown below.

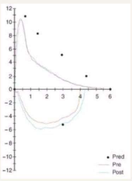

ABGs on high-flow oxygen on this admission:	
pH	7.29
PCO_2	10.91 kPa
PO_2	12.39 kPa
Bicarbonate	40.6 mmol/l
Base excess	10.4

What does the arterial blood gas analysis show?

A	Mixed respiratory and metabolic acidosis
B	Acute respiratory acidosis
C	Metabolic acidosis
D	Acute on chronic respiratory acidosis
E	Metabolic alkalosis

Explanation

D	Acute on chronic respiratory acidosis

This patient has an acute on chronic respiratory acidosis. The high bicarbonate and base excess show that there is an underlying chronic respiratory acidosis with renal compensation. The acidosis and high CO_2 indicate an acute respiratory acidosis. If this was acute without a chronic element then, for a PCO_2 of 10.91 one would expect the pH to be lower.

The diagnosis of COPD is suggested from the CXR and flow-volume curve, which shows the classic shape for COPD. In some patients with COPD, respiratory drive depends on their degree of hypoxia, rather than the usual dependence on hypercapnia. Although it is important to prevent life-threatening hypoxia, uncontrolled oxygen therapy should be used with caution. This patient has a suppressed respiratory drive and carbon dioxide narcosis secondary to high-flow oxygen. He was able to tell the ambulance crew that he had no chest pain at home; he was then given high-flow oxygen and his GCS dropped. Note on arrival at the Emergency Department that he scored 2/5 for verbal response and therefore would not be able to give any information. The immediate management is therefore to reduce the inspired oxygen concentration and repeat the arterial blood gases. If by doing this the patient becomes hypoxic or remains acidotic, they should then be referred for non-invasive ventilation.

A	Mixed respiratory and metabolic acidosis

The ABG would be expected to show low bicarbonate and base excess if a metabolic component to the acidosis were present.

B	Acute respiratory acidosis

In acute respiratory acidosis, one would expect the bicarbonate and base excess to be lower. The raised bicarbonate implies a chronicity to the respiratory acidosis with renal compensation.

C	Metabolic acidosis

The raised CO_2 implies a respiratory component to the acidosis. In a metabolic acidosis, the bicarbonate and base excess would be expected to be low.

E	Metabolic alkalosis

The ABG demonstrates a low pH and raised CO_2, neither of which is in keeping with metabolic alkalosis. The bicarbonate and base excess are raised, likely representing renal compensation to a chronic respiratory acidosis.

70129

Rate this question:

Next Question

Previous Question | Tag Question

Feedback | End Session

Difficulty: Average

Peer Responses %

Session Progress

Responses Correct:	0
Responses Incorrect:	242
Responses Total:	242
Responses - % Correct:	0%

Blog About Pastest Contact Us Help

© Pastest 2017

A 69-year-old gentleman was taken to the Emergency Department with a reduced GCS score; no history was available from A&E for the patient in A&E. The ambulance crew said that the call was put out by his wife as he had become increasingly short of breath. When they arrived he looked breathless and cyanosed. He denied any chest pain at that time.

On examination he had a GCS score of 10 (M5, V2, E3), respiratory rate 10/min, BP 130/70 mmHg, pulse 120/min, temperature 36.9°C, SaO_2 94% on 15 l oxygen. Auscultation of the chest revealed an expiratory wheeze throughout.

Heart sounds were normal and abdominal examination unremarkable. There was no obvious focal neurological abnormality and both plantars showed a flexor response.

Investigations:

Hb	17.3 g/dl
WCC	8.2 $x10^9$/l
PLT	400 $x10^9$/l
MCV	84 fl
CRP	21 mg/l
ECG	Sinus tachycardia
CXR	Hyperinflated lung fields with low, flattened diaphragm; no evidence of a pneumothorax
Renal function & liver tests	Unremarkable

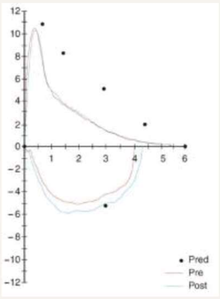

ABGs on high-flow oxygen on this admission:	
pH	7.29
PCO_2	10.91 kPa
PO_2	12.39 kPa
Bicarbonate	40.6 mmol/l
Base excess	10.4

What is the most appropriate next step in the management of this patient?

A	Intubation and invasive ventilation
B	Start non-invasive ventilation
C	Hydrocortisone 100 mg IV
D	Salbutamol 2.5 mg via nebuliser
E	Reduce inspired oxygen concentration to 28% and repeat ABG

70129

Submit

Previous Question | Skip Question

Calculator

Normal Values

© Pastest 2017

A 69-year-old gentleman was taken to the Emergency Department with a reduced GCS score; no history was available from A&E for the patient in A&E. The ambulance crew said that the call was put out by his wife as he had become increasingly short of breath. When they arrived he looked breathless and cyanosed. He denied any chest pain at that time.

On examination he had a GCS score of 10 (M5, V2, E3), respiratory rate 10/min, BP 130/70 mmHg, pulse 120/min, temperature 36.9°C, SaO_2 94% on 15 l oxygen. Auscultation of the chest revealed an expiratory wheeze throughout.

Heart sounds were normal and abdominal examination unremarkable. There was no obvious focal neurological abnormality and both plantars showed a flexor response.

Investigations:

Hb	17.3 g/dl
WCC	8.2 $x10^9$/l
PLT	400 $x10^9$/l
MCV	84 fl
CRP	21 mg/l
ECG	Sinus tachycardia
CXR	Hyperinflated lung fields with low, flattened diaphragm; no evidence of a pneumothorax
Renal function & liver tests	Unremarkable

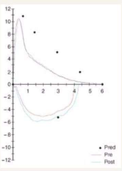

ABGs on high-flow oxygen on this admission:	
pH	7.29
PCO_2	10.91 kPa
PO_2	12.39 kPa
Bicarbonate	40.6 mmol/l
Base excess	10.4

What is the most appropriate next step in the management of this patient?

A	Intubation and invasive ventilation
B	Start non-invasive ventilation
C	Hydrocortisone 100 mg IV
D	Salbutamol 2.5 mg via nebuliser
E	Reduce inspired oxygen concentration to 28% and repeat ABG

Explanation

E	Reduce inspired oxygen concentration to 28% and repeat ABG

This patient has an acute on chronic respiratory acidosis. The high bicarbonate and base excess shows that there is an underlying chronic respiratory acidosis with renal compensation. The acidosis and high CO_2 indicate an acute respiratory acidosis. If this was acute without a chronic element then, for a PCO_2 of 10.91 one would expect the pH to be lower.

This question is about oxygen therapy in COPD. The diagnosis of COPD is suggested from the CXR and flow-volume curve, which shows the classic shape for COPD. In some patients with COPD, CO2 retention is more prevalent. Two reasons are now thought to underlie this, 1) there is greater v/q mismatch in COPD, and secondly, the Haldane effect, a shift in the CO2 dissociation curve occurs.

Note on arrival at the Emergency Department he scored 2/5 for verbal response and therefore would not be able to give any information. The immediate management is therefore to reduce the inspired oxygen concentration and repeat the arterial blood gases. If by doing this the patient becomes hypoxic or remains acidotic, they should then be referred for non-invasive ventilation.

National Collaborating Centre for Chronic Conditions. 2004. Chronic obstructive pulmonary disease. National clinical guideline on management of chronic obstructive pulmonary disease in adults in primary and secondary care.Thorax, 59 (suppl 1), 1-232

http://www.ncbi.nlm.nih.gov/pubmed/15041752

A	Intubation and invasive ventilation

An anaesthetic opinion would be warranted for consideration of intubation if he did not respond to controlled oxygen ± a trial of NIV, but it does not represent the optimal next step for this patient.

B	Start non-invasive ventilation

Non-invasive ventilation (NIV) would be appropriate if controlled oxygen therapy and medical therapies did not result in clinical improvement including resolution of acidosis, but does not represent the optimal next step for this patient.

C	Hydrocortisone 100 mg IV

While NICE recommend corticosteroids (prednisolone orally for a maximum of 7-14 days) for patients without contraindications who present to hospital with an exacerbation of COPD, in this case the patient has become obtunded due to excessive oxygen therapy. Corticosteroids may play a role in his medical management, but the optimal next step is to provide controlled oxygen therapy.

D	Salbutamol 2.5 mg via nebuliser

Salbutamol (and/or ipratropium) via nebuliser is recommended therapy in the treatment of COPD exacerbation, but the most pressing concern in this patient's case is his reduced GCS secondary to excessive oxygen therapy. The most appropriate next step is to provide controlled oxygen therapy and repeat an ABG.

70129

Rate this question:

Next Question

Previous Question | Tag Question

Feedback | End Session

Difficulty: Average

Peer Responses %

Session Progress

Responses Correct:	0
Responses Incorrect:	243
Responses Total:	243
Responses - % Correct:	0%

© Pastest 2017

A 72-year-old gentleman is referred to the Respiratory Outpatients Clinic with a 2-month history of increasing shortness of breath and cough. Over the last few weeks he has coughed up a few streaks of blood. He has also noticed difficulty getting up from a chair, and that his clothes have been looser recently despite his not trying to lose weight.

On examination he is clubbed. Auscultation of his chest reveals reduced expansion and breath sounds on the left. Heart sounds are normal. He has a 2 cm hepatomegaly on palpation of his abdomen. He has reduced power (4/5) on hip flexion bilaterally and generally reduced tendon reflexes. Plantars both show a flexor response; proprioception and sensation are normal.

Investigations:

Hb	10.9 g/dl
WCC	12.2 x10^9/l
PLT	491 x10^9/l
MCV	79 fl
ESR	58 mm/1st hour
Na^+	126 mmol/l
K^+	3.6 mmol/l
Urea	5.9 mmol/l
Creatinine	125 micromol/l
Bilirubin	49 micromol/l
AST	120 U/l
ALP	441 U/l
Albumin	32 g/l
Corrected Calcium	2.74 mmol/l
Phosphate	0.81 mmol/l

His CXR is shown below:

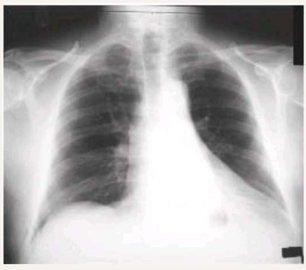

What does the CXR show?

A	Left lower lobe consolidation
B	Left lower lobe collapse
C	Lingular consolidation
D	Left upper lobe collapse
E	Left apical pneumothorax

70131

Submit

Previous Question | Skip Question

Calculator

Normal Values

© Pastest 2017

A 72-year-old gentleman is referred to the Respiratory Outpatients Clinic with a 2-month history of increasing shortness of breath and cough. Over the last few weeks he has coughed up a few streaks of blood. He has also noticed difficulty getting up from a chair, and that his clothes have been looser recently despite his not trying to lose weight.

On examination he is clubbed. Auscultation of his chest reveals reduced expansion and breath sounds on the left. Heart sounds are normal. He has a 2 cm hepatomegaly on palpation of his abdomen. He has reduced power (4/5) on hip flexion bilaterally and generally reduced tendon reflexes. Plantars both show a flexor response; proprioception and sensation are normal.

Investigations:

Hb	10.9 g/dl
WCC	12.2 $x10^9$/l
PLT	491 $x10^9$/l
MCV	79 fl
ESR	58 mm/1st hour
Na^+	126 mmol/l
K^+	3.6 mmol/l
Urea	5.9 mmol/l
Creatinine	125 micromol/l
Bilirubin	49 micromol/l
AST	120 U/l
ALP	441 U/l
Albumin	32 g/l
Corrected Calcium	2.74 mmol/l
Phosphate	0.81 mmol/l

His CXR is shown below:

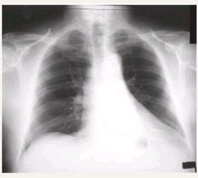

What does the CXR show?

A	Left lower lobe consolidation
B	Left lower lobe collapse
C	Lingular consolidation
D	Left upper lobe collapse
E	Left apical pneumothorax

Explanation

B	Left lower lobe collapse

The chest X-ray shows left lower lobe collapse. There is loss of volume of the left hemi-thorax, the classical 'sail sign' (double left heart border) behind the heart, and loss of the normal outline of the left hemi-diaphragm.

A	Left lower lobe consolidation

The opacification seen in the left lower zone has a smooth border and is more in keeping with the 'sail sign' of left lower lobe collapse. Consolidation would have a more heterogeneous appearance and air bronchograms may be visible.

C	Lingular consolidation

The left cardiac border can be visualised, making lingular consolidation unlikely. In lingular consolidation, loss of the left heart silhouette would be expected.

D	Left upper lobe collapse

Left upper lobe collapse presents as veil-like shadowing over the remaining inflated lung.

E	Left apical pneumothorax

Lung markings are visible throughout all lung fields and no lung edge is seen.

701.31

Rate this question:

Next Question

Previous Question | Tag Question

Feedback | End Session

Difficulty: Average

Peer Responses %

Session Progress

Responses Correct:	0
Responses Incorrect:	244
Responses Total:	244
Responses - % Correct:	0%

© Pastest 2017

A 72-year-old gentleman is referred to the Respiratory Outpatients Clinic with a 2-month history of increasing shortness of breath and cough. Over the last few weeks he has coughed up a few streaks of blood. He has also noticed difficulty getting up from a chair, and that his clothes have been looser recently without trying to lose weight. He is taking regular inhaler therapy but is unsure of their names.

On examination he is clubbed. Auscultation of his chest reveals reduced expansion and breath sounds on the left. Heart sounds are normal. He has a 2 cm hepatomegaly on palpation of his abdomen. He has reduced power (4/5) on hip flexion bilaterally and generally reduced tendon reflexes. Plantars both show a flexor response; proprioception and sensation are normal.

Investigations:

Hb	10.9 g/dl
WCC	12.2 x10^9/l
PLT	491 x10^9/l
MCV	79 fl
ESR	58 mm/1st hour
Na^+	126 mmol/l
K^+	3.6 mmol/l
Urea	5.9 mmol/l
Creatinine	125 micromol/l
Bilirubin	49 micromol/l
AST	120 U/l
ALP	441 U/l
Albumin	32 g/l
Corrected Calcium	2.74 mmol/l
Phosphate	0.81 mmol/l

His CXR is shown below:

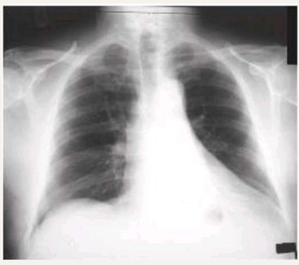

Which investigations would you organise next to aid diagnosis and treatment?

A	Bone scan and bronchoscopy
B	CT brain and liver ultrasound
C	Bronchoscopy and PTH level
D	MRI chest and bone scan
E	CT chest/upper abdomen and bronchoscopy

70132

Submit

Previous Question | Skip Question

Calculator

Normal Values

© Pastest 2017

A 72-year-old gentleman is referred to the Respiratory Outpatients Clinic with a 2-month history of increasing shortness of breath and cough. Over the last few weeks he has coughed up a few streaks of blood. He has also noticed difficulty getting up from a chair, and that his clothes have been looser recently without trying to lose weight. He is taking regular inhaler therapy but is unsure of their names.

On examination he is clubbed. Auscultation of his chest reveals reduced expansion and breath sounds on the left. Heart sounds are normal. He has a 2 cm hepatomegaly on palpation of his abdomen. He has reduced power (4/5) on hip flexion bilaterally and generally reduced tendon reflexes. Plantars both show a flexor response; proprioception and sensation are normal.

Investigations:

Hb	10.9 g/dl
WCC	12.2 x10^9/l
PLT	491 x10^9/l
MCV	79 fl
ESR	58 mm/1st hour
Na^+	126 mmol/l
K^+	3.6 mmol/l
Urea	5.9 mmol/l
Creatinine	125 micromol/l
Bilirubin	49 micromol/l
AST	120 U/l
ALP	441 U/l
Albumin	32 g/l
Corrected Calcium	2.74 mmol/l
Phosphate	0.81 mmol/l

His CXR is shown below:



Which investigations would you organise next to aid diagnosis and treatment?

A	Bone scan and bronchoscopy
B	CT brain and liver ultrasound
C	Bronchoscopy and PTH level
D	MRI chest and bone scan
E	CT chest/upper abdomen and bronchoscopy

Explanation

E	CT chest/upper abdomen and bronchoscopy

The chest X-ray shows left lower lobe collapse. There is loss of volume of the left hemi-thorax and the classical 'sail sign' behind the heart.

In addition to this suggestive CXR, this man also has clinical features of lung malignancy weight loss, haemoptysis, dyspnoea and hypercalcaemia.

His investigations and clinical examination also demonstrate evidence of paraneoplastic syndromes which are associated with certain types of lung cancer:

- hyponatraemia secondary to the syndrome of inappropriate antidiuretic hormone secretion
- the proximal weakness and hyporeflexia which, along with autonomic features, suggests Lambert-Eaton myasthenic syndrome.

These are seen more frequently with small cell lung cancer. Ectopic ACTH production is also associated but rare.

Squamous cell carcinoma is associated with:

- gynaecomastia
- hyperthyroidism
- hypertropic pulmonary osteoarthropathy (HPOA) finger-clubbing, periostitis and arthritis
- hypercalcaemia usually secondary to bone metastases, but rarely may be secondary to secretion of PTH-related peptide.

Common to both:

- hypercalcaemia: the corrected calcium here is 2.74 mmol/ , due to bony metastases. If albumin is <40 g/l, corrected calcium = [Ca^{2+}] + 0.02 × 40-[alb] mmol/l
- clubbing
- smoking: he is likely to be a smoker or ex-smoker and have COPD as he is on inhalers.

A histological diagnosis is important, as is accurate staging. Therefore the most appropriate next investigation would be a bronchoscopy and biopsy, and a staging CT scan. Following this, a bone scan would be useful to confirm bone metastases. Since this patient has deranged liver function tests and hypercalcaemia, it is likely he has metastatic disease. Treatment of small cell lung cancer is primarily palliative with chemotherapy, as metastases tend to occur early. Surgical resection may be considered in combination with chemotherapy if it presented as a solitary pulmonary nodule, but this is rare. Palliative care involvement is important for symptomatic control or if the patient is unsuitable for other treatment options.

A Bone scan and bronchoscopy

While the hypercalcaemia may suggest metastatic disease warranting a bone scan in due course, NICE guidance recommends that 'Patients with known or suspected lung cancer should be offered a contrast-enhanced chest CT scan to further the diagnosis and stage the disease'; the CT scan should be performed first to stage disease, in association with bronchoscopy for histological diagnosis.

B CT brain and liver ultrasound

This would represent an inadequate combination of investigations in this case, and would provide neither histological nor radiological confirmation of the diagnosis. The patient's neurological symptoms are more likely caused by paraneoplastic effects than a cerebral metastasis, and while liver ultrasound may be appropriate to examine for metastases, this alone would not provide adequate staging of the primary tumour.

C Bronchoscopy and PTH level

While bronchoscopy could provide histological diagnosis, PTH would not be a diagnostic test for malignancy. NICE guidance recommends that 'patients with known or suspected lung cancer should be offered a contrast-enhanced chest CT scan to further the diagnosis and stage the disease'.

D MRI chest and bone scan

CT scan, rather than MRI, is the recommended imaging modality for staging of lung cancer. Bronchoscopy is recommended for histological diagnosis.

70132

Rate this question:

Next Question

Previous Question | Tag Question

Feedback | End Session

Difficulty: Average

Peer Responses %

Session Progress

Responses Correct:	0
Responses Incorrect:	245
Responses Total:	245
Responses - % Correct:	0%

Blog About Pastest Contact Us Help

© Pastest 2017

A 72-year-old gentleman is referred to the Respiratory Outpatients Clinic with a 2-month history of increasing shortness of breath and cough. Over the last few weeks he has coughed up a few streaks of blood. He has also noticed difficulty getting up from a chair, and that his clothes are looser recently without trying to lose weight. He is taking regular inhalers, but is unsure of their names.

On examination he is clubbed. Auscultation of his chest reveals reduced expansion and breath sounds on the left. Heart sounds are normal. He has a 2 cm hepatomegaly on palpation of his abdomen. He has reduced power (4/5) on hip flexion bilaterally and generally reduced tendon reflexes. Plantars both show a flexor response; proprioception and sensation are normal.

Investigations:

Hb	10.9 g/dl
WCC	12.2 x10^9/l
PLT	491 x10^9/l
MCV	79 fl
ESR	58 mm/1st hour
Na^+	126 mmol/l
K^+	3.6 mmol/l
Urea	5.9 mmol/l
Creatinine	125 micromol/l
Bilirubin	49 micromol/l
AST	120 U/l
ALP	441 U/l
Albumin	32 g/l
Corrected Calcium	2.68 mmol/l
Phosphate	0.81 mmol/l

His CXR is shown below:

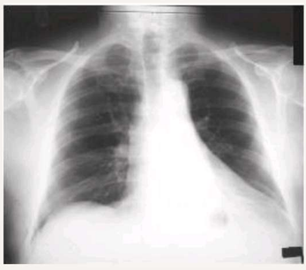

What is the most likely underlying diagnosis?

A	Adenocarcinoma of the lung
B	Squamous carcinoma of the lung
C	Small-cell carcinoma of the lung
D	Mesothelioma
E	Bronchioalveolar carcinoma

70133

Submit

Previous Question | Skip Question

Calculator

Normal Values

© Pastest 2017

A 72-year-old gentleman is referred to the Respiratory Outpatients Clinic with a 2-month history of increasing shortness of breath and cough. Over the last few weeks he has coughed up a few streaks of blood. He has also noticed difficulty getting up from a chair, and that his clothes are looser recently without trying to lose weight. He is taking regular inhalers, but is unsure of their names.

On examination he is clubbed. Auscultation of his chest reveals reduced expansion and breath sounds on the left. Heart sounds are normal. He has a 2 cm hepatomegaly on palpation of his abdomen. He has reduced power (4/5) on hip flexion bilaterally and generally reduced tendon reflexes. Plantars both show a flexor response; proprioception and sensation are normal.

Investigations:

Hb	10.9 g/dl
WCC	12.2 x10^9/l
PLT	491 x10^9/l
MCV	79 fl
ESR	58 mm/1st hour
Na^+	126 mmol/l
K^+	3.6 mmol/l
Urea	5.9 mmol/l
Creatinine	125 micromol/l
Bilirubin	49 micromol/l
AST	120 U/l
ALP	441 U/l
Albumin	32 g/l
Corrected Calcium	2.68 mmol/l
Phosphate	0.81 mmol/l

His CXR is shown below:

What is the most likely underlying diagnosis?

A	Adenocarcinoma of the lung
B	Squamous carcinoma of the lung
C	Small-cell carcinoma of the lung
D	Mesothelioma
E	Bronchioalveolar carcinoma

Explanation

C Small-cell carcinoma of the lung

The chest X-ray shows left lower lobe collapse. There is loss of volume of the left hemi-thorax and the classical 'sail sign' behind the heart.

In addition to this suggestive CXR, this man also has clinical features suggestive of a lung malignancy weight loss, haemoptysis, dyspnoea and hypercalcaemia.

His investigations and clinical examination are suggestive of a paraneoplastic component to this malignancy:

- hyponatraemia secondary to the syndrome of inappropriate antidiuretic hormone secretion
- the proximal weakness and hyporeflexia, which, along with autonomic features, suggest Lambert-Eaton myasthenic syndrome.

These are seen more frequently with small cell lung cancer, making this the most likely diagnosis in this case. Ectopic ACTH production is also associated but rare.

Squamous cell carcinoma is associated with:

- gynaecomastia
- hyperthyroidism
- hypertropic pulmonary osteoarthropathy (HPOA) finger-clubbing, periostitis and arthritis
- hypercalcaemia usually secondary to secretion of PTH-related peptide.

Common to both:

- Clubbing
- Smoking: he is likely to be a smoker or ex-smoker and have COPD as he is on inhalers.

A Adenocarcinoma of the lung

Suspected lung malignancy with hyponatraemia and Lambert-Eaton myasthenic syndrome would be more compatible with small cell lung cancer than adenocarcinoma.

B Squamous carcinoma of the lung

Suspected lung malignancy with hyponatraemia and Lambert-Eaton myasthenic syndrome would be more compatible with small cell lung cancer than squamous cell carcinoma. Although the calcium is elevated, this minor elevation could well be consistent with dehydration rather than PTHrp

D Mesothelioma

Mesothelioma classically presents as progressive pleural thickening ± pleural effusion. This is not seen here, and there are no pleural or diaphragmatic calcified plaques, or features in the history, to suggest previous asbestos exposure.

E Bronchioalveolar carcinoma

This is a subtype of adenocarcinoma but with different characteristics and management. It presents more commonly in non-smokers, and has no gender predominance (unlike other forms of lung cancer which show a male predominance). Patients may present asymptomatically in up to 50% of cases. The paraneoplastic features make small cell lung cancer more likely than bronchioalveolar carcinoma in this case.

70133

Rate this question:

Next Question

Previous Question | Tag Question

Feedback | End Session

Difficulty: Average

Peer Responses %

Session Progress

Responses Correct:	0
Responses Incorrect:	246
Responses Total:	246
Responses - % Correct:	0%

© Pastest 2017

A 72-year-old gentleman is referred to the Respiratory Outpatients Clinic with a 2-month history of increasing shortness of breath and cough. Over the last few weeks he has coughed up a few streaks of blood. He has also noticed difficulty getting up from a chair. He has noticed that his clothes are looser without having tried to lose weight. He takes inhaled medication but cannot remember their names.

On examination he is clubbed. Auscultation of his chest reveals reduced expansion and breath sounds on the left. Heart sounds are normal. He has a 2 cm hepatomegaly on palpation of his abdomen. He has reduced power (4/5) on hip flexion bilaterally and generally reduced tendon reflexes. Plantars both show a flexor response; proprioception and sensation are normal.

Investigations:

Hb	10.9 g/dl
WCC	12.2 x10^9/l
PLT	491 x10^9/l
MCV	79 fl
ESR	58 mm/1st hour
Na^+	126 mmol/l
K^+	3.6 mmol/l
Urea	5.9 mmol/l
Creatinine	125 micromol/l
Bilirubin	49 micromol/l
AST	120 U/l
ALP	441 U/l
Albumin	32 g/l
Corrected Calcium	2.74 mmol/l
Phosphate	0.81 mmol/l

His CXR is shown;

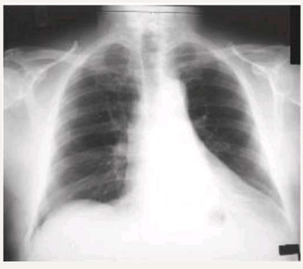

How would you treat this patient?

A	Radiotherapy
B	Lobectomy
C	Pneumonectomy
D	Chemotherapy
E	Best supportive care

70134

Submit

Previous Question | Skip Question

Calculator

Normal Values

© Pastest 2017

A 72-year-old gentleman is referred to the Respiratory Outpatients Clinic with a 2-month history of increasing shortness of breath and cough. Over the last few weeks he has coughed up a few streaks of blood. He has also noticed difficulty getting up from a chair. He has noticed that his clothes are looser without having tried to lose weight. He takes inhaled medication but cannot remember their names.

On examination he is clubbed. Auscultation of his chest reveals reduced expansion and breath sounds on the left. Heart sounds are normal. He has a 2 cm hepatomegaly on palpation of his abdomen. He has reduced power (4/5) on hip flexion bilaterally and generally reduced tendon reflexes. Plantars both show a flexor response; proprioception and sensation are normal.

Investigations:

Hb	10.9 g/dl
WCC	12.2 $x10^9$/l
PLT	491 $x10^9$/l
MCV	79 fl
ESR	58 mm/1st hour
Na^+	126 mmol/l
K^+	3.6 mmol/l
Urea	5.9 mmol/l
Creatinine	125 micromol/l
Bilirubin	49 micromol/l
AST	120 U/l
ALP	441 U/l
Albumin	32 g/l
Corrected Calcium	2.74 mmol/l
Phosphate	0.81 mmol/l

His CXR is shown;

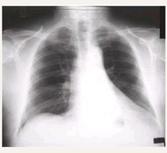

How would you treat this patient?

A	Radiotherapy
B	Lobectomy
C	Pneumonectomy
D	Chemotherapy
E	Best supportive care

Explanation

D	Chemotherapy

The chest X-ray shows left lower lobe collapse. There is loss of volume of the left hemi-thorax and the classical 'sail sign' behind the heart.

This man has radiological and clinical features suggestive of a lung malignancy weight loss, haemoptysis, dyspnoea and hypercalcaemia.

He also has features of paraneoplastic syndromes, making small cell lung cancer the most likely diagnosis in this case:

- hyponatraemia secondary to the syndrome of inappropriate antidiuretic hormone secretion
- the proximal weakness and hyporeflexia which, along with autonomic features, represents Lambert-Eaton myasthenic syndrome.

Platinum-based combination chemotherapy represents the mainstay of treatment for small cell lung cancer (SCLC), as per current NICE guidelines, ± radiotherapy dependent on the stage of the disease at the time of diagnosis or response to chemotherapy. Those with limited-stage disease, or with extensive disease that shows a complete response to chemotherapy at distant sites, should be considered for adjunctive radiotherapy. Because SCLC has a predilection for early metastasis, surgery has a limited role in management in comparison to other lung cancer subtypes.

A	Radiotherapy

Radiotherapy is an inappropriate monotherapy in the treatment of SCLC - chemotherapy is the most appropriate choice. Some patients may benefit from chemo-radiotherapy depending on their disease stage and response to chemotherapy.

B	Lobectomy

Surgery in the case of widely metastatic SCLC would not provide a curative option, and it would be inappropriate in this case; chemotherapy represents the treatment of choice.

C	Pneumonectomy

Surgery in the case of widely metastatic SCLC would not provide a curative option, and it would be inappropriate in this case; chemotherapy represents the treatment of choice.

E	Best supportive care

SIGN guidelines state that 'Patients have a high objective response rate to [systemic anti-cancer therapy], with useful symptomatic improvement' and therefore it should be at least considered in all patients with SCLC. Age should not be a factor in itself, but consideration should be given to best supportive care in those patients with, for example, poor performance status (WHO PS 3-4) or other life-limiting disease.

70134

Rate this question:

Next Question

Previous Question | Tag Question

Feedback | End Session

Difficulty: Average

Peer Responses %

Session Progress

Responses Correct:	0
Responses Incorrect:	247
Responses Total:	247
Responses - % Correct:	0%

© Pastest 2017

A 45-year-old man presented to his GP with a gradual onset of shortness of breath and increasing difficulty swallowing.

His CXR is shown below:

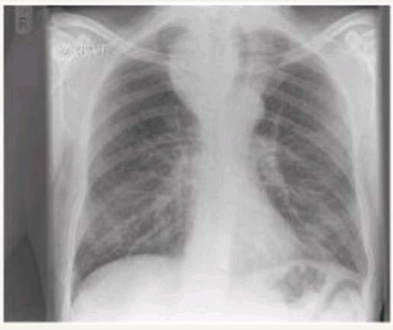

His flow-volume loop is shown below:

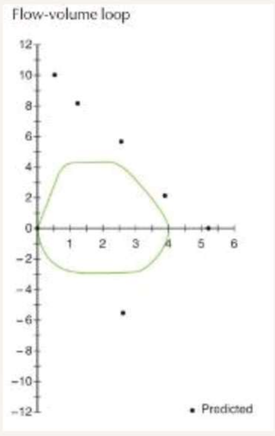

What does the flow-volume loop show?

A	Fixed extrathoracic airflow obstruction
B	Variable extra-thoracic airflow obstruction
C	Intrathoracic airflow obstruction
D	Restrictive lung disease
E	Obstructive lung disease

70135

Submit

Previous Question | Skip Question

Calculator

Normal Values

© Pastest 2017

A 45-year-old man presented to his GP with a gradual onset of shortness of breath and increasing difficulty swallowing.

His CXR is shown below:

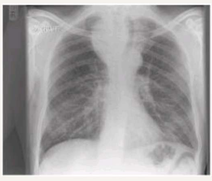

His flow-volume loop is shown below:

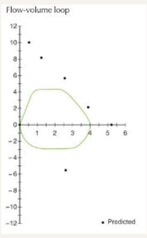

What does the flow-volume loop show?

A	Fixed extrathoracic airflow obstruction
B	Variable extra-thoracic airflow obstruction
C	Intrathoracic airflow obstruction
D	Restrictive lung disease
E	Obstructive lung disease

Explanation

A	Fixed extrathoracic airflow obstruction

The flow-volume loop shows a fixed extrathoracic airflow obstruction – both inspiratory and expiratory flow is blunted. This is caused by the large goitre shown on the chest X-ray. In extrathoracic obstructions flow tends to be constant throughout the first part of expiration rather than decelerating. The inspiratory flow is even more reduced. Normally, inspiratory flow is promoted by the negative intrathoracic pressure pulling the intrathoracic airways open. The extrathoracic obstruction prevents this from happening, thus reducing inspiratory flow. Another cause of fixed extrathoracic obstruction is tracheal stenosis. Variable extrathoracic obstruction does not affect the expiratory flow. Causes include: tracheal tumours, vocal cord paralysis and pharyngeal muscle weakness.

B	Variable extra-thoracic airflow obstruction

In variable extra-thoracic obstruction there is a varying degree of obstruction during inspiration and expiration. The flow-volume loop demonstrates a reduced inspiratory curve, with less effect on the expiratory curve as the positive pressure in the airway leads to reduced obstruction. Causes of variable extra-thoracic obstruction include vocal cord paralysis.

C	Intrathoracic airflow obstruction

In this case, the flow volume loop would show a normal or near-normal inspiratory component, with flattening of the expiratory component.

D	Restrictive lung disease

Flow-volume loops typically demonstrate reduced tidal volume (therefore less excursion on the X-axis), with steep expiratory and end-inspiratory curves.

E	Obstructive lung disease

These typically feature a ‘concave’ or ‘hollowed-out’ inspiratory curve.

70135

Rate this question:

Next Question

Previous Question | Tag Question

Feedback | End Session

Difficulty: Average

Peer Responses %

Session Progress

Responses Correct:	0
Responses Incorrect:	248
Responses Total:	248
Responses - % Correct:	0%

© Pastest 2017

A 31-year-old woman presented to the Respiratory Outpatients Department with a 3-year history of increasing shortness of breath and cough. She had required numerous courses of antibiotics in the last few years. She was a smoker of 5/day for 5 years but gave up 4 years ago. Respiratory examination revealed a hyper-inflated chest and a mild wheeze throughout.

Lung function tests:

FEV_1	50% predicted
FVC	80% predicted
TLCO	68% predicted
KCO	71% predicted
RV:TLC	Increased

What is the diagnosis?

A	COPD
B	Asthma
C	Cystic fibrosis
D	Bronchiectasis
E	Alpha-1-antitrypsin deficiency

70138

Submit

Previous Question | Skip Question

Calculator

Normal Values

© Pastest 2017

A 31-year-old woman presented to the Respiratory Outpatients Department with a 3-year history of increasing shortness of breath and cough. She had required numerous courses of antibiotics in the last few years. She was a smoker of 5/day for 5 years but gave up 4 years ago. Respiratory examination revealed a hyper-inflated chest and a mild wheeze throughout.

Lung function tests:

FEV_1	50% predicted
FVC	80% predicted
TLCO	68% predicted
KCO	71% predicted
RV:TLC	Increased

What is the diagnosis?

A	COPD
B	Asthma
C	Cystic fibrosis
D	Bronchiectasis
E	Alpha-1-antitrypsin deficiency

Explanation

E	Alpha-1-antitrypsin deficiency

Alpha-1-antitrypsin deficiency is a rare autosomal recessive disease associated with the development of premature panlobular emphysema, most severe in the basal areas of the lungs.Emphysema is thought to result from an imbalance in the lung between neutrophil elastase (which destroys elastin) and the elastase inhibitor α1-antitrypsin (which protects against the proteolytic degradation by elastin). The decline in lung function is accelerated in smokers.

Patients usually present with progressive increasing shortness of breath and weight loss. Corpulmonale and polycythaemia occur later in the course of the disease. A chest X-ray usually shows bilateral bibasal emphysema. Lung function tests show an obstructive picture and the RV:TLC ratio is raised, indicating gas trapping. Transfer factor will be reduced. There are a number of different phenotypes depending on the serum level of α1-antitrypsin:
Pi – protease inhibitor
M – normal allele
S, X and null are disease alleles

Phenotype	α1-Antitrypsin level	Disease
PiMM	Normal	
PiMS	80%	
PiMZ	60%	
PiSS	60%	
PiSZ	40%	Liver cirrhosis/premature emphysema
Pi Null Null	Nil	Premature emphysema

Treatment is similar to that of asthma. Alpha1-antitrypsin replacement can be given weekly or monthly and is recommended for those with very low serum levels and abnormal lung function. Lung transplantation should be considered in advanced disease. Patients should be encouraged to stop smoking.

A	COPD

Her disease severity coupled with her minimal smoking history makes α1-antitrypsin deficiency more likely.

B	Asthma

The lung function pattern and history suggesting lack of variability in symptoms is more in keeping with emphysema.

C	Cystic fibrosis

Respiratory problems in CF would usually be present since infancy. She has no other features of CF such as pancreatic insufficiency, sinus disease, liver disease or diabetes.

D	Bronchiectasis

The gas trapping and reduced gas transfer are more in keeping with emphysema in this history.

70138

Rate this question:

Next Question

Previous Question | Tag Question

Feedback | End Session

Difficulty: Average

Peer Responses %

Session Progress

Responses Correct:	0
Responses Incorrect:	249
Responses Total:	249
Responses - % Correct:	0%

© Pastest 2017

A 64-year-old man was referred to the clinic with insomnia. He complained of falling asleep during the day and having an early morning headache. He had a past history of a cholecystectomy and gout. He took no other regular medication. Examination was unremarkable. His weight and height were 120 kg and 175 cm, respectively

Investigations:

Hb	16.1 g/dl
WCC	6.4×10^9/l
PLT	94×10^9/l
MCV	101 fl
TSH	1.2 mU/l

Which of the following investigations would most aid diagnosis?

A	ABG
B	Sleep studies
C	CXR
D	CT thorax
E	Body plethysmography

70139

Submit

Previous Question | Skip Question

Calculator

Normal Values

© Pastest 2017

A 64-year-old man was referred to the clinic with insomnia. He complained of falling asleep during the day and having an early morning headache. He had a past history of a cholecystectomy and gout. He took no other regular medication. Examination was unremarkable. His weight and height were 120 kg and 175 cm, respectively

Investigations:

Hb	16.1 g/dl
WCC	6.4 × 10^9/l
PLT	94 × 10^9/l
MCV	101 fl
TSH	1.2 mU/l

Which of the following investigations would most aid diagnosis?

A	ABG
B	Sleep studies
C	CXR
D	CT thorax
E	Body plethysmography

Explanation

B	Sleep studies

This patient has obstructive sleep apnoea (OSA), suggested by insomnia, daytime somnolence, morning headache and obesity. Other symptoms include poor concentration during the day, and partners may describe snoring followed by apnoeic episodes.

Diagnosis is made using the Epworth score, which is a measure of daytime somnolence, and sleep studies, which would show apnoeic/hypopnoeic episodes associated with desaturations, increase in heart rate and arousal from sleep. Treatment will depend on severity of symptoms and desaturations. In most cases weight loss is advisable.

In mild OSA syndrome a mandibular advancement device may control symptoms. In moderate to severe OSA syndrome, nocturnal non-invasive ventilation (NIV) using continuous positive airway pressure (CPAP) can be considered. Early-morning headaches can be caused by a transient hypercapnia, which corrects to normal when the patient is awake. If a patient has hypercapnia in waking hours (and not just on an early morning blood gas) then overlap syndrome with obesity hypoventilation syndrome should be considered, although severe OSA may cause persistent hypercapnoea in some cases. Patients with persistent hypercapnoea should be considered for bi-level positive airway pressure (BiPAP).

It is important to exclude underlying causes; this patient has a history of gout which, together with the raised MCV and low platelets, suggests alcohol consumption, which can precipitate the problem. Hypothyroidism, acromegaly and sedating drugs also need to be excluded. Retrognathia can cause OSA, and large tonsils may obstruct the airway.

A	ABG

Arterial blood gases would be helpful in assessing for hypercapnoea, but are not diagnostic of OSA.

C	CXR

Radiology is usually normal in obstructive sleep apnoea.There are no respiratory symptoms to suggest an intrathoracic pathology that would require a CXR.

D	CT thorax

Radiology is usually normal in obstructive sleep apnoea.There are no respiratory symptoms to suggest an intrathoracic pathology that would require a CT.

E	Body plethysmography

Body plethysmography may reveal restrictive lung function with a normal gas transfer but this is not a diagnostic test for OSA.

70139

Rate this question:

Next Question

Previous Question | Tag Question

Feedback | End Session

Difficulty: Average

Peer Responses %

Session Progress

Responses Correct:	0
Responses Incorrect:	250
Responses Total:	250
Responses - % Correct:	0%

© Pastest 2017

A 64-year-old man was referred to the clinic with insomnia. He complained of falling asleep during the day and having an early morning headache. He had a past history of a cholecystectomy and gout. He took no other regular medication. Examination was unremarkable.

Weight	115 kg
Height	175 cm
Hb	16.1 g/dl
WCC	6.4 $x10^9$/l
PLT	94 $x10^9$/l
MCV	101 fl
TSH	1.2 mU/l
Glucose	8.2 mmol/l

What would the optimal management of this patient be over the long term?

A	Refer for non-invasive ventilation
B	Diuretics
C	Advise to lose weight
D	Refer to ENT surgeons
E	Doxapram

70140

Submit

Previous Question | Skip Question

Calculator

Normal Values

© Pastest 2017

A 64-year-old man was referred to the clinic with insomnia. He complained of falling asleep during the day and having an early morning headache. He had a past history of a cholecystectomy and gout. He took no other regular medication. Examination was unremarkable.

Weight	115 kg
Height	175 cm
Hb	16.1 g/dl
WCC	6.4 $x10^9$/l
PLT	94 $x10^9$/l
MCV	101 fl
TSH	1.2 mU/l
Glucose	8.2 mmol/l

What would the optimal management of this patient be over the long term?

A	Refer for non-invasive ventilation
B	Diuretics
C	Advise to lose weight
D	Refer to ENT surgeons
E	Doxapram

Explanation

C Advise to lose weight

This patient has obstructive sleep apnoea (OSA) – insomnia, daytime sommolence, morning headache and obesity. Other symptoms include poor concentration during the day and partners may describe snoring followed by apnoeic episodes.

Diagnosis is made using the Epworth score – which is a measure of daytime somnolence – and sleep studies, which would show apnoeic/hypopnoeic episodes associated with desaturations, increase in heart rate and arousal from sleep. Treatment will depend on severity of symptoms and desaturations. In most cases weight loss is advisable.

In mild OSA syndrome a mandibular advancement device may control symptoms in mild to sever OSA syndrome nocturnal non-invasive ventilation (NIV) using continuous positive airway pressure (CPAP). Early morning headaches can be caused by a transient hypercapnia.This normal corrects to normal when the patient is awake.If a patient has hypercapnia in waking hours (and not just on an early morning blood gas) then overlap syndrome with obesity hypoventilation syndrome should be considered, although severe OSA may cause persisitenthypercapnoea in some case. Patients with persistent hypercapnoea should be considered for bilevel positive airway pressure (egBiPAP).
It is important to exclude underlying causes – this patient has a history of gout which, together with the raised MCV and low platelets, suggests alcohol consumption, which can precipitate the problem. Hypothyroidism, acromegaly and sedating drugs also need to be excluded. Retrognathia can cause OSA and large tonsils may obstruct the airway.

A Refer for non-invasive ventilation

Although NIV is optimal for relief of symptoms, over the long term, given significant risk of type 2 diabetes and diseases associated with insulin resistance, weight loss is preferred long term.

B Diuretics

Diuretics would be an appropriate treatment for pulmonary oedema.

D Refer to ENT surgeons

Surgery is used as a last resort as a treatment for OSA and is often unsuccessful.

E Doxapram

Doxopram is a repiratory stimulant with a vast array of side effects previously used to treat acute type 2 resiratory failure. It has been supercededby non invasive ventilation now.

70140

Rate this question:

Next Question

Previous Question | Tag Question

Feedback | End Session

Difficulty: Average

Peer Responses %

Session Progress

Responses Correct:	0
Responses Incorrect:	251
Responses Total:	251
Responses - % Correct:	0%

© Pastest 2017

A 64-year-old man was referred to the clinic with insomnia. He complained of falling asleep during the day and having an early morning headache. He had a past history of a cholecystectomy and gout. He took no other regular medication. Examination was unremarkable. His weight and height were 120 kg and 175 cm, respectively.

Investigations:

Weight	120 kg
Height	175 cm
Hb	16.1 g/dl
WCC	6.4 $x10^9$/l
PLT	94 $x10^9$/l
MCV	101 fl
TSH	1.2 mU/l

What underlying cause should be suspected in this patient?

A	Acromegaly
B	Alcohol excess
C	Hypothyroidism
D	Cushing's disease
E	Enlarged tonsils

70141

Submit

Previous Question | Skip Question

Calculator

Normal Values

© Pastest 2017

A 64-year-old man was referred to the clinic with insomnia. He complained of falling asleep during the day and having an early morning headache. He had a past history of a cholecystectomy and gout. He took no other regular medication. Examination was unremarkable. His weight and height were 120 kg and 175 cm, respectively.

Investigations:

Weight	120 kg
Height	175 cm
Hb	16.1 g/dl
WCC	6.4 $x10^9$/l
PLT	94 $x10^9$/l
MCV	101 fl
TSH	1.2 mU/l

What underlying cause should be suspected in this patient?

A	Acromegaly
B	Alcohol excess
C	Hypothyroidism
D	Cushing's disease
E	Enlarged tonsils

Explanation

B	Alcohol excess

This patient has obstructive sleep apnoea (OSA) – insomnia, daytime sommolence, morning headache and obesity. Other symptoms include poor concentration during the day and partners may describe snoring followed by apnoeic episodes.

Diagnosis is made using the Epworth score – which is a measure of daytime somnolence – and sleep studies, which would show apnoeic/hypopnoeic episodes associated with desaturations, increase in heart rate and arousal from sleep. Treatment will depend on severity of symptoms and desaturations. In most cases, weight loss is advisable.

In mild OSA syndrome, a mandibular advancement device may control symptoms in mild to sever OSA syndrome nocturnal non-invasive ventilation (NIV) using continuous positive airway pressure (CPAP). Early morning headaches can be caused by a transient hypercapnia. This corrects to normal when the patient is awake. If a patient has hypercapnia in waking hours (and not just on an early morning blood gas) then overlap syndrome with obesity hypoventilation syndrome should be considered, although severe OSA may cause persisitenthypercapnoea in some cases. Patients with persistent hypercapnoea should be considered for bilevel positive airway pressure (egBiPAP).

It is important to exclude underlying causes – this patient has a history of gout which, together with the raised MCV and low platelets, suggests alcohol consumption, which can precipitate the problem. Hypothyroidism, acromegaly and sedating drugs also need to be excluded. Retrognathia can cause OSA and large tonsils may obstruct the airway.

A	Acromegaly

Acromegaly is associated with OSA but there are no features in the history to suggest this over the more likely diagnosis of alcohol excess.

C	Hypothyroidism

The patient's TSH is not raised, making this an unlikely diagnosis.

D	Cushing's disease

Cushing's disease may be associated with OSA, but there are no features in the history or blood tests to suggest this as the more likely diagnosis versus alcohol excess.

E	Enlarged tonsils

Enlarged tonsils may be associated with OSA, but the history and blood tests are more strongly suggestive of alcohol excess.

70141

Rate this question:

Next Question

Previous Question | Tag Question

Feedback | End Session

Difficulty: Average

Peer Responses %

Session Progress

Responses Correct:	0
Responses Incorrect:	252
Responses Total:	252
Responses - % Correct:	0%

© Pastest 2017

An 18-year-old woman presents with increasing shortness of breath and nasal congestion. She has a past history of recurrent chest infections. On examination her fingers appear as shown below. Her sputum is mucopurulent.

Her CXR is shown below:

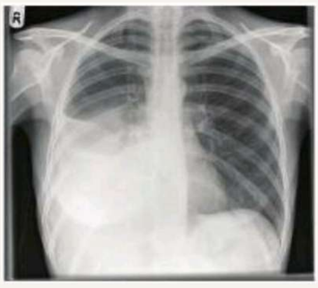

Appearance	Clear
Protein	35 g/l
WCC	2440 (80% lymphocytes)

What is the most likely diagnosis?

A	Cystic fibrosis
B	Yellow-nail syndrome
C	Filariasis
D	Meigs' syndrome
E	Tuberculosis

70142

Submit

Previous Question | Skip Question

Calculator

Normal Values

© Pastest 2017

An 18-year-old woman presents with increasing shortness of breath and nasal congestion. She has a past history of recurrent chest infections. On examination her fingers appear as shown below. Her sputum is mucopurulent.

Her CXR is shown below:

Appearance	Clear
Protein	35 g/l
WCC	2440 (80% lymphocytes)

What is the most likely diagnosis?

A	Cystic fibrosis
B	Yellow-nail syndrome
C	Filariasis
D	Meigs' syndrome
E	Tuberculosis

Explanation

B	Yellow-nail syndrome

This girl has yellow-nail syndrome which is a rare condition consisting of the triad of primary lymphoedema, recurrent pleural effusions and dystrophic yellow nails. It is associated with bronchiectasis and sinusitis. Pleural fluid is typically a clear exudate in which lymphocytes predominate. The underlying abnormality is hypoplasia of the lymphatics with impaired drainage. This results in subungual oedema, lymphoedema and pleural effusions.

A	Cystic fibrosis

Cystic fibrosis would be expected to present with respiratory symptoms from infancy, is not usually associated with pleural effusions, and would be expected to cause finger-clubbing, not dystrophic nails.

C	Filariasis

Filariasis is a cause of lymphoedema (most commonly of the legs and external genitals), secondary to microfilariae being introduced into the skin by mosquitoes and migrating to the lymphatics. It may present asymptomatically or with infective symptoms of fever/rigors/myalgia, and lymphangitis. It can be associated with chylous pleural effusions.

D	Meigs' syndrome

This is a rare condition comprised of the triad of pleural effusions, ascites and benign ovarian tumours – usually fibromas.

E	Tuberculosis

TB may present as a lymphocytic pleural effusion, but with the history of recurrent chest infections rather than an acute illness and no mention of night sweats, fevers or weight loss, alongside the examination finding of dystrophic nails, it is less likely than yellow nail syndrome.

70142

Rate this question:

Next Question

Previous Question | Tag Question

Feedback | End Session

Difficulty: Average

Peer Responses %

Session Progress

Responses Correct:	0
Responses Incorrect:	253
Responses Total:	253
Responses - % Correct:	0%

© Pastest 2017

A 25-year-old man is brought to the Emergency Department following a road traffic accident in which he was thrown off his motorbike. He is the subject of a trauma call. He is complaining of pain in his chest and upper abdomen which radiates to his back and left shoulder. He was previously fit and well.

On examination he looks unwell. BP 90/55 mmHg, pulse 130/min. He is bruised and tender over his anterior chest wall. Auscultation of his chest reveals quiet breath sounds at the left base.

His CXR is shown below:

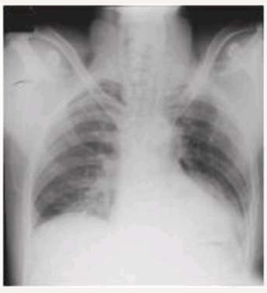

A chest drain is inserted in the Emergency Department.

Pleural fluid protein	45 g/l
Pleural amylase	240 U/l
Serum amylase	190 U/l

What is the diagnosis?

A	Oesophageal rupture
B	Pancreatitis
C	Rib fractures and haemothorax
D	Chylothorax
E	Aortic dissection

70143

Submit

Previous Question | Skip Question

Calculator

Normal Values

© Pastest 2017

A 25-year-old man is brought to the Emergency Department following a road traffic accident in which he was thrown off his motorbike. He is the subject of a trauma call. He is complaining of pain in his chest and upper abdomen which radiates to his back and left shoulder. He was previously fit and well.

On examination he looks unwell. BP 90/55 mmHg, pulse 130/min. He is bruised and tender over his anterior chest wall. Auscultation of his chest reveals quiet breath sounds at the left base.

His CXR is shown below:

A chest drain is inserted in the Emergency Department.

Pleural fluid protein	45 g/l
Pleural amylase	240 U/l
Serum amylase	190 U/l

What is the diagnosis?

A	Oesophageal rupture
B	Pancreatitis
C	Rib fractures and haemothorax
D	Chylothorax
E	Aortic dissection

Explanation

A	Oesophageal rupture

Oesophageal rupture is a serious condition following trauma, violent vomiting or endoscopic procedures, or can be associated with malignancy. Spillage of gastric contents into the pleurae causes shock and pain. The chest X-ray usually shows a left pleural effusion or hydro-pneumothorax. There may also be air in the soft tissues (as in this patient), termed surgical emphysema. Pleural fluid is an exudate, and amylase levels are high. The ratio of pleural fluid amylase to serum amylase is >1.0. Iso-enzyme analysis can be useful, as oesophageal rupture will show the amylase to be salivary in origin.
Diagnosis is made radiologically using water-soluble contrast. Surgical treatment is required and mortality is high.

B	Pancreatitis

Serum amylase is only mildly raised, making an acute pancreatitis unlikely. Serum amylase can be normal in chronic pancreatitis, but from the history the patient was previously fit and well. The history of trauma in this case makes oesophageal rupture a more likely diagnosis.

C	Rib fractures and haemothorax

There are no rib fractures visible on the CXR and no mention of blood in the pleural tap.

D	Chylothorax

A chylothorax may be caused by a tear in the thoracic duct, which could occur with trauma. Pleural fluid has a milky appearance and pleural triglyceride levels are high, neither of which is mentioned here. The amylase values in serum and pleural fluid make oesophageal rupture more likely.

E	Aortic dissection

The mediastinum is not broadened, and pleural effusion with high amylase levels is more in keeping with oesophageal rupture.

70143

Rate this question:

Next Question

Previous Question | Tag Question

Feedback | End Session

Difficulty: Average

Peer Responses %

Session Progress

Responses Correct:	0
Responses Incorrect:	254
Responses Total:	254
Responses - % Correct:	0%

© Pastest 2017

A 36-year-old man presents with increasing shortness of breath and a cough, which is worse at night. He has no significant past medical history. He has never smoked. He works as a car mechanic, restoring run-down cars. He notes that his symptoms are often better at the weekend.

Investigations:

FEV_1	70% of normal
FVC	85% of normal
PEFR	450 l/min
Histamine challenge test	20% fall in FEV_1 with 2 micromol/l histamine (normal >4)

What is the most likely diagnosis?

A	Carbon monoxide poisoning
B	Occupational asthma
C	Silicosis
D	Extrinsic Allergic Alveolitis
E	Hyperactive airways

70144

Submit

Previous Question | Skip Question

Calculator

Normal Values

© Pastest 2017

A 36-year-old man presents with increasing shortness of breath and a cough, which is worse at night. He has no significant past medical history. He has never smoked. He works as a car mechanic, restoring run-down cars. He notes that his symptoms are often better at the weekend.

Investigations:

FEV_1	70% of normal
FVC	85% of normal
PEFR	450 l/min
Histamine challenge test	20% fall in FEV_1 with 2 micromol/l histamine (normal >4)

What is the most likely diagnosis?

A	Carbon monoxide poisoning
B	Occupational asthma
C	Silicosis
D	Extrinsic Allergic Alveolitis
E	Hyperactive airways

Explanation

B Occupational asthma

This man has occupational asthma secondary to isocyanates, which are found in paints used to spray cars. Occupational asthma is characterised by airway obstruction and/or bronchial hyper-reactivity induced by a person's occupation. His spirometry reveals an obstructive picture with a hyper-responsive histamine challenge test. Diagnosis is confirmed by asking the patient to do 2 h peak flows both at his place of work and at home, and ideally during a period of leave from work, to look for significant differences and worsening of PEFR at work.

Other occupations commonly associated with occupational asthma that may come up in the MRCP exam include: bakers, vets, hairdressers, pharmaceutical workers, welders, roofers and textile workers.

A Carbon monoxide poisoning

Carbon monoxide poisoning presents as a flu-like illness with malaise and fatigue. There is dyspnoea on exertion and chest pain with palpitations can occur. As exposure progresses, lethargy, hallucinations, agitation and confusion occur, eventually leading to coma. Patients may also experience headache, abdominal pain with nausea, vomiting and diarrhoea.

C Silicosis

Silicosis is associated with occupations such as foundry work, hard rock mining and civil engineering, and is due to inhalation of silicon dioxide. The history does not suggest this.

D Extrinsic Allergic Alveolitis

There is no history of allergen exposure to suggest EAA, which usually presents as a flu-like illness with dyspnoea soon after exposure to the offending allergen.

E Hyperactive airways

The patient does have hyperactive airways, but the 20% drop in FEV_1 on histamine challenge confirms a diagnosis of asthma as the underlying cause.

70144

Rate this question:

Next Question

Previous Question | Tag Question

Feedback | End Session

Difficulty: Average

Peer Responses %

Session Progress

Responses Correct:	0
Responses Incorrect:	255
Responses Total:	255
Responses - % Correct:	0%

© Pastest 2017

A 34-year-old HIV-positive man presented to hospital complaining of increasing shortness of breath and cough. He had noticed his vision was slightly worse over the last few weeks. He had prolonged admission 4 months previously with a chest complaint. He has been taking prophylactic co-trimoxazole. He is a current smoker with a 10- pack year historysmoked 20 cigarettes/day. On examination he looked unwell. Pulse was 110/min, respiratory rate 28/min, BP 95/65 mmHg and saturations 91% on air. Auscultation of his chest revealed fine crackles bilaterally. The CXR shows reticular shadowing throughout both lung fields.

Investigations:

Hb	9.4 g/dl
WCC	3.2 x10^9/l
PLT	511 x10^9/l
MCV	84 fl
CD4 count	10/mm^3
Na^+	139 mmol/l
K^+	4.2 mmol/l
Urea	6.1 mmol/l
Creatinine	111 micromol/l
Bilirubin	52 micromol/l
AST	113 U/l
ALP	121 U/l
Albumin	34 U/l
TLCO	110% predicted

What is the likely diagnosis?

A	*Pneumocystis jirovecii* pneumonia
B	CMV pneumonitis
C	Nocardia infection
D	Tuberculosis
E	Streptococcal pneumonia

70145

Submit

Previous Question | Skip Question

Calculator

Normal Values

© Pastest 2017

A 34-year-old HIV-positive man presented to hospital complaining of increasing shortness of breath and cough. He had noticed his vision was slightly worse over the last few weeks. He had prolonged admission 4 months previously with a chest complaint. He has been taking prophylactic co-trimoxazole. He is a current smoker with a 10- pack year historysmoked 20 cigarettes/day. On examination he looked unwell. Pulse was 110/min, respiratory rate 28/min, BP 95/65 mmHg and saturations 91% on air. Auscultation of his chest revealed fine crackles bilaterally. The CXR shows reticular shadowing throughout both lung fields.

Investigations:

Hb	9.4 g/dl
WCC	3.2 $x10^9$/l
PLT	511 $x10^9$/l
MCV	84 fl
CD4 count	10/mm^3
Na^+	139 mmol/l
K^+	4.2 mmol/l
Urea	6.1 mmol/l
Creatinine	111 micromol/l
Bilirubin	52 micromol/l
AST	113 U/l
ALP	121 U/l
Albumin	34 U/l
TLCO	110% predicted

What is the likely diagnosis?

A	*Pneumocystis jirovecii* pneumonia
B	CMV pneumonitis
C	Nocardia infection
D	Tuberculosis
E	Streptococcal pneumonia

Explanation

B CMV pneumonitis

This patient has a cytomegalovirus (CMV) infection. CMV is one of the most frequent opportunistic infections in patients with advanced HIV disease. A CD4 count <50 cells/mm^3 carries high risk of the disease.

It can cause hepatitis, colitis, retinitis, pneumonitis, radiculopathy and encephalitis. The reduced visual acuity and abnormal liver function tests also are more in keeping with CMV.

In the immunosuppressed, serology may be of little value. Diagnosis is made by polymerase chain reaction (PCR) of serum. Histological staining of transbronchial biopsies may demonstrate the pathognomic 'owl's eye' cells. Other techniques include rapid culture methods such as DEAFF (detection of early antigen fluorescent foci) by monoclonal antibody.

Treatment is with intravenous ganciclovir.

A *Pneumocystis jirovecii* pneumonia

Clinically and radiologically, CMV pneumonia mimics *P. jirovecii* pneumonia (PJP). However, this patient was on prophylactic co-trimoxazole, making PJP less likely.

C Nocardia infection

Nocardiosis can occur in immunocompromised patients, but CXR usually shows cavitation plus/minus pleural effusion. Skin abscesses may be present. The diffuse CXR shadowing combined with eye symptoms and deranged LFTs make CMV disease more likely.

D Tuberculosis

TB is more common in immunocompromised patients, and miliary TB may affect multiple organs, but the combination of diffuse CXR shadowing, deranged LFTs and eye symptoms in particular make CMV disease more likely.

E Streptococcal pneumonia

There is multi-organ involvement here, making streptococcal pneumonia less likely.

70145

Rate this question:

Next Question

Previous Question	Tag Question
Feedback	End Session

Difficulty: Average

Peer Responses %

Session Progress

Responses Correct:	0
Responses Incorrect:	256
Responses Total:	256
Responses - % Correct:	0%

© Pastest 2017

A 16-year-old boy presents with a persistent cough productive of brown/green sputum. He occasionally produces a small amount of blood. His mother said he had always suffered from chest infections, requiring numerous courses of antibiotics. He also complained of offensive-smelling stools which were difficult to flush. On examination he looked small for his age. Auscultation of his chest revealed bi-basal coarse crackles.

Investigations:

Hb	11.2 g/dl
WBC	10.7 $x10^9$/l
PLT	511 $x10^9$/l
MCV	91 fl
Na^+	139 mmol/l
K^+	3.9 mmol/l
Urea	5.3 mmol/l
Creatinine	99 micromol/l
Bilirubin	18 micromol/l
AST	34 U/l
ALP	93 U/l
Albumin	39 g/l
TP	50 g/l

His CXR is shown below:

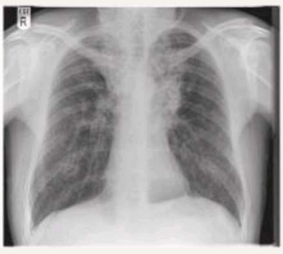

What is the diagnosis?

A	Cystic fibrosis
B	Kartagener's syndrome
C	Young's syndrome
D	X-linked hypogammaglobulinaemia
E	Eosinophilic granulomatosis with polyangiitis (Churg-Strauss)

70147

Submit

Previous Question | Skip Question

Calculator

Normal Values

© Pastest 2017

A 16-year-old boy presents with a persistent cough productive of brown/green sputum. He occasionally produces a small amount of blood. His mother said he had always suffered from chest infections, requiring numerous courses of antibiotics. He also complained of offensive-smelling stools which were difficult to flush. On examination he looked small for his age. Auscultation of his chest revealed bi-basal coarse crackles.

Investigations:

Hb	11.2 g/dl
WBC	10.7 x10^9/l
PLT	511 x10^9/l
MCV	91 fl
Na^+	139 mmol/l
K^+	3.9 mmol/l
Urea	5.3 mmol/l
Creatinine	99 micromol/l
Bilirubin	18 micromol/l
AST	34 U/l
ALP	93 U/l
Albumin	39 g/l
TP	50 g/l

His CXR is shown below:

What is the diagnosis?

A	Cystic fibrosis
B	Kartagener's syndrome
C	Young's syndrome
D	X-linked hypogammaglobulinaemia
E	Eosinophilic granulomatosis with polyangiitis (Churg-Strauss)

Explanation

D	X-linked hypogammaglobulinaemia

This patient has X-linked hypogammaglobulinaemia. The main clue is the low total protein with a normal albumin, demonstrating low levels of globulins.

Patients usually present in childhood with recurrent infections, which result in bronchiectasis if untreated, and malabsorption, in a similar way to patients with cystic fibrosis. All immunoglobulin classes and B cells and plasma cells are reduced.

The defect is in the differentiation of pre-B cells into B cells. T cells are normal. The gene defect is on the long arm of the X chromosome, making it an X-linked condition.

Treatment is with IV immunoglobulin therapy which, if started early, can prevent progression of disease.

The chest X-ray shows bronchiectasis – parallel thickened bronchial walls with a 'tram track' appearance.

A	Cystic fibrosis

Although the patient has symptoms compatible with CF, bronchiectasis visible on his CXR and the low total protein makes X-linked hypogammaglobulinaemia more likely.

B	Kartagener's syndrome

There is no dextrocardia seen on the CXR. Kartagener syndrome is associated with bronchiectasis, sinusitis and dextrocardia.

C	Young's syndrome

Young syndrome is not associated with malabsorption: it is the triad of bronchiectasis, rhinosinusitis and reduced fertility.

E	Eosinophilic granulomatosis with polyangiitis (Churg-Strauss)

An asthma/rhinitis prodrome to this condition is classical, followed by an eosinophilia and systemic vasculitis. The bronchiectasis seen on the CXR, and infective rather than asthmatic chest symptoms, make hypogammaglobulinaemia a more likely diagnosis.

70147

Rate this question:

Next Question

Previous Question | Tag Question

Feedback | End Session

Difficulty: Average

Peer Responses %

Session Progress

Responses Correct:	0
Responses Incorrect:	257
Responses Total:	257
Responses - % Correct:	0%

© Pastest 2017

A 16-year-old boy presents with a persistent cough productive of brown/green sputum. He occasionally produces a small amount of blood. His mother said he had always suffered from chest infections, requiring numerous courses of antibiotics. He also complained of offensive-smelling stools which were difficult to flush . On examination he looks small for his age. Auscultation of his chest revealsed bi-basal coarse crackles.

Investigations:

Hb	11.2 g/dl
WBC	10.7 $x10^9$/l
PLT	511 $x10^9$/l
MCV	91 fl
Na^+	139 mmol/l
K^+	3.9 mmol/l
Urea	5.3 mmol/l
Creatinine	99 micromol/l
Bilirubin	18 micromol/l
AST	34 U/l
ALP	93 U/l
Albumin	39 g/l
TP	50 g/l

His CXR is shown below:

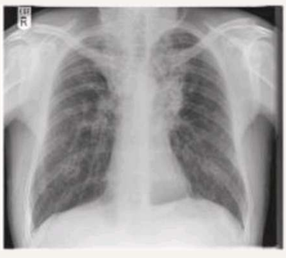

How would you make a diagnosis?

A	Sweat test
B	Measure immunoglobulins
C	High-resolution CT scan
D	Electron microscopy of cilia
E	Full lung function tests

70148

Submit

Previous Question | Skip Question

Calculator

Normal Values

© Pastest 2017

A 16-year-old boy presents with a persistent cough productive of brown/green sputum. He occasionally produces a small amount of blood. His mother said he had always suffered from chest infections, requiring numerous courses of antibiotics. He also complained of offensive-smelling stools which were difficult to flush . On examination he looks small for his age. Auscultation of his chest revealed bi-basal coarse crackles.

Investigations:

Hb	11.2 g/dl
WBC	10.7 x10^9/l
PLT	511 x10^9/l
MCV	91 fl
Na^+	139 mmol/l
K^+	3.9 mmol/l
Urea	5.3 mmol/l
Creatinine	99 micromol/l
Bilirubin	18 micromol/l
AST	34 U/l
ALP	93 U/l
Albumin	39 g/l
TP	50 g/l

His CXR is shown below:

How would you make a diagnosis?

A	Sweat test
B	Measure immunoglobulins
C	High-resolution CT scan
D	Electron microscopy of cilia
E	Full lung function tests

Explanation

B Measure immunoglobulins

This patient has X-linked hypogammaglobulinaemia. The main clue is the low total protein with a normal albumin, demonstrating low levels of globulins.

Patients usually present in childhood with recurrent infections, which result in bronchiectasis if untreated, and malabsorption, in a similar way to patients with cystic fibrosis. All immunoglobulin classes and B cells and plasma cells are reduced.
The defect is in the differentiation of pre-B cells into B cells. T cells are normal. The gene defect is on the long arm of the X chromosome, making it an X-linked condition.

Treatment is with IV immunoglobulin therapy which, if started early, can prevent progression of disease. The chest X-ray shows bronchiectasis – parallel thickened bronchial walls with a 'tram track' appearance.

A Sweat test

This is a diagnostic test for cystic fibrosis. This can present in infancy with failure to thrive, typically due to pancreatic insufficiency. Cough, recurrent chest infections, malabsorption and recurrent sinusitis are typical features. However, the low globulins in this patient's case make X-linked hypogammaglobulinaemia a more likely diagnosis here.

C High-resolution CT scan

This is a diagnostic test for primary ciliary dyskinesia, associated with chronic/recurrent respiratory infections and sinusitis. Up to 50% of patients with PCD have situs inversus. Kartagener syndrome is a subset of this condition, associated with bronchiectasis, sinusitis and dextrocardia.

D Electron microscopy of cilia

This would help diagnose bronchiectasis but would not reveal the underlying cause in this case.

E Full lung function tests

Lung function tests would help assess the severity of lung function impairment but would not be diagnostic of hypogammaglbulinaemia.

70148

Rate this question:

Next Question

Previous Question | Tag Question

Feedback | End Session

Difficulty: Average

Peer Responses %

Session Progress

Responses Correct:	0
Responses Incorrect:	258
Responses Total:	258
Responses - % Correct:	0%

© Pastest 2017

A 54-year-old man presented with increasing shortness of breath and orthopnoea. He had noticed these symptoms over the last few years but only went to his GP after he had had a severe episode of breathlessness when he went wading in the sea on holiday. On further enquiry he had also become aware of morning headaches and an increasing tendency to fall asleep during the day. On examination he looked well. Auscultation of his chest revealed reduced breath sounds and reduced percussion note bi-basally.

Serology Investigations:

Hb	17.7 g/dl
WCC	12.3 $x10^9$/l
PCV	0.51
PLT	289 $x10^9$/l

	Erect (% predicted)	Supine (% predicted)
Residual volume	105%	
Total lung capacity	80%	
Vital capacity	75%	50%
TLCO	70%	
KCO	95%	

Which of the following is the most helpful investigation in achieving the correct diagnosis?

A	CXR
B	Arterial blood gases
C	Ultrasound screening of the diaphragm
D	Echocardiogram
E	Gas transfer and transfer coefficient

70149

Submit

Previous Question | Skip Question

Calculator

Normal Values

© Pastest 2017

A 54-year-old man presented with increasing shortness of breath and orthopnoea. He had noticed these symptoms over the last few years but only went to his GP after he had had a severe episode of breathlessness when he went wading in the sea on holiday. On further enquiry he had also become aware of morning headaches and an increasing tendency to fall asleep during the day. On examination he looked well. Auscultation of his chest revealed reduced breath sounds and reduced percussion note bi-basally.

Serology Investigations:

Hb	17.7 g/dl
WCC	12.3 x10^9/l
PCV	0.51
PLT	289 x10^9/l

	Erect (% predicted)	Supine (% predicted)
Residual volume	105%	
Total lung capacity	80%	
Vital capacity	75%	50%
TLCO	70%	
KCO	95%	

Which of the following is the most helpful investigation in achieving the correct diagnosis?

A	CXR
B	Arterial blood gases
C	Ultrasound screening of the diaphragm
D	Echocardiogram
E	Gas transfer and transfer coefficient

Explanation

C	Ultrasound screening of the diaphragm

In bilateral diaphragmatic weakness, patients commonly present with breathlessness on exertion and when lying flat. It can be associated with sleep apnoea, resulting in daytime somnolence and headaches. The symptoms are due to the paroxysmal movement of the diaphragm during inspiration. In the supine position, expansion of the ribs results in movement of the abdominal contents into the chest, aided by gravity. Symptoms can be worse when standing up to the waist in water, as this counteracts the effects of gravity and prevents outward movement of the abdomen during inspiration and therefore produces a similar situation to being in the supine position. A chest X-ray may show relatively small lung fields and basal linear shadowing due to subsegmental collapse. A SNIF test (diaphragmatic screening on ultrasound) will show paradoxical movement of the diaphragm, particularly on sniffing. Blood gases may show a type II respiratory failure, particularly at night. Lung function tests classically show a low vital capacity, which falls further in the supine position. All lung volumes except the residual volume are reduced. GThe gas transfer tends to be mildly impaired with a normal KCO. Treatment is with non-invasive ventilation.

A	CXR

This may show relatively small lung fields but would not confirm diaphragmatic weakness.

B	Arterial blood gases

These may show respiratory failure (either type 1 or chronic type 2) but cannot be used to diagnose diaphragmatic weakness.

D	Echocardiogram

This would most likely be normal in this case, as the history is more in keeping with diaphragmatic weakness than cardiac disease.

E	Gas transfer and transfer coefficient

This would likely be normal, or only mildly impaired, in this case, and would not aid in confirming the diagnosis.

70149

Rate this question:

Next Question

Previous Question | Tag Question

Feedback | End Session

Difficulty: Average

Peer Responses %

Session Progress

Responses Correct:	0
Responses Incorrect:	259
Responses Total:	259
Responses - % Correct:	0%

© Pastest 2017

A 54-year-old man presented with increasing shortness of breath and orthopnoea. He had noticed these symptoms over the last few years but only went to his GP after he had had a severe episode of breathlessness when he went wading in the sea on holiday. On further enquiry, he had also become aware of morning headaches and an increasing tendency to fall asleep during the day.

On examination he looked well. Auscultation of his chest revealed reduced breath sounds and percussion note bi-basally.

Investigations:

Hb	17.7 g/dl
WCC	12.3 × 10^9/l
PLT	289 × 10^9/l
PCV	0.51
Residual volume Erect (% predicted)	105
Total lung capacity Erect (% predicted)	80
Vital capacity Erect (% predicted)/Supine (% predicted)	75/50
TLCO Erect (% predicted)	70
KCO Erect (% predicted)	95

What is the most likely diagnosis?

A	Obstructive sleep apnoea
B	Nocturnal asthma
C	Bilateral diaphragmatic weakness
D	Left ventricular failure
E	Multiple sclerosis

70150

Submit

Previous Question | Skip Question

Calculator

Normal Values

© Pastest 2017

A 54-year-old man presented with increasing shortness of breath and orthopnoea. He had noticed these symptoms over the last few years but only went to his GP after he had had a severe episode of breathlessness when he went wading in the sea on holiday. On further enquiry, he had also become aware of morning headaches and an increasing tendency to fall asleep during the day.

On examination he looked well. Auscultation of his chest revealed reduced breath sounds and percussion note bi-basally.

Investigations:

Hb	17.7 g/dl
WCC	12.3 × 10^9/l
PLT	289 × 10^9/l
PCV	0.51
Residual volume Erect (% predicted)	105
Total lung capacity Erect (% predicted)	80
Vital capacity Erect (% predicted)/Supine (% predicted)	75/50
TLCO Erect (% predicted)	70
KCO Erect (% predicted)	95

What is the most likely diagnosis?

A	Obstructive sleep apnoea
B	Nocturnal asthma
C	Bilateral diaphragmatic weakness
D	Left ventricular failure
E	Multiple sclerosis

Explanation

C Bilateral diaphragmatic weakness

In bilateral diaphragmatic weakness, patients commonly present with breathlessness on exertion and when lying flat. It can be associated with sleep apnoea, resulting in daytime somnolence and headaches. The symptoms are due to the paroxysmal movement of the diaphragm during inspiration.

In the supine position, expansion of the ribs results in movement of abdominal contents into the chest, aided by gravity. Symptoms can be worse when standing up to the waist in water, as this counteracts the effects of gravity and prevents outward movement of the abdomen during inspiration and therefore produces a similar situation to being in the supine position.

A chest X-ray may show relatively small lung fields and basal linear shadowing due to sub-segmental collapse. A SNIF test (diaphragmatic screening on ultrasound) will show paradoxical movement of the diaphragm, particularly on sniffing. Blood gases may show a type II respiratory failure, particularly at night. Lung function tests classically show a low vital capacity, which falls further in the supine position. All lung volumes except the residual volume are reduced. The gas transfer tends to mildly impaired with a normal KCO. Treatment is with non-invasive ventilation.

A Obstructive sleep apnoea

The 15% change in vital capacity when supine alongside breathlessness when submerged in water and orthopnoea make diaphragmatic weakness more likely.

B Nocturnal asthma

The patient has no symptoms to suggest that asthma is the diagnosis. There is no wheeze or cough. The breathlessness is progressive and there are several other features in this history to suggest diaphragmatic weakness.

D Left ventricular failure

Orthopnoea and dull percussion notes bilaterally (due to pleural effusions) in isolation could be in keeping with LVF, but there is more going on here. The patient has a change in sitting and supine VC, there is a normal transfer factor when corrected for lung volumes and haemoglobin is high (you would expect a lower Hb in LVF due to fluid overload and haemodilution).

E Multiple sclerosis

Patients with MS can experience diaphragmatic weakness, but there are no other clinical features to suggest an underlying diagnosis of MS.

70150

Rate this question:

Next Question

Previous Question | Tag Question

Feedback | End Session

Difficulty: Average

Peer Responses %

Session Progress

Responses Correct:	0
Responses Incorrect:	260
Responses Total:	260
Responses - % Correct:	0%

© Pastest 2017

A 55-year-old woman presented with a 6-month history of recurrent chest infections. She had had a few episodes of wheeze and haemoptysis in the last few weeks. She also noticed intermittent hot flushes, which her GP had put down to the menopause. These could occur at any time but on occasions were precipitated by alcohol. She had no significant past medical history and she had never smoked. On examination she was anxious, examination of her chest revealed reduced expansion of the upper right zone. Cardiovascular examination revealed a pan-systolic murmur. Blood results were unremarkable. Her CXR is shown below.

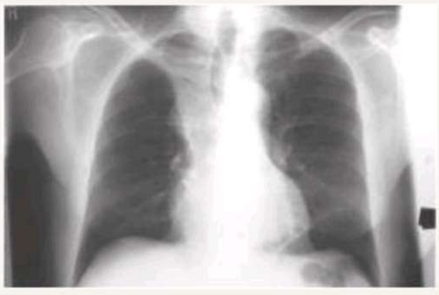

What does the CXR show?

A	Right upper lobe consolidation
B	Right pleural effusion
C	Right upper lobe calcification
D	Right upper lobe collapse
E	Right lower lobe collapse

70173

Submit

Previous Question | Skip Question

Calculator

Normal Values

© Pastest 2017

A 55-year-old woman presented with a 6-month history of recurrent chest infections. She had had a few episodes of wheeze and haemoptysis in the last few weeks. She also noticed intermittent hot flushes, which her GP had put down to the menopause. These could occur at any time but on occasions were precipitated by alcohol. She had no significant past medical history and she had never smoked. On examination she was anxious, examination of her chest revealed reduced expansion of the upper right zone. Cardiovascular examination revealed a pan-systolic murmur. Blood results were unremarkable. Her CXR is shown below.

What does the CXR show?

A	Right upper lobe consolidation
B	Right pleural effusion
C	Right upper lobe calcification
D	Right upper lobe collapse
E	Right lower lobe collapse

Explanation

D	Right upper lobe collapse

This patient has bronchial carcinoid. It commonly presents between the ages of 50 and 70 and is unrelated to smoking. Bronchial carcinoid tumours are the most indolent form of a spectrum of neuroendocrine tumours of the lung that include small-cell lung cancer as the most malignant. They are thought to arise from Kulchitsky's cells in the bronchial mucosa. They usually secrete serotonin and arise from the large bronchi. Patients may present with a mass, which is usually centrally located (as in this case – CXR shows right upper lobe collapse), or with recurrent chest infections, haemoptysis, chest pain and wheeze. Flushing (which may be precipitated by alcohol, food ingestion, stress or emotion) and diarrhoea may occur. However, patients are commonly asymptomatic and the tumour is found incidentally.

(The CXR does not show Right upper lobe consolidation, right pleural effusion, right upper lobe calcification or right lower lobe collapse).

Carcinoid syndrome occurs when there are secondaries in the liver which release serotonin into the systemic circulation. However, symptoms of carcinoid syndrome may rarely occur in bronchial carcinoid in the absence of metastases as the bronchial tree drains straight into the systemic circulation.

Diagnosis is by detection of 5-hydroxyindoleacetic acid (the metabolite of serotonin) in the urine and bronchial carcinoid is usually seen and diagnosed by bronchoscopy and biopsy.

The treatment of choice of bronchial carcinoid is surgical resection. Flushing may be controlled with somatostatin analogues.

Pellagra may occur due to tumour uptake of tryptophan, the precursor of nicotinic acid.

A	Right upper lobe consolidation

The CXR shows Right upper lobe collapse, where the lung volume itself looks diminished, not Right upper lobe consolidation.

B	Right pleural effusion

The CXR shows Right upper lobe collapse not Right pleural effusion. Pleural effusion is associated with lower zone changes consistent with fluid accumulation.

C	Right upper lobe calcification

The CXR shows Right upper lobe collapse not Right upper lobe calcification, which would be associated with a denser opacity, consistent with calcium deposition.

E	Right lower lobe collapse

The CXR shows Right upper lobe collapse not Right lower lobe collapse.

© Pastest 2017

A 31-year-old lady presented to the Respiratory Outpatients Department with a 3-year history of increasing shortness of breath and cough. She had required numerous courses of antibiotics in the last few years. She was a smoker of 5/day for about 5 years. Respiratory examination revealed a hyperinflated chest and a mild wheeze throughout.

Lung function tests:

FEV_1	50% predicted
FVC	80% predicted
TLCO	68% predicted
KCO	71% predicted
RV:TLC	Increased

Which investigation would help make a diagnosis?

A	Histamine challenge test
B	Sweat test
C	AAT genotyping
D	Reversibility testing
E	High-resolution CT

70193

Submit

Previous Question | Skip Question

Calculator

Normal Values

© Pastest 2017

A 31-year-old lady presented to the Respiratory Outpatients Department with a 3-year history of increasing shortness of breath and cough. She had required numerous courses of antibiotics in the last few years. She was a smoker of 5/day for about 5 years. Respiratory examination revealed a hyperinflated chest and a mild wheeze throughout.

Lung function tests:

FEV_1	50% predicted
FVC	80% predicted
TLCO	68% predicted
KCO	71% predicted
RV:TLC	Increased

Which investigation would help make a diagnosis?

A	Histamine challenge test
B	Sweat test
C	AAT genotyping
D	Reversibility testing
E	High-resolution CT

Explanation

C AAT genotyping

Alpha-1-antitrypsin deficiency is a rare autosomal recessive disease associated with the development of premature pan-lobular emphysema, most severe in the basal areas of the lungs. Emphysema is thought to result from an imbalance in the lung between neutrophil elastase (which destroys elastin) and the elastase inhibitor α1-antitrypsin (which protects against proteolytic degradation by elastin). The decline in lung function is accelerated in smokers.

Patients usually present with progressive increasing shortness of breath and weight loss. Cor pulmonale and polycythaemia occur later in the course of the disease. A chest X-ray usually shows bilateral bi-basal emphysema. Lung function tests show an obstructive picture and the RV:TLC ratio is raised, indicating gas trapping. Transfer factor will be reduced. There are a number of different phenotypes depending on the serum level of α1-antitrypsin:
Pi – protease inhibitor
M – normal allele
S, X and null are disease alleles

Phenotype	α1-Antitrypsin level	Disease
PiMM	Normal	
PiMS	80%	
PiMZ	60%	
PiSS	60%	
PiSZ	40%	Liver cirrhosis/premature emphysema
Pi Null Null	Nil	Premature emphysema

Treatment is similar to that of asthma. Alpha1-antitrypsin replacement can be given weekly or monthly and is recommended for those with very low serum levels and abnormal lung function. Lung transplantation should be considered in advanced disease. Patients should be encouraged to stop smoking.

A Histamine challenge test

This would be used to confirm a diagnosis of asthma. Histamine challenge is rarely performed because of technical difficulties in performing it, including the risk of provoking severe bronchoconstriction.

B Sweat test

This would be used to confirm a diagnosis of cystic fibrosis, where levels of sodium and chloride are measured in sweat, production of which is stimulated by pads soaked in pilocarpine.

D Reversibility testing

This would be used to confirm a diagnosis of asthma, rather than the picture consistent with alpha-1-antitrypsin deficiency seen here.

E High-resolution CT

This would be helpful in confirming basal predominant pan-lobular emphysema, making the diagnosis likely, but α1-antitrypsin levels would be more helpful in making definitive diagnosis.

70193

Rate this question:

Next Question

Previous Question | Tag Question

Feedback | End Session

Difficulty: Average

Peer Responses %

Session Progress

Responses Correct:	0
Responses Incorrect:	262
Responses Total:	262
Responses - % Correct:	0%

© Pastest 2017

A 76-year-old woman presents to the Respiratory Clinic with symptoms of stridor and shortness of breath. She smokes 5 cigarettes per day and has done for 50 years. She has also noticed in increase in swelling around the front of her neck over the past few weeks. On examination her BP is 138/80 mmHg, pulse is 75/min and regular. You notice a hard mass extending from the left lobe of the thyroid and regional lymphadenopathy. Auscultation of the chest reveals significant transmitted upper airway sounds. Abdomen is soft and non tender.

Her flow volume loop is shown below:

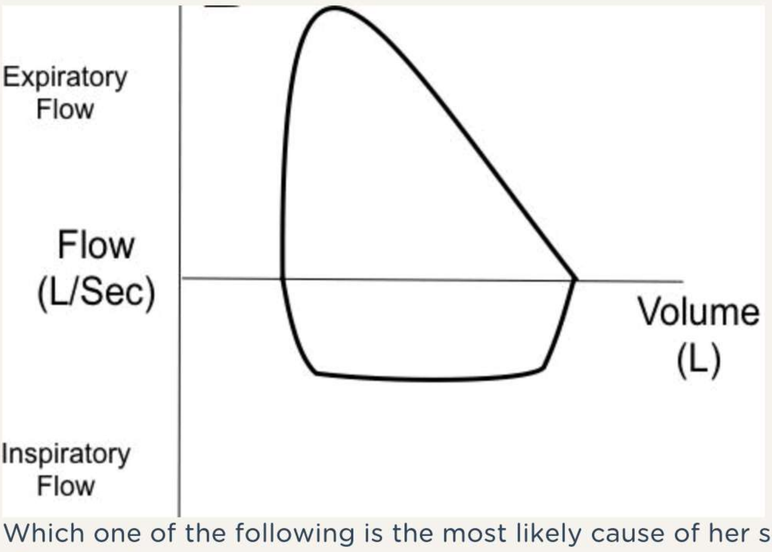

Which one of the following is the most likely cause of her shortness of breath?

A	Asthma
B	Emphysema
C	Left ventricular failure
D	Non-Hodgkin's lymphoma
E	Thyroid carcinoma

70415

Submit

Previous Question | Skip Question

Calculator

Normal Values

© Pastest 2017

A 76-year-old woman presents to the Respiratory Clinic with symptoms of stridor and shortness of breath. She smokes 5 cigarettes per day and has done for 50 years. She has also noticed in increase in swelling around the front of her neck over the past few weeks. On examination her BP is 138/80 mmHg, pulse is 75/min and regular. You notice a hard mass extending from the left lobe of the thyroid and regional lymphadenopathy. Auscultation of the chest reveals significant transmitted upper airway sounds. Abdomen is soft and non tender.

Her flow volume loop is shown below:

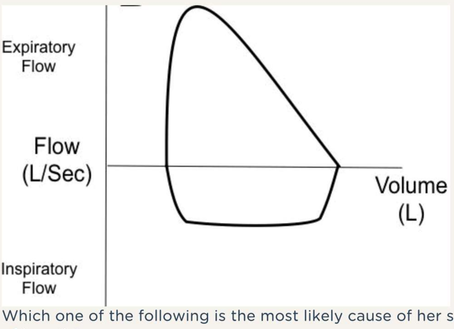

Which one of the following is the most likely cause of her shortness of breath?

A	Asthma
B	Emphysema
C	Left ventricular failure
D	Non-Hodgkin's lymphoma
E	Thyroid carcinoma

Explanation

E	Thyroid carcinoma

The features here with a rapidly enlarging anterior neck mass, are very suggestive of a diagnosis of anaplastic thyroid carcinoma. Tumoural extension has led to extra-thoracic obstruction and the restriction of inspiratory flow seen here on the flow volume loop.

A	Asthma

Obstructive lung disease results in a concave shape to the expiratory portion of the flow volume loop.

B	Emphysema

Emphysema shows a similar concavity with respect to the expiratory portion of the loop, residual volume is elevated, and total lung capacity is also increased.

C	Left ventricular failure

In patients with stable left ventricular failure, flattening of the inspiratory flow loop would not be expected.

D	Non-Hodgkin's lymphoma

Given the mass appears to be arising from the thyroid, this is the more likely diagnosis versus non-Hodgkin's lymphoma.

70415

Rate this question:

Next Question

Previous Question | Tag Question

Feedback | End Session

Difficulty: Average

Peer Responses %

Session Progress

Responses Correct:	0
Responses Incorrect:	263
Responses Total:	263
Responses - % Correct:	0%

© Pastest 2017

A 41-year-old woman who is known to have brittle asthma was admitted to the Emergency Department with increased shortness of breath and a severe cough over the past few days, productive of yellow/green sputum. She was pyrexial 38.4°C, pulse was 90/min and regular, BP was 85/60 mmHg on admission, but improved with a fluid challenge. You review her on the ward some 36 h later, with her blood culture results. Her BP is now 105/70 mmHg, with pulse 75/min and regular. There are right basal crackles consistent with consolidation. She is still spiking fevers of 39.2°C every few hours.

Investigations:

Hb	129 g/l
WCC	15.2
PLT	203 x 10^9/l
CRP	215 mg/l
Na^+	132 mmol/l
K^+	5.1 mmol/l
Creatinine	162 micromol/l
Urea	14.1 mmol/l
Blood cultures	*Pseudomonas*

Which of the following is the most appropriate antibiotic choice?

A	IV colistin (polymyxin E)
B	IV gentamicin
C	IV meropenem
D	IV tazocin
E	Oral ciprofloxacin

70490

Submit

Previous Question | Skip Question

Calculator

Normal Values

© Pastest 2017

A 41-year-old woman who is known to have brittle asthma was admitted to the Emergency Department with increased shortness of breath and a severe cough over the past few days, productive of yellow/green sputum. She was pyrexial 38.4°C, pulse was 90/min and regular, BP was 85/60 mmHg on admission, but improved with a fluid challenge. You review her on the ward some 36 h later, with her blood culture results. Her BP is now 105/70 mmHg, with pulse 75/min and regular. There are right basal crackles consistent with consolidation. She is still spiking fevers of 39.2°C every few hours.

Investigations:

Hb	129 g/l
WCC	15.2
PLT	203 x 10^9/l
CRP	215 mg/l
Na^+	132 mmol/l
K^+	5.1 mmol/l
Creatinine	162 micromol/l
Urea	14.1 mmol/l
Blood cultures	*Pseudomonas*

Which of the following is the most appropriate antibiotic choice?

A	IV colistin (polymyxin E)
B	IV gentamicin
C	IV meropenem
D	IV tazocin
E	Oral ciprofloxacin

Explanation

D	IV tazocin

The choice here is between oral quinolone and IV therapy for *Pseudomonas*. Given that this patient is still spiking fevers and has an elevated urea, IV therapy with tazocin is most appropriate.

A	IV colistin (polymyxin E)

Colistin is generally reserved for serious pseudomonal infections that are resistant to therapy with other agents.

B	IV gentamicin

Gentamicin monotherapy is not recommended for the treatment of respiratory tract infections.

C	IV meropenem

Carbapenems are an option for the treatment of *Pseudomonas*, although inducible resistance is a concern. For this reason, tazocin is the preferred option.

E	Oral ciprofloxacin

Although oral ciprofloxacin is an option for pseudomonal infection, the severity of this patient's pneumonia drives us more towards IV tazocin as the preferred therapy.

70490

Rate this question:

Next Question

Previous Question | Tag Question

Feedback | End Session

Difficulty: Average

Peer Responses %

Session Progress

Responses Correct:	0
Responses Incorrect:	264
Responses Total:	264
Responses - % Correct:	0%

© Pastest 2017

A 64-year-old man presents to the Emergency Department with nausea, vomiting and polyuria over the past few days. By the time he reaches the hospital he is drowsy and confused. Past medical history of note includes COPD, for which he takes high-dose seretide, a previous anterior myocardial infarction (MI), and he continues to smoke 30 cigarettes per day. On examination his BP is 115/75 mmHg, with pulse 90/min and regular. There is bilateral poor air entry on auscultation of the chest, with quiet wheeze. Abdomen is soft and non-tender.

Investigations:

Hb	131 g/l
WCC	9.2×10^9 /l
PLT	203×10^9 /l
Na^+	145 mmol/l
K^+	5.1 mmol/l
Creatinine	151 micromol/l
Glucose	6.9 mmol/l
Ca^{2+}	3.31 mmol/l
Albumin	38 g/l
ALT	122 U/l
ALP	191 U/l
PO_4	0.7 mmol/l
CXR	left hilar mass

Which of the following is the most likely diagnosis?

A	Adenocarcinoma of the bronchus
B	Bronchial carcinoid
C	Non-Hodgkin's lymphoma
D	Small cell carcinoma of the bronchus
E	Squamous cell carcinoma of the bronchus

70499

Submit

Previous Question | Skip Question

Calculator

Normal Values

© Pastest 2017

A 64-year-old man presents to the Emergency Department with nausea, vomiting and polyuria over the past few days. By the time he reaches the hospital he is drowsy and confused. Past medical history of note includes COPD, for which he takes high-dose seretide, a previous anterior myocardial infarction (MI), and he continues to smoke 30 cigarettes per day. On examination his BP is 115/75 mmHg, with pulse 90/min and regular. There is bilateral poor air entry on auscultation of the chest, with quiet wheeze. Abdomen is soft and non-tender.

Investigations:

Hb	131 g/l
WCC	9.2 x 10^9 /l
PLT	203 x 10^9 /l
Na^+	145 mmol/l
K^+	5.1 mmol/l
Creatinine	151 micromol/l
Glucose	6.9 mmol/l
Ca^{2+}	3.31 mmol/l
Albumin	38 g/l
ALT	122 U/l
ALP	191 U/l
PO_4	0.7 mmol/l
CXR	left hilar mass

Which of the following is the most likely diagnosis?

A Adenocarcinoma of the bronchus

B Bronchial carcinoid

C Non-Hodgkin's lymphoma

D Small cell carcinoma of the bronchus

E Squamous cell carcinoma of the bronchus

Explanation

E Squamous cell carcinoma of the bronchus

The most likely diagnosis, with evidence of lung cancer, hypercalcaemia and phosphate below the lower limit of the normal range, is squamous cell carcinoma of the bronchus associated with production of parathyroid hormone-related protein (PTHrP). If intact PTH is measured, then this is found to be below the lower limit of normal.

A Adenocarcinoma of the bronchus

Bronchial adenocarcinoma is rarely associated with paraneoplastic syndromes, although some cases of polymyositis are documented.

B Bronchial carcinoid

Bronchial carcinoid generally occurs at a younger age and is not associated with smoking; lesions are often peripheral. It is most likely to be associated with secretion of serotonin, although tumours secreting ACTH and growth hormone are also seen.

C Non-Hodgkin's lymphoma

In NHL more extensive lymphadenopathy would be expected, and although PTHrP secretion is seen in NHL, it is much less frequently seen than in bronchial carcinoma.

D Small cell carcinoma of the bronchus

This is more likely to be associated with syndrome of inappropriate ADH secretion (SIADH) and hyponatraemia.

70499

Rate this question:

Next Question

Previous Question | Tag Question

Feedback | End Session

Difficulty: Average

Peer Responses %

Session Progress

Responses Correct:	0
Responses Incorrect:	265
Responses Total:	265
Responses - % Correct:	0%

© Pastest 2017

A 64-year-old woman comes to the Respiratory Clinic for review. She has recently been diagnosed with moderate COPD and is about to commence therapy for the condition. She also has a history of hypertension and chronic stable angina for which she receives ramipril, indapamide and diltiazem. On examination her BP is 132/82 mmHg, with pulse 70/min and regular. There is bilateral poor air entry with quiet wheeze on auscultation of the chest.

Which of the following is likely to have the greatest short-term impact on her quality of life?

A	Ipratropium
B	Long-term oxygen therapy (LTOT)
C	Pulmonary rehabilitation
D	Salbutamol
E	Tiotropium

70500

Submit

Previous Question

Calculator

Normal Values

© Pastest 2017

A 64-year-old woman comes to the Respiratory Clinic for review. She has recently been diagnosed with moderate COPD and is about to commence therapy for the condition. She also has a history of hypertension and chronic stable angina for which she receives ramipril, indapamide and diltiazem. On examination her BP is 132/82 mmHg, with pulse 70/min and regular. There is bilateral poor air entry with quiet wheeze on auscultation of the chest.

Which of the following is likely to have the greatest short-term impact on her quality of life?

A	Ipratropium
B	Long-term oxygen therapy (LTOT)
C	Pulmonary rehabilitation
D	Salbutamol
E	Tiotropium

Explanation

C	Pulmonary rehabilitation

Pulmonary rehabilitation has been shown to improve exercise tolerance in COPD, and will also improve this patient's exercise tolerance in relation to her chronic stable angina. Over a relatively short time, (about 6-8 weeks), these improvements have been shown to lead to quality of life (QoL) benefit.

A	Ipratropium

Short-acting anti-cholinergics do not significantly impact on quality of life in COPD.

B	Long-term oxygen therapy (LTOT)

LTOT reduces progression of pulmonary hypertension and right heart failure over the longer term. Although this translates into QoL benefit over the longer term, in the short term pulmonary rehabilitation will have a greater impact.

D	Salbutamol

Short acting beta-agonists do not have significant impact on QoL in COPD.

E	Tiotropium

Although tiotropium did show an impact on the St George's respiratory quality of life score, the effect was moderate and was only seen in 3 out of 4 pivotal studies. Hence over the short term, pulmonary rehabilitation carries greater benefit.

70500

Rate this question:

End Session

Previous Question | Tag Question

Feedback

Difficulty: Average

Peer Responses %

Session Progress

Responses Correct:	0
Responses Incorrect:	266
Responses Total:	266
Responses - % Correct:	0%

© Pastest 2017